

The key to an ordered and successful day in theatre is good communication among all the staff involved. A briefing involving the surgeons, theatre staff and anaesthetists should always take place before starting the theatre list. It is good practice to discuss each case that will be performed during the operating list. Important information that should be discussed for each patient includes significant past medical history (e.g. malignant hypertension), the optimal positioning on the table, the requirement for specialist equipment (e.g. fluoroscopy), the need for a diathermy pad, the site of the incision and whether antibiotics are required perioperatively. Any anticipated difficulties should also be discussed. In conjunction with a briefing at the start of the list, The World Health Organisation *Safe Surgery Checklist* has been shown to reduce surgical morbidity and mortality and its use for each case should be strongly encouraged (see Chap. A1).

The position of the patient is as fundamental as is the initial incision. Good positioning and draping will allow optimal exposure of the operative field. For each position, any potential pressure points where the skin overlies a bony prominence should be protected with additional padding. In this chapter we discuss some of the common positions used in paediatric surgery.

Extended Neck for Head and Neck Surgery

The patient lies on their back with a roll placed under the shoulders and the neck extended in the midline. This position is adopted for operations on the neck, e.g. thyroid and thyroglossal cyst.

Dorsal Position

The patient lies on their back on the operating table (Fig. 1). This is the position most commonly adopted in paediatric surgery. Arms should be kept at the side of the patient, with the use of curved supports.

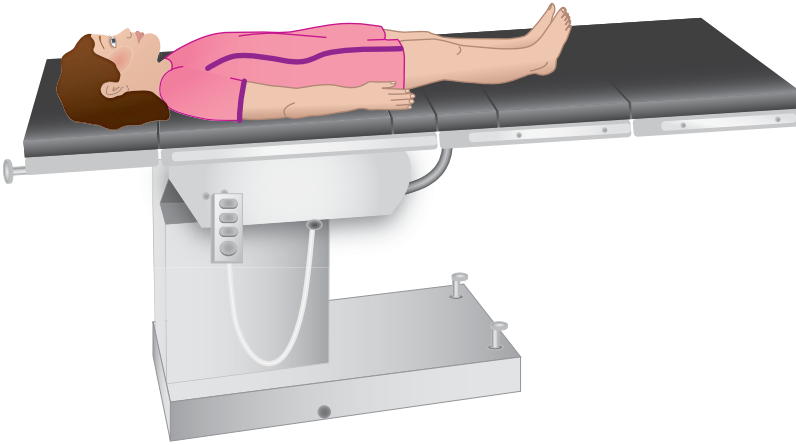
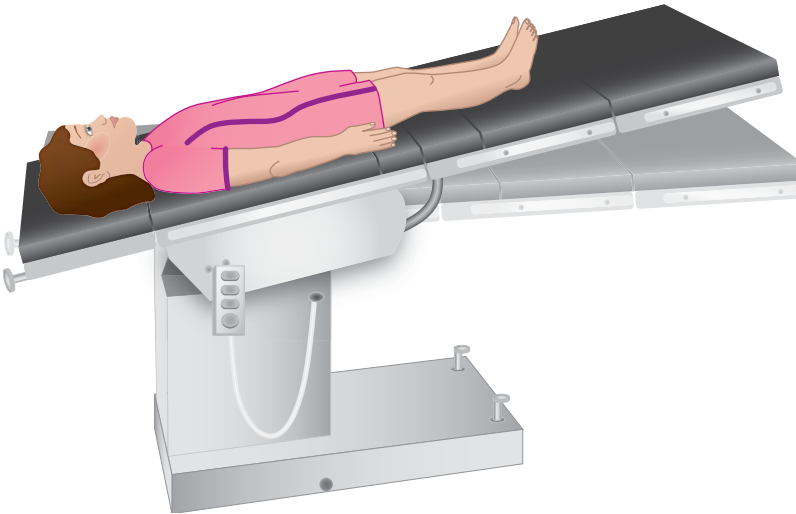
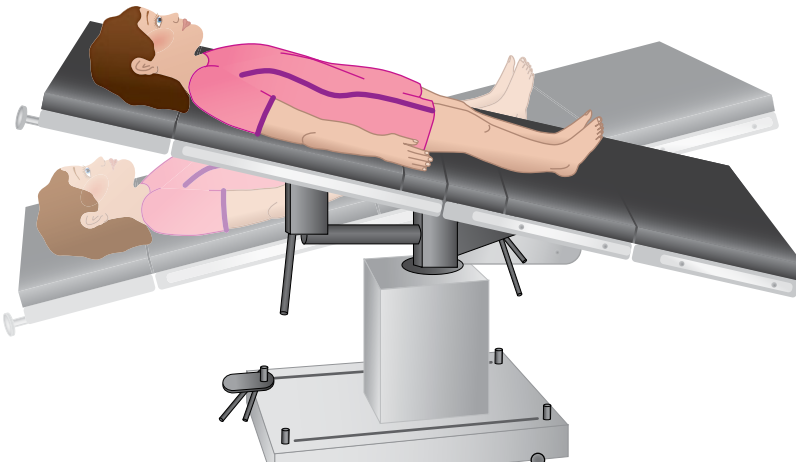
Trendelenburg Position

The patient is placed on the operating table in the dorsal position, but the table is tilted with a head-downwards slope (Fig. 2). The feet are now at a higher level than the head. This increases venous return from the body, but increases the risk of aspiration of gastric contents and may hinder diaphragmatic excursion. The head-down position can be used in central venous surgery to fill the internal and external jugular veins, and in pelvic surgery to displace the abdominal organs out of the pelvis. In a laparoscopic appendectomy the patient is usually positioned head down, with a left lateral tilt to help mobilise the small bowel from the pelvis and right iliac fossa, providing optimal exposure of the caecum and appendix base.

In the reverse-Trendelenburg position (Fig. 3), the patient is tilted in the opposite direction, so that the head and chest lay superior to the lower limbs. This position may be used to facilitate exposure of the upper abdomen during laparoscopy.

Prabhu Sekaran (✉)
Specialty Trainee in Paediatric Surgery
E-mail: Prabhu.sekaran@nhs.net

Robert Carachi
Professor of Surgical Paediatrics
E-mail: Robert.Carachi@glasgow.ac.uk

**Fig. 1****Fig. 2****Fig. 3**

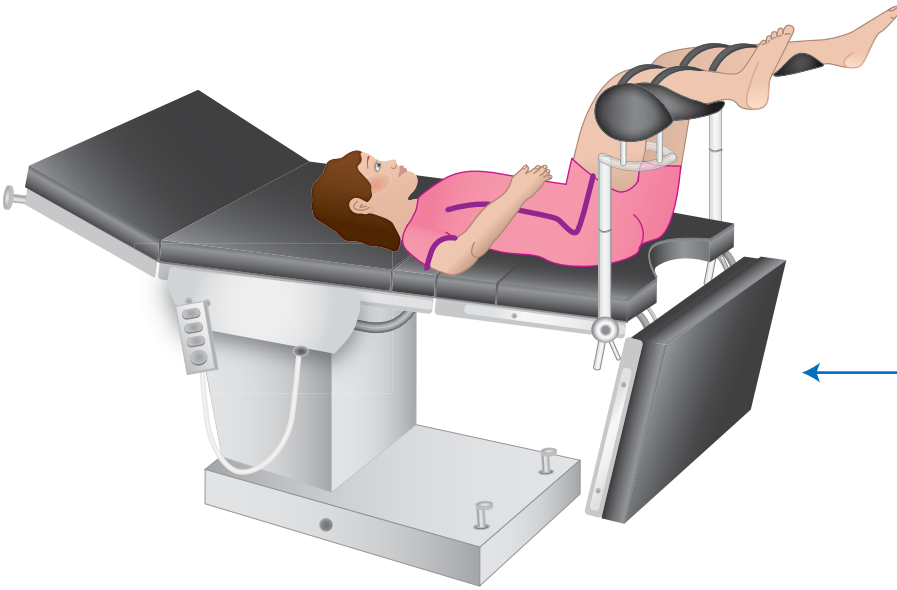


Fig. 4

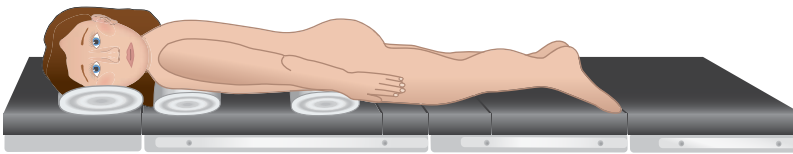


Fig. 5

Lithotomy Position

The patient lies supine on the operating table. The thighs and knees are flexed and supported on stirrups (Fig. 4). Additional padding should be placed under the posterior compartment muscles of the legs to reduce the risk of pressure ulceration. The legs are secured onto the stirrups with crepe bandaging. This position is routinely used for cystoscopy, as it provides good exposure of the perineum.

Lateral Position

The patient is placed on their side with the arm on the side of the incision, lying forward and over the face, supported on an armrest (Fig. 6). Care should be taken to avoid dislodging the endotracheal tube. The patient is secured to the edges of the table by using strong adhesive tape across the hips and shoulders to prevent the patient from rolling during the operation. This position may be used for posterolateral thoracotomies and open renal surgery.

Prone Position

The patient is placed flat, face downwards on the operating table, with their arms at their side (Fig. 5). The face is supported with a head ring and the endotracheal tube position is safely secured. This position may be used for closure of myelomeningocele and excision of sacrococcygeal teratoma.

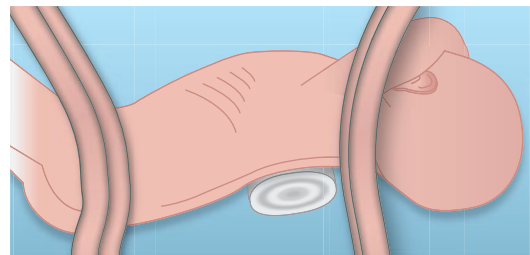


Fig. 6

Basic Techniques in Pediatric Surgery

An Operative Manual

Carachi, R.; Agarwala, S.; Bradnock, T.J. (Eds.)

2013, XVIII, 644 p. 1100 illus., Hardcover

ISBN: 978-3-642-20640-5