

Michael E. Lipkin and Glenn M. Preminger

Contents

2.1	Introduction	9
2.2	Computed Tomography	9
2.2.1	Indications.....	9
2.2.2	Radiation Exposure.....	11
2.2.3	Recommendations.....	11
2.3	Ultrasound	12
2.3.1	Indications.....	12
2.3.2	Recommendations.....	13
2.4	Plain Radiography	14
2.4.1	Kidneys, Ureters, and Bladder (KUB).....	14
2.4.2	Intravenous Pyelography (IVP).....	14
2.4.3	Radiation Exposure.....	14
2.4.4	Recommendation.....	15
2.5	Magnetic Resonance Imaging (MRI)	15
2.5.1	Indications.....	15
2.5.2	Recommendations.....	15
2.6	New Technology	15
2.6.1	Digital Tomosynthesis.....	15
	References	16

M.E. Lipkin (✉)
Duke Comprehensive Kidney Stone Center,
Division of Urologic Surgery, Duke University,
200 Trent Drive, DUMC 3167,
Durham, NC 27713
e-mail: michael.lipkin@duke.edu

G.M. Preminger
Duke Comprehensive Kidney Stone Center,
Division of Urologic Surgery, Duke University,
200 Trent Drive, DUMC 3167, Durham, NC 27713
e-mail: premi001@mc.duke.edu

2.1 Introduction

Imaging remains a critical component to the evaluation of a patient with known or suspected urolithiasis. There are a number of imaging modalities that have been used for the evaluation of urolithiasis. Imaging for urolithiasis has evolved over the years. Historically, plain abdominal radiography (KUB) and excretory radiography (IVP) have been considered the studies of choice for the diagnosis and follow-up of patients with stones. These modalities have been largely supplanted by non-contrast computed tomography of the abdomen and pelvis (NCCT) and ultrasound. Though NCCT and ultrasound represent improvements over traditional radiography, neither is without limitations. The ideal imaging study for the evaluation of urolithiasis would be quickly performed, have a high sensitivity and specificity for the detection of stones, and expose the patient to minimal or no radiation. This chapter will review currently available imaging modalities for the evaluation of urolithiasis. The advantages and disadvantages of each will be discussed. Recommendations on the clinical scenarios where each should be used will also be made.

2.2 Computed Tomography

2.2.1 Indications

Non-contrast computed tomography (NCCT) has been used to evaluate for urinary stones for over

30 years (Segal et al. 1978; Tessler and Ghazi 1979). Initially, its primary utility was in diagnosing radiolucent stones (Segal et al. 1978; Tessler et al. 1979; Federle et al. 1981). However, it was eventually demonstrated that NCCT had improved sensitivity for diagnosing ureteral stones in patients with flank pain compared with IVP (Smith et al. 1995). Currently, NCCT is considered the first-line imaging study for the evaluation of the patient with acute flank pain (Westphalen et al. 2011). The reported sensitivity for diagnosing a ureteral stone in a patient with acute flank pain ranges from 95% to 98% and the specificity ranges from 96% to 98% (Smith et al. 1996; Dalrymple et al. 1998; Vieweg et al. 1998). In addition to being able to identify the stone, NCCT allows for evaluation of secondary signs of obstruction associated with ureteral stones. In one study, NCCT was able to identify hydroureter in 82.7%, hydronephrosis in 80%, peri-ureteric edema in 59%, and unilateral renal enlargement in 57.2% of patients with ureteral stones (Ege et al. 2003).

There are other advantages NCCT holds over IVP and other imaging modalities for the evaluation of acute flank pain. NCCT is quickly performed and does not require intravenous contrast. Unlike plain radiography such as KUB and IVP, NCCT can detect stones of almost any composition. The exception to this are stones formed by protease inhibitors, such as indinavir, which may not be visible on NCCT (Sundaram and Saltzman 1999). However, often in these cases, there are secondary signs of stones such as hydroureter and periureteral or perinephric inflammation which aide in the diagnosis (Sundaram et al. 1999).

Another advantage of NCCT in the evaluation of the patient with acute flank pain is the ability to evaluate the rest of the abdominal and pelvic viscera and possibly identify other causes for pain. In one study evaluating 1,000 consecutive NCCT performed for the evaluation of renal colic, an alternative diagnosis was made in 10.1% of the cases (Katz et al. 2000). The majority of these diagnoses were related to the genitourinary system. Ureteral stones or signs

suggestive of recently passed ureteral stones were identified in 62.4% of the patients, and 27.5% of the NCCT were considered negative for any pathology. Another report looking at 1,500 NCCT for the evaluation of flank pain with a suspected stone found 24% of the patients had alternative CT findings without a urinary calculus, and 7% had a negative CT (Hoppe et al. 2006). A urinary stone was identified in 69% of patients. An additional pathological condition was found in 47% of the patients who were diagnosed with a stone.

Beyond diagnosing urolithiasis, NCCT is useful in preoperative planning for the treatment of stones. Stone size and location are easily evaluated with NCCT. Skin to stone distance as determined on preoperative NCCT is an independent predictor of successful treatment of SWL (Pareek et al. 2005; Perks et al. 2008; Patel et al. 2009; Wiesenthal et al. 2010). The greater the skin to stone distance, the lower the efficacy of SWL. A skin to stone distance greater than or equal to 11 cm has been associated with worse stone-free outcomes for SWL (Patel et al. 2009; Wiesenthal et al. 2010). Prone NCCT can be useful for preoperative evaluation prior to PNL. Prone NCCT can determine the anatomic relations of adjacent organs and the pleura with upper pole calyces (Hopper and Yakes 1990; Ng et al. 2005). This can be useful in risk stratifying patients for potential organ injury when planning upper pole access.

Stone composition can be identified as well. Hounsfield units (HU) or CT attenuation has been most commonly used to aide in the identification of stone composition (Mostafavi et al. 1998). Brushite stones and calcium oxalate stones were shown to have the highest CT attenuations, averaging over 1,400 HU. Uric acid stones had the lowest CT attenuation, on average 409 HU. These measurements have clinical implications when planning surgical treatment treatments. A number of reports demonstrated that the efficacy of shock wave lithotripsy (SWL) is affected by stone attenuation on NCCT (Joseph et al. 2002; Perks et al. 2008; Shah et al. 2010; Wiesenthal et al. 2010). In a series looking at 30 patients who

underwent SWL, the authors found that the success rate for fragmentation (54%) was significantly lower for stones with a CT attenuation greater than 1,000 HU when compared with stones with attenuations 500–1,000 HU (86.7%) or less than 500 (100%) (Joseph et al. 2002). Another group reported a significantly higher effectiveness coefficient for SWL treating stones with attenuation less than 1,200 HU versus those with greater than 1,200 HU (80.4% vs. 66.2%, $p=0.03$) (Shah et al. 2010). Two reports have demonstrated that stone attenuation less than 900 HU is an independent predictor of SWL success (Perks et al. 2008; Wiesenthal et al. 2010). Dual-energy NCCT can be used to determine stone composition as well (Ferrandino et al. 2010; Zilberman et al. 2010; Manglaviti et al. 2011). In an in vivo study, dual-energy NCCT was able to accurately determine and differentiate stone compositions, including stones of mixed composition (Zilberman et al. 2010). The ability to accurately identify stone composition with NCCT can direct both surgical management and metabolic workup.

2.2.2 Radiation Exposure

The utilization of CT scans has rapidly increased in the United States over the past 30 years. In 2006, there were estimated 62 million CT scans performed in the United States (Brenner and Hall 2007). It estimated that an additional 29,000 cancers could be related to CT scans performed in the United States in 2007 (Berrington de Gonzalez et al. 2009). From 1996 to 2007, the use of NCCT to assess patients with suspected urolithiasis increased significantly from 4% to 42.5% (Westphalen et al. 2011). The use of NCCT for evaluation of flank pain in the emergency room has increased significantly over the past decade (Hyams et al. 2011). Patients receive a median of 1.7 CT scans in the 1 year period following an acute stone event (Ferrandino et al. 2009).

The advent of newer CT scanners and newer software has allowed for lower radiation doses while maintaining diagnostic accuracy for the imaging of nephrolithiasis. There have been a

number of reports assessing “low-dose” CT for the evaluation of stones and renal colic (Kim et al. 2005; Kluner et al. 2006; Poletti et al. 2007; Jellison et al. 2009; Jin et al. 2010; Zilberman et al. 2011). One report compared a standard NCCT at a dose of 7.3–10 mSv versus a low-dose NCCT at 1.4–1.97 mSv for the evaluation of acute renal colic (Kim et al. 2005). The low-dose NCCT had equivalent sensitivities to the standard NCCT for the diagnosis of a ureteral stone except in cases of stones <2 mm. In these cases, low-dose NCCT did not perform as well as standard dose NCCT (Kim et al. 2005). In another evaluation of low-dose versus standard dose NCCT for the evaluation of acute renal colic, low-dose NCCT achieved sensitivities and specificities for diagnosing a stone or indirect signs of a stone approaching standard dose NCCT (Poletti et al. 2007). The authors in this trial did report decreased sensitivity and specificity for the diagnosis of ureteral calculi with patient body mass index (BMI) greater than 30 kg/m², 50% and 89% respectively, compared to 95% and 97% in non-obese patients (Poletti et al. 2007). Low-dose NCCT has been shown to be useful for the follow-up of recurrent stone formers to evaluate for new stone formation or stone growth (Zilberman et al. 2011). A recent meta-analysis of studies evaluating low-dose NCCT demonstrated a pooled sensitivity of 97% and specificity of 95% (Niemann et al. 2008). Low-dose NCCT appears to perform as well as standard NCCT for the evaluation of urolithiasis, and in cases where NCCT is to be performed, low-dose NCCT should be considered the first-line imaging study.

2.2.3 Recommendations

Non-contrast CT of the abdomen and pelvis should be considered the first-line imaging study for patients presenting with acute renal colic and suspected urolithiasis due to its exceptional sensitivity and specificity for identifying a stone or secondary signs related to obstruction. The exception

to this would be in pediatric patients and pregnant women due to the increased risks from radiation exposure in these populations. However, the use of low-dose NCCT has been reported to be safe during pregnancy (White et al. 2007). A low-dose NCCT should be used in lieu of a standard dose NCCT due to similar sensitivity and specificity and decreased radiation exposure. NCCT should be considered in the planning of surgical interventions. The information provided by a NCCT about stone size, location, and composition aide in determining appropriate surgical management. Performing NCCT in the prone position also helps to risk stratify patients undergoing PNL for injuries to adjacent organs.

2.3 Ultrasound

2.3.1 Indications

Ultrasound is commonly used to evaluate for urolithiasis. The main advantage of ultrasound over NCCT is that it exposes patients to no radiation. This advantage comes at a cost of decreased sensitivity and specificity, especially for ureteral calculi. Using NCCT as the standard, the sensitivity of ultrasound for diagnosing renal stones ranges from 29% to 81% (Fowler et al. 2002; Unal et al. 2003; Ulsan et al. 2007; Viprakasit et al. 2011). The specificity ranges from 82% to 90% (Fowler et al. 2002; Unal et al. 2003; Ulsan et al. 2007). Ultrasound is less accurate at imaging ureteral stones. The sensitivity of ultrasound for the detection of ureteral stones in patients with acute renal colic ranges from 11% to 93% (Yilmaz et al. 1998; Sheafar et al. 2000; Hamm et al. 2001; Patlas et al. 2001; Unal et al. 2003; Ripolles et al. 2004). The specificity for ureteral stones ranges from 87% to 100% (Yilmaz et al. 1998; Sheafar et al. 2000; Hamm et al. 2001; Patlas et al. 2001; Unal et al. 2003; Ripolles et al. 2004).

Similar to NCCT, ultrasound can identify alternative causes for renal colic. In a study of 45 patients with renal colic who underwent both NCCT and ultrasound, the sensitivity for ultrasound diagnosing a ureteral stone was 61%

versus 96% for NCCT ($p=0.02$) (Sheafar et al. 2000). However, the sensitivity for ultrasound in determining any cause for renal colic, such as hydronephrosis, stones, or appendicitis, was 85%. In another report comparing ultrasound and NCCT for the evaluation of renal colic in 62 patients, the sensitivity of ultrasound detecting a ureteral stone was 93% (Patlas et al. 2001). Ultrasound was able to find an alternative diagnosis in six patients including appendicitis, cholecystitis, cholelithiasis, adnexal mass, and torsed ovary. Ultrasound is also very good at identifying secondary signs of obstruction during renal colic. The sensitivity and specificity of ultrasound for the diagnosis of obstruction has been reported to be as high as 100% (Ripolles et al. 2004). In patients with confirmed renal colic, ultrasound identified hydronephrosis in 95%, ureteral dilation in 89%, and perirenal fluid in 23% (Ripolles et al. 2004). Ultrasound has been shown to be effective at identifying stones in the distal ureter. One prospective study looked at patients diagnosed with distal ureteral stones on an initial NCCT (Moesbergen et al. 2011). On follow-up, the patients were imaged with ultrasound in addition to either repeat NCCT or radiography. The sensitivity of ultrasound on follow-up was 94.3%, and the specificity was 99.1%. The benefit of using ultrasound for the follow-up of ureteral calculi is it reduces the patient's radiation exposure.

The limitations of ultrasound for identifying stones are related to stone location, size, and patient size. As stated above, ultrasound is less sensitive at detecting stones in the ureter than in the kidney (Yilmaz et al. 1998; Sheafar et al. 2000; Hamm et al. 2001; Patlas et al. 2001; Fowler et al. 2002; Unal et al. 2003; Ripolles et al. 2004; Ulsan et al. 2007; Viprakasit et al. 2011). In a retrospective study of 228 patients with renal colic and suspected ureteral stones who were evaluated with ultrasound and then treated with ureteroscopy for ureteral stones, the sensitivity of ultrasound was 86.4% (Pichler et al. 2011). The stone size was significantly smaller in the patients in whom ultrasound failed to diagnose a stone (4 mm vs. 6 mm, $p<0.001$). In addition to difficulties identifying smaller stones,

ultrasound has been shown to overestimate stone size compared to NCCT (Ray et al. 2010). In one report, the mean stone size on NCCT was 7.4 ± 4 mm versus 9.2 ± 5 mm ($p=0.018$) (Ray et al. 2010). This can have implications when counseling patients on likelihood of stone passage and when discussing treatment options. Patient body habitus is another factor that can affect the accuracy of ultrasound. Increased skin to stone distance leads to increased discordance between ultrasound and NCCT for the measurement of stone size (Ray et al. 2010). The ability of ultrasound to detect stones has been shown to be lower in patients with higher BMI (Pichler et al. 2011).

There are certain signs and techniques that can improve the sensitivity of ultrasound. Doppler ultrasound can be useful to aide in the detection of stones. One sign that can be evaluated using Doppler ultrasound is the “twinkling sign” (Mitterberger et al. 2009). The “twinkling sign” is color-flow Doppler ultrasound artifact. It appears as random color encoding in the area behind the stone where shadowing would be seen in traditional B-mode ultrasound. Doppler ultrasound utilizing the “twinkling sign” has been shown to outperform gray scale ultrasonography for the detection of urolithiasis (Mitterberger et al. 2009). In this report, Doppler ultrasound was able to detect 97% of stones versus 66% for gray scale ultrasound. Another measurement that can improve ultrasound detection of stones and obstruction is the resistive index (RI) (Shokeir and Abdulmaaboud 2001; Gandolpho et al. 2001; Pepe et al. 2005; Andreoiu and MacMahon 2009; Kavakli et al. 2011). Using IVP as the standard, RI was shown to have a sensitivity of 88% and a specificity of 98% for ureteral obstruction (Shokeir AA, Abdulmaaboud M 1999). The RI in obstructed kidneys was significantly greater than the RI in non-obstructed kidneys, 0.73 versus 0.64 ($p<0.001$). In a prospective study comparing NCCT and Doppler ultrasound with RI for the detection of ureteral obstruction using IVP as the standard, both NCCT and Doppler ultrasound performed equally well (Shokeir and Abdulmaaboud 2001). The sensitivity and specificity for the diagnosis of ureteral obstruc-

tion for NCCT was 96% and 96% compared to 90% and 100% for Doppler ultrasound. Using a RI of 0.70 and a 10% difference in RI between kidneys as diagnostic of obstruction, the sensitivity and specificity of ultrasound for the diagnosis of ureteral obstruction can be improved from 94.8% and 55.5% to 98.9% and 90.9% (Pepe et al. 2005). The finding of ureteral jets on Doppler ultrasound can be a useful adjunct to RI in ruling out obstruction (Gandolpho et al. 2001; Andreoiu and MacMahon 2009). Color Doppler ultrasound and measurement of RI is a useful adjunct to gray scale ultrasonography to improve the sensitivity and specificity of diagnosis ureteral obstruction in patients with renal colic.

2.3.2 Recommendations

Ultrasound should be considered the first-line imaging study for the evaluation of renal colic in pediatric patients and pregnant women given the lack of radiation exposure. Ultrasound is an acceptable alternative to NCCT in adults with suspected urolithiasis; however, it has decreased sensitivity and specificity compared to NCCT, particularly for the diagnosis of ureteral stones. Ultrasound can overestimate stone size; therefore, in cases where the stone size may affect the type of surgery a patient is offered, consideration should be made to obtain a NCCT prior to surgery. Ultrasound is also limited in obese patients. In obese patients in whom there is a high index of suspicion for urolithiasis and a negative ultrasound, NCCT should be obtained. Ultrasound can be useful for follow-up in patients who are diagnosed with distal ureteral stones with evidence for obstruction on NCCT and are offered conservative management to rule out persistent obstruction. It is also useful for follow-up of patients who undergo uncomplicated surgical procedures to rule out new or residual obstruction. In patients in whom it is important to determine stone-free status postoperatively, NCCT should be performed due to its increased sensitivity. Finally, color Doppler is a useful adjunct to gray scale ultrasonography to aide in the diagnosis of stones or ureteral obstruction.

2.4 Plain Radiography

2.4.1 Kidneys, Ureters, and Bladder (KUB)

The majority of stones are calcium containing and therefore would be expected to be visible on KUB. However, the sensitivity of KUB for diagnosing urolithiasis has been reported to be 45–58% (Mutgi et al. 1991; Levine et al. 1997; Jackman et al. 2000; Johnston et al. 2009). The specificity of KUB is between 69% and 77% (Mutgi et al. 1991; Levine et al. 1997). The factors that contribute to this low sensitivity and specificity include overlying bowel gas, extrarenal and extra-ureteral calcifications, and patient body habitus (Sandhu et al. 2003). The use of tomography has been shown to improve the diagnostic accuracy of KUB for the evaluation of nephrolithiasis (Goldwasser et al. 1989). In 46% of patients, additional stones were seen on tomograms versus KUB, and in 8% of patients, stones were not seen on KUB but were identified on tomograms.

Despite the limitations of KUB, it is still useful in the evaluation of patients with urolithiasis. It is often used as an adjunct to ultrasound in the evaluation of patients with renal colic. Ultrasound combined with KUB has been demonstrated to have a sensitivity of 96% and a specificity of 91% for the diagnosis of ureteral calculi (Mitterberger et al. 2007). It is recommended that KUB be performed prior to ultrasound as KUB can identify calcifications and direct the ultrasound examination. Ultrasound can then be used to confirm these calcifications are stones. KUB also has utility in preoperative planning. It can determine radiopacity and ability to target with fluoroscopy prior to SWL. In one study, a KUB was obtained after a stone was diagnosed on NCCT (Lamb et al. 2008). The KUB changed the surgical management in 17 out of 100 cases. When compared to a scout image from a NCCT, KUB is more sensitive for identifying stones (Jackman et al. 2000; Johnston et al. 2009). Therefore, scout images from NCCT cannot be used as a surrogate for a KUB. If surgical intervention with

SWL is planned, a KUB should be obtained to determine if the stone will be visible on fluoroscopy.

2.4.2 Intravenous Pyelography (IVP)

Prior to the development of NCCT, IVP was considered the standard imaging technique for the evaluation of renal colic. However, NCCT has been shown to be superior in identifying stones in patients with renal colic (Smith et al. 1995; Pfister et al. 2003). In a prospective randomized trial comparing NCCT with IVP for the evaluation of acute flank pain, NCCT was shown to have superior sensitivity and specificity compared to IVP (Pfister et al. 2003). The sensitivity and specificity of NCCT was 94.1% and 94.2% compared to 85.2% and 90.4% for IVP. Other disadvantages of IVP are the need for intravenous contrast and the longer amount of time to perform the exam. IVP does have some utility in evaluating for obstruction and relative renal function. Contrast images of the ureter can be useful in evaluating patients for ureteral strictures. It also provides detailed pelvi-calyceal anatomy which can be useful in planning surgical interventions, especially in those individuals with urinary tract anomalies.

2.4.3 Radiation Exposure

The effective dose for a KUB and IVP has been reported to be approximately 1.3 and 3 mSv, respectively (Mettler et al. 2008). The number of images obtained during an IVP affects the dose, with the more shots taken the higher the effective dose. The use of tomograms with a KUB increases the dose of radiation. One study comparing the effective dose of a NCCT with KUB and tomograms found that the NCCT exposed patients to less radiation (Wang et al. 2011). The effective dose of the KUB was calculated to be 0.67 mSv, and the effective dose of each tomogram was 1.1 mSv. The effective dose of a “low-dose” NCCT was 3.04 mSv. Typically, when KUB and tomograms are performed, a KUB is taken along with 3–4 tomograms. This yields a total dose of 3.97–5.07 mSv.

2.4.4 Recommendation

The role of KUB in the evaluation of urolithiasis is limited. It is a useful adjunct to ultrasound. It is also valuable to obtain a KUB for preoperative planning if SWL is being considered. KUB has limited utility as a follow-up exam for recurrent calcium stone formers to monitor their stone burden. If KUB and tomograms are to be obtained, consideration should be made to obtain a “low-dose” NCCT as the NCCT is more sensitive and exposes patients to less radiation. The main use of an IVP is in delineating the pelvi-calyceal anatomy and evaluating patients for obstruction.

2.5 Magnetic Resonance Imaging (MRI)

2.5.1 Indications

Calculi cannot be directly visualized using MRI. However, MRI can detect secondary signs of obstruction and can evaluate for possible alternative etiologies of pain. A number of different techniques and sequences have been proposed for the evaluation of urolithiasis. The most common technique is to look at the T2-weighted images and assess for signs of obstruction or look for filling defects which may be stones (Sudah et al. 2001, 2002; Regan et al. 2005; Kalb et al. 2010). In the evaluation of acute renal colic, the findings of perirenal fluid and ureteral dilation had a sensitivity and specificity of 93% and 95% for the diagnosis of ureteral calculi (Regan et al. 2005). Using a three-dimensional fast low-angle shot (3D FLASH) sequence, one group reported sensitivity between 96.2% and 100% and specificity of 100% for the diagnosis of a ureteral stone (Sudah et al. 2001). This was superior to T2-weighted images, but it required gadolinium contrast. The 3D FLASH sequence combined with T2-weighted images has been shown to be as sensitive and specific for the diagnosis of ureteral stones as NCCT (Sudah et al. 2002).

The advantage of MRI over NCCT is it does not expose patients to ionizing radiation. The disadvantages of MRI include cost and the length of time the imaging takes to complete. MRI also cannot

directly image a stone, so assessing for stone size can be difficult. Gadolinium contrast can aide in the measurement of stone size (Sudah et al. 2002). The use of gadolinium can add time to the study and adds the risk of contrast reaction.

2.5.2 Recommendations

MRI is not routinely used in the evaluation of urolithiasis. The fact that it does not expose patients to any radiation makes useful as a second-line study in pediatrics and pregnant women. In pediatrics, it can be helpful in delineating complicated anatomy such as calyceal diverticulum prior to surgical intervention. It can be useful to confirm obstruction and possibly identify a ureteral stone in pregnant women with renal colic and an equivocal ultrasound.

2.6 New Technology

2.6.1 Digital Tomosynthesis

Digital tomosynthesis (DT) is a new imaging technology that has potential applications for the evaluation of urolithiasis. In DT, a single scout KUB is taken. This is followed by a single tomographic sweep over a limited angle. A digital flat panel detector records the data from the sweep, and software reconstructs the data to provide high-resolution “slice” or coronal images at varying depths (Fig. 2.1). The image in each slice removes overlying structures such as bowel gas and provides depth information. The resolution of the images can allow for visualization of the collecting system. The depth information is useful in differentiating a calcification in the ureter versus an overlying spinal transverse process.

The primary current uses for DT are in chest radiography and breast imaging (Dobbins and McAdams 2009; Hakim et al. 2010). There have been reports of its use for the evaluation of urolithiasis (Mermuys et al. 2010; Wells et al. 2011). One study compared the ability to detect stones by DT and a KUB combined with a zoomed in shot of the pelvis using NCCT as the standard

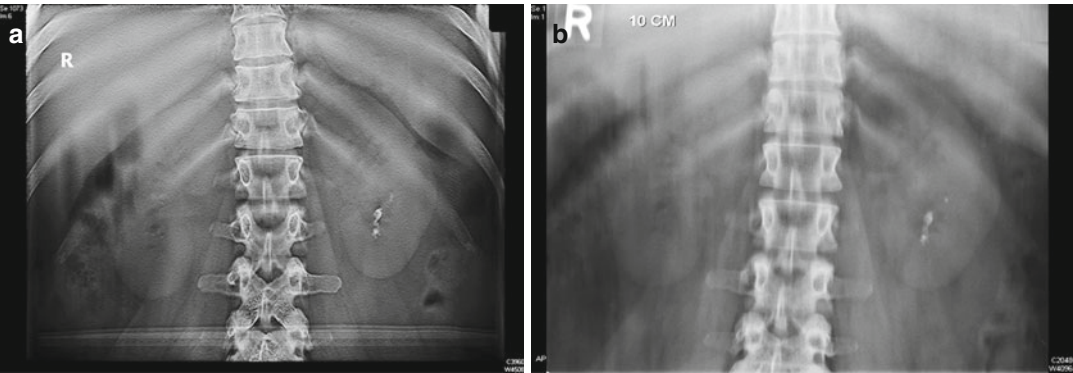


Fig. 2.1 Comparison of digital tomosynthesis (a) and a standard tomogram (b) in the same patient

Table 2.1 Comparison of different imaging modalities for the evaluation of nephrolithiasis

	Diagnostic accuracy	Time to perform exam	Radiation exposure
Non-contrast computed tomography	+++	+++	+
Ultrasound	++	++	+++
Plain abdominal radiography	+	+++	+
Excretory radiography	++	+	+
Magnetic resonance imaging	++	+	+++
Digital tomosynthesis	?	+++	++

(Mermuys et al. 2010). The authors found that DT was superior to KUB for the identification of renal stones but not ureteral stones. Another study looked at using DT to perform an IVP (Wells et al. 2011). In this study, two uro-radiologists evaluated the subjective diagnostic quality of traditional IVP and IVP with DT. They found that 95.5% of the IVPs with DT were of diagnostic quality versus 46.5% of the traditional IVPs. In addition, the dose of radiation was lower for the IVP with DT, and they took less time. The dose of radiation from DT has been shown to be lower than that of a “low-dose” NCCT (Mermuys et al. 2010; Wang et al. 2011) (Table 2.1).

References

Andreoiu M, MacMahon R (2009) Renal colic in pregnancy: lithiasis or physiological hydronephrosis? *Urology* 74:757–761

Berrington de Gonzalez A, Mahesh M, Kim KP et al (2009) Projected cancer risks from computed tomographic scans performed in the United States in 2007. *Arch Intern Med* 169:2071–2077

Brenner DJ, Hall EJ (2007) Computed tomography – an increasing source of radiation exposure. *N Engl J Med* 357:2277–2284

Dalrymple NC, Verga M, Anderson KR et al (1998) The value of unenhanced helical computerized tomography in the management of acute flank pain. *J Urol* 159: 735–740

Dobbins JT 3rd, McAdams HP (2009) Chest tomosynthesis: technical principles and clinical update. *Eur J Radiol* 72:244–251

Ege G, Akman H, Kuzucu K et al (2003) Acute ureterolithiasis: incidence of secondary signs on unenhanced helical CT and influence on patient management. *Clin Radiol* 58:990–994

Federle MP, McAninch JW, Kaiser JA et al (1981) Computed tomography of urinary calculi. *AJR Am J Roentgenol* 136:255–258

Ferrandino MN, Bagrodia A, Pierre SA (2009) Radiation exposure in the acute and short-term management of urolithiasis at 2 academic centers. *J Urol* 181:668–672, discussion 673

Ferrandino MN, Pierre SA, Simmons WN et al (2010) Dual-energy computed tomography with advanced postimage acquisition data processing: improved determination of urinary stone composition. *J Endourol* 24:347–354

Fowler KA, Locken JA, Duchesne JH et al (2002) US for detecting renal calculi with nonenhanced CT as a reference standard. *Radiology* 222:109–113

Gandolpho L, Sevilano M, Barbieri A (2001) Scintigraphy and Doppler ultrasonography for the evaluation of

- obstructive urinary calculi. *Braz J Med Biol Res* 34:745–751
- Goldwasser B, Cohan RH, Dunnick NR et al (1989) Role of linear tomography in evaluation of patients with nephrolithiasis. *Urology* 33:253–256
- Hakim CM, Chough DM, Ganott MA et al (2010) Digital breast tomosynthesis in the diagnostic environment: a subjective side-by-side review. *AJR Am J Roentgenol* 195:W172–W176
- Hamm M, Wawroschek F, Weckermann D et al (2001) Unenhanced helical computed tomography in the evaluation of acute flank pain. *Eur Urol* 39:460–465
- Hoppe H, Studer R, Kessler TM (2006) Alternate or additional findings to stone disease on unenhanced computerized tomography for acute flank pain can impact management. *J Urol* 175:1725–1730, discussion 1730
- Hopper KD, Yakes WF (1990) The posterior intercostal approach for percutaneous renal procedures: risk of puncturing the lung, spleen, and liver as determined by CT. *AJR Am J Roentgenol* 154:115–117
- Hyams ES, Korley FK, Pham JC et al (2011) Trends in imaging use during the emergency department evaluation of flank pain. *J Urol* 186:2270–2274
- Jackman SV, Potter SR, Regan F et al (2000) Plain abdominal x-ray versus computerized tomography screening: sensitivity for stone localization after non-enhanced spiral computerized tomography. *J Urol* 164:308–310
- Jellison FC, Smith JC, Heldt JP et al (2009) Effect of low dose radiation computerized tomography protocols on distal ureteral calculus detection. *J Urol* 182:2762–2767
- Jin DH, Lamberton GR, Broome DR et al (2010) Effect of reduced radiation CT protocols on the detection of renal calculi. *Radiology* 255:100–107
- Johnston R, Lin A, Du J et al (2009) Comparison of kidney-ureter-bladder abdominal radiography and computed tomography scout films for identifying renal calculi. *BJU Int* 104:670–673
- Joseph P, Mandal AK, Singh SK et al (2002) Computerized tomography attenuation value of renal calculus: can it predict successful fragmentation of the calculus by shock wave lithotripsy? A preliminary study. *J Urol* 167:1968–1971
- Kalb B, Sharma P, Salman K et al (2010) Acute abdominal pain: is there a potential role for MRI in the setting of the emergency department in a patient with renal calculi? *J Magn Reson Imaging* 32:1012–1023
- Katz DS, Scheer M, Lumerman JH et al (2000) Alternative or additional diagnoses on unenhanced helical computed tomography for suspected renal colic: experience with 1000 consecutive examinations. *Urology* 56:53–57
- Kavakli HS, Koktener A, Yilmaz A (2011) Diagnostic value of renal resistive index for the assessment of renal colic. *Singapore Med J* 52:271–273
- Kim BS, Hwang IK, Choi YW et al (2005) Low-dose and standard-dose unenhanced helical computed tomography for the assessment of acute renal colic: prospective comparative study. *Acta Radiol* 46:756–763
- Kluner C, Hein PA, Gralla O et al (2006) Does ultra-low-dose CT with a radiation dose equivalent to that of KUB suffice to detect renal and ureteral calculi? *J Comput Assist Tomogr* 30:44–50
- Lamb AD, Wines MD, Mousa S et al (2008) Plain radiography still is required in the planning of treatment for urolithiasis. *J Endourol* 22:2201–2205
- Levine JA, Neitlich J, Verga M et al (1997) Ureteral calculi in patients with flank pain: correlation of plain radiography with unenhanced helical CT. *Radiology* 204:27–31
- Manglaviti G, Tresoldi S, Guerrer CS et al (2011) In vivo evaluation of the chemical composition of urinary stones using dual-energy CT. *AJR Am J Roentgenol* 197:W76–W83
- Mermuys K, De Geeter F, Bacher K et al (2010) Digital tomosynthesis in the detection of urolithiasis: diagnostic performance and dosimetry compared with digital radiography with MDCT as the reference standard. *AJR Am J Roentgenol* 195:161–167
- Mettler FA Jr, Huda W, Yoshizumi TT et al (2008) Effective doses in radiology and diagnostic nuclear medicine: a catalog. *Radiology* 248:254–263
- Mitterberger M, Pinggera GM, Pallwein L et al (2007) Plain abdominal radiography with transabdominal native tissue harmonic imaging ultrasonography vs unenhanced computed tomography in renal colic. *BJU Int* 100:887–890
- Mitterberger M, Aigner F, Pallwein L et al (2009) Sonographic detection of renal and ureteral stones. Value of the twinkling sign. *Int Braz J Urol* 35:532–539, discussion 540–531
- Moesbergen TC, de Ryke RJ, Dunbar S et al (2011) Distal ureteral calculi: US follow-up. *Radiology* 260:575–580
- Mostafavi MR, Ernst RD, Saltzman B (1998) Accurate determination of chemical composition of urinary calculi by spiral computerized tomography. *J Urol* 159:673–675
- Mutgi A, Williams JW, Nettleman M (1991) Renal colic. Utility of the plain abdominal roentgenogram. *Arch Intern Med* 151:1589–1592
- Ng CS, Herts BR, Streem SB (2005) Percutaneous access to upper pole renal stones: role of prone 3-dimensional computerized tomography in inspiratory and expiratory phases. *J Urol* 173:124–126
- Niemann T, Kollmann T, Bongartz G (2008) Diagnostic performance of low-dose CT for the detection of urolithiasis: a meta-analysis. *AJR Am J Roentgenol* 191:396–401
- Pareek G, Hedican SP, Lee FT Jr et al (2005) Shock wave lithotripsy success determined by skin-to-stone distance on computed tomography. *Urology* 66:941–944
- Patel T, Kozakowski K, Hruby G et al (2009) Skin to stone distance is an independent predictor of stone-free status following shockwave lithotripsy. *J Endourol* 23:1383–1385
- Patlas M, Farkas A, Fisher D et al (2001) Ultrasound vs CT for the detection of ureteric stones in patients with renal colic. *Br J Radiol* 74:901–904
- Pepe P, Motta L, Pennisi M et al (2005) Functional evaluation of the urinary tract by color-Doppler ultrasonography (CDU) in 100 patients with renal colic. *Eur J Radiol* 53:131–135

- Perks AE, Schuler TD, Lee J et al (2008) Stone attenuation and skin-to-stone distance on computed tomography predicts for stone fragmentation by shock wave lithotripsy. *Urology* 72:765–769
- Pfister SA, Deckart A, Laschke S et al (2003) Unenhanced helical computed tomography vs intravenous urography in patients with acute flank pain: accuracy and economic impact in a randomized prospective trial. *Eur Radiol* 13:2513–2520
- Pichler R, Skradski V, Aigner F (2011) In young adults with a low body mass index ultrasonography is sufficient as a diagnostic tool for ureteric stones. *BJU Int* 109:770–774
- Poletti PA, Platon A, Rutschmann OT et al (2007) Low-dose versus standard-dose CT protocol in patients with clinically suspected renal colic. *AJR Am J Roentgenol* 188:927–933
- Ray AA, Ghiculete D, Pace KT et al (2010) Limitations to ultrasound in the detection and measurement of urinary tract calculi. *Urology* 76:295–300
- Regan F, Kuszyk B, Bohlman ME et al (2005) Acute ureteric calculus obstruction: unenhanced spiral CT versus HASTE MR urography and abdominal radiograph. *Br J Radiol* 78:506–511
- Ripolles T, Agramunt M, Errando J et al (2004) Suspected ureteral colic: plain film and sonography vs unenhanced helical CT. A prospective study in 66 patients. *Eur Radiol* 14:129–136
- Sandhu C, Anson KM, Patel U (2003) Urinary tract stones – Part I: role of radiological imaging in diagnosis and treatment planning. *Clin Radiol* 58:415–421
- Segal AJ, Spataro RF, Linke CA et al (1978) Diagnosis of nonopaque calculi by computed tomography. *Radiology* 129:447–450
- Shah K, Kurien A, Mishra S et al (2010) Predicting effectiveness of extracorporeal shockwave lithotripsy by stone attenuation value. *J Endourol* 24:1169–1173
- Sheafor DH, Hertzberg BS, Freed KS et al (2000) Nonenhanced helical CT and US in the emergency evaluation of patients with renal colic: prospective comparison. *Radiology* 217:792–797
- Shokeir AA, Abdulmaaboud M (1999) Resistive index in renal colic: a prospective study. *BJU Int* 83:378–382
- Shokeir AA, Abdulmaaboud M (2001) Prospective comparison of nonenhanced helical computerized tomography and Doppler ultrasonography for the diagnosis of renal colic. *J Urol* 165:1082–1084
- Smith RC, Rosenfield AT, Choe KA et al (1995) Acute flank pain: comparison of non-contrast-enhanced CT and intravenous urography. *Radiology* 194:789–794
- Smith RC, Verga M, McCarthy S et al (1996) Diagnosis of acute flank pain: value of unenhanced helical CT. *AJR Am J Roentgenol* 166:97–101
- Sudah M, Vanninen R, Partanen K et al (2001) MR urography in evaluation of acute flank pain: T2-weighted sequences and gadolinium-enhanced three-dimensional FLASH compared with urography. Fast low-angle shot. *AJR Am J Roentgenol* 176:105–112
- Sudah M, Vanninen RL, Partanen K et al (2002) Patients with acute flank pain: comparison of MR urography with unenhanced helical CT. *Radiology* 223:98–105
- Sundaram CP, Saltzman B (1999) Urolithiasis associated with protease inhibitors. *J Endourol* 13:309–312
- Tessler AN, Ghazi MR (1979) Case profile: computerized tomographic assistance in diagnosis of radiolucent calculi. *Urology* 13:672–673
- Ulusan S, Koc Z, Tokmak N (2007) Accuracy of sonography for detecting renal stone: comparison with CT. *J Clin Ultrasound* 35:256–261
- Unal D, Yeni E, Karaoglanoglu M et al (2003) Can conventional examinations contribute to the diagnostic power of unenhanced helical computed tomography in urolithiasis? *Urol Int* 70:31–35
- Vieweg J, Teh C, Freed K et al (1998) Unenhanced helical computerized tomography for the evaluation of patients with acute flank pain. *J Urol* 160:679–684
- Viprakasit DP, Sawyer MD, Herrell SD et al (2012) Limitations of ultrasonography in the evaluation of urolithiasis: a correlation with computed tomography. *J Endourol*. Mar;26(3):209–13. Epub 2011 Oct 19
- Wang AJ, Nguyen G, Toncheva G et al (2011) Radiation exposure from non-contrast CT, digital tomosynthesis, and standard KUB and tomograms. *J Endourol* 25:A304–A305
- Wells IT, Raju VM, Rowberry BK et al (2011) Digital tomosynthesis – a new lease of life for the intravenous urogram? *Br J Radiol* 84:464–468
- Westphalen AC, Hsia RY, Maselli JH et al (2011) Radiological imaging of patients with suspected urinary tract stones: national trends, diagnoses, and predictors. *Acad Emerg Med* 18:699–707
- White WM, Zite NB, Gash J et al (2007) Low-dose computed tomography for the evaluation of flank pain in the pregnant population. *J Endourol* 21:1255–1260
- Wiesenthal JD, Ghiculete D, RJ DAH (2010) Evaluating the importance of mean stone density and skin-to-stone distance in predicting successful shock wave lithotripsy of renal and ureteric calculi. *Urol Res* 38:307–313
- Yilmaz S, Sindel T, Arslan G et al (1998) Renal colic: comparison of spiral CT, US and IVU in the detection of ureteral calculi. *Eur Radiol* 8:212–217
- Zilberman DE, Ferrandino MN, Preminger GM et al (2010) In vivo determination of urinary stone composition using dual energy computerized tomography with advanced post-acquisition processing. *J Urol* 184:2354–2359
- Zilberman DE, Tsivian M, Lipkin ME et al (2011) Low dose computerized tomography for detection of urolithiasis – its effectiveness in the setting of the urology clinic. *J Urol* 185:910–914

Clinical Management of Urolithiasis

Knoll, Th.; Pearle, M.S. (Eds.)

2013, X, 222 p. 60 illus., 53 illus. in color., Hardcover

ISBN: 978-3-642-28731-2