

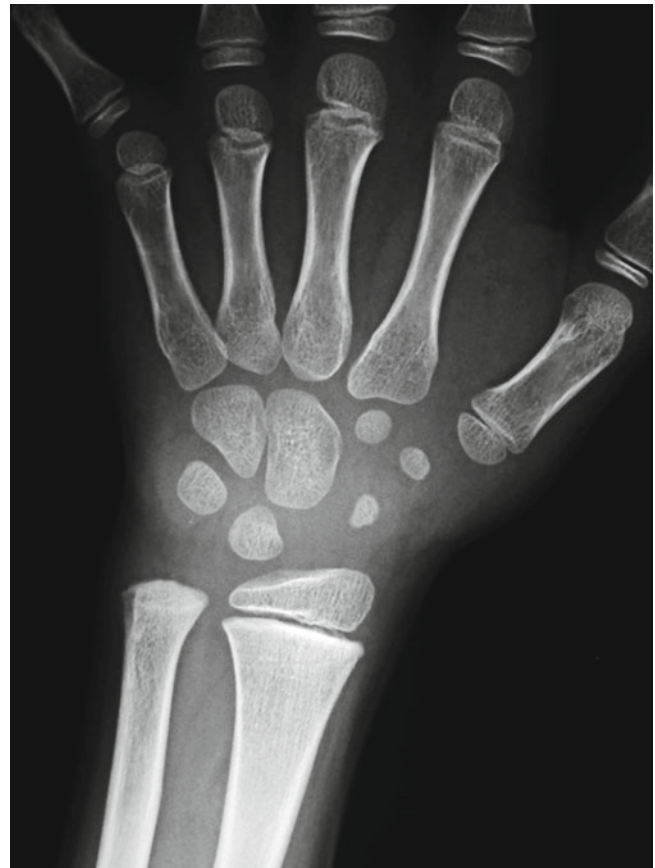## 2.1 Introduction

Many radiologists – even experienced and renowned professionals – do not feel comfortable with pediatric studies, including those related to the immature musculoskeletal system. The most important cause of this antipathy is, by far, lack of familiarity with the normal appearance of the growing skeleton and its developmental peculiarities; this unawareness is a barrier both to recognition of normal patterns and to the diagnosis of pathological findings. The purpose of this chapter is to provide the reader with a brief review of the anatomical, histological, and physiological bases of osteoarticular development, which are crucial for interpretation and understanding of pediatric imaging.

## 2.2 The Immature Epiphysis and the Physis

A unique feature of the immature skeleton is the presence of cartilaginous structures in the extremities of the long bones, namely, the epiphyseal cartilage and the physis (also referred to as primary physis, growth cartilage, or growth plate), which involute with skeletal maturation and are no longer present in the adult organism. These cartilages act together as a functional unit responsible for the longitudinal growth of the bone. On the other hand, the articular cartilage protects and nourishes the subchondral bone of the joint surfaces, and, unlike the physis and the epiphyseal cartilage, it does not disappear, remaining throughout the life course. Radiographs are insensitive to demonstrate these cartilages (Fig. 2.1), and computed tomography and ultrasonography are also limited in their evaluation. Because of its characteristics (see Chap. 1), magnetic resonance imaging (MRI) is the preferred imaging method for assessment of most structures of the immature bone (Fig. 2.2).

The immature epiphysis is situated between the joint cavity and the physis. During the early stages of development, the epiphyses are entirely cartilaginous, serving as precursors for the ossified ends of the long bones. The

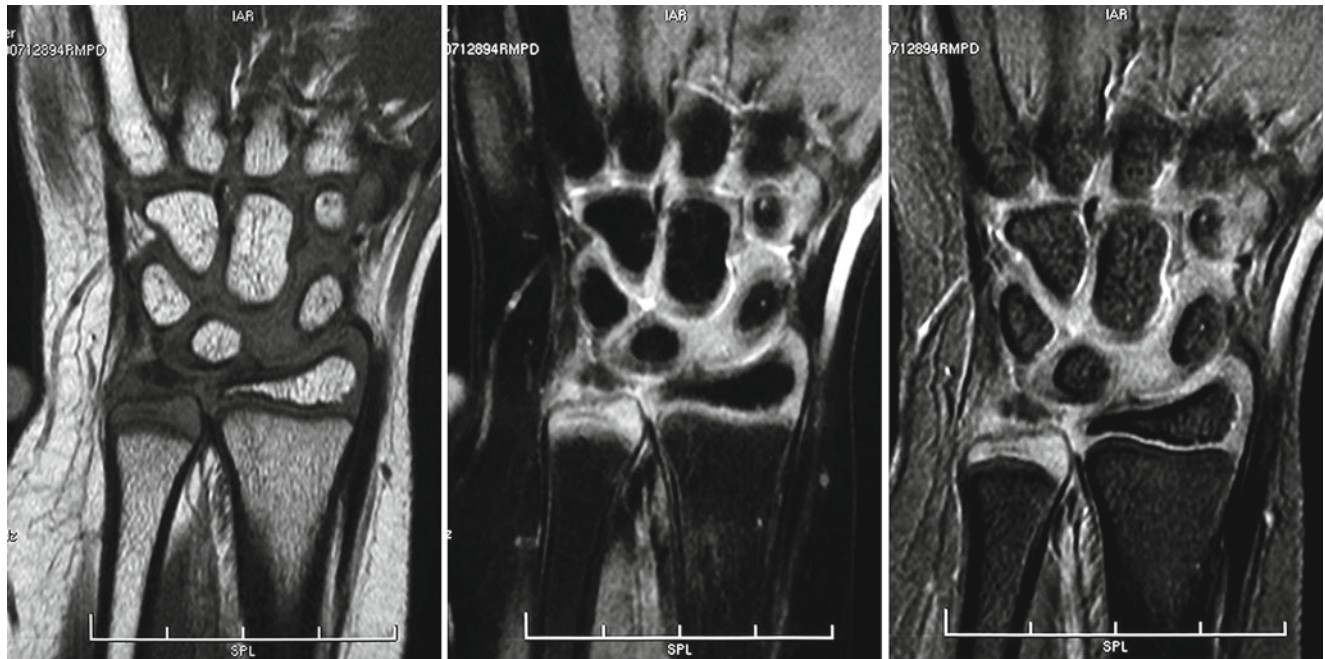


**Fig. 2.1** Radiograph of the right wrist of an 8-year-old male showing that ossification has already begun in the carpal bones and in the distal radial epiphysis. However, as radiographs are fairly insensitive for cartilaginous assessment, only an indirect estimate of the thickness of the physes, of the cartilaginous anlage of the carpal bones, and of the epiphyseal cartilages can be made. The distal epiphysis of the ulna is entirely cartilaginous and completely invisible

cartilaginous epiphysis usually display low signal intensity on T1-weighted images (T1-WI) and intermediate to high signal intensity in fluid-sensitive sequences. Transformation of cartilage into bone begins in the inner portion of the epiphysis, the so-called secondary ossification center (the primary ossification centers form the diaphyses of the tubular

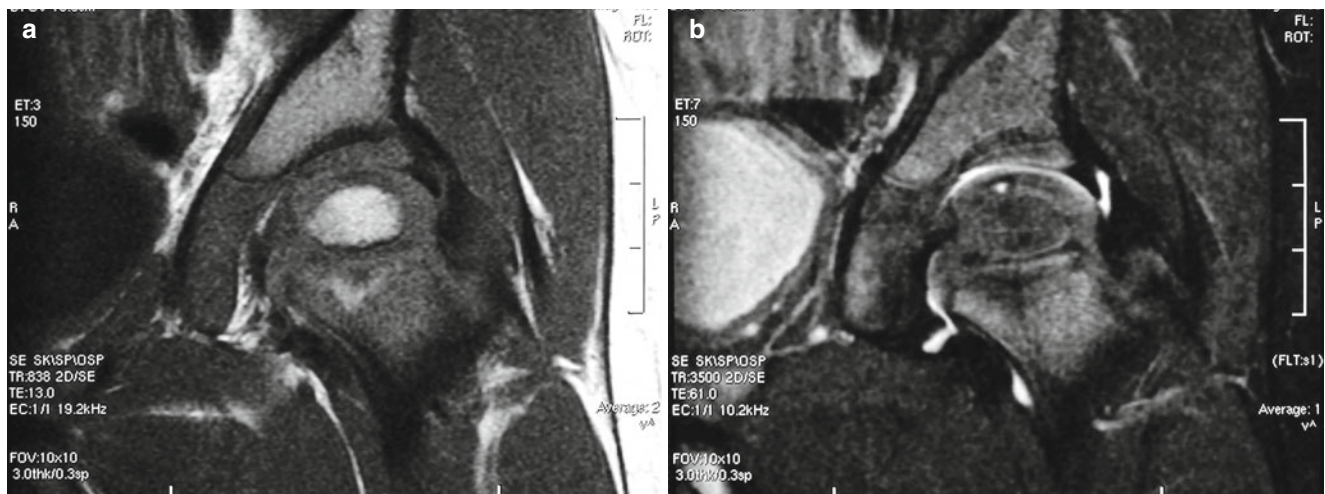
bones during intrauterine life). Ossification may occur in a single center (like in the proximal or distal femoral epiphyses – Fig. 2.3) or, less often, via multiple secondary ossification centers that later coalesce (such as in the distal humerus – Fig. 2.4). The secondary ossification center is surrounded by a specialized structure, the secondary physis, responsible for the endochondral ossification and

structurally similar to the primary physis, appearing as a thin layer of high signal intensity on fluid-sensitive sequences (Figs. 2.5 and 2.6). The ossification center, which is round when it first appears, changes to a hemispheric configuration over time: it increases in size and molds to the contour of the epiphysis in which it is settled, at the same time as there is thinning of the epiphyseal cartilage (Fig. 2.7). The epiphyseal



**Fig. 2.2** MRI of the right wrist of a young male whose age is similar to that of the child in Fig. 2.1. Coronal T1-WI (left), fat sat PD-WI (center), and gradient-echo image (right) show that the ossified portions of the carpal bones are isointense with the medullary bone seen in the metacarpals, the distal metaphyses of the radius and the ulna, and the ossified portion of the distal epiphysis of the radius. Even though

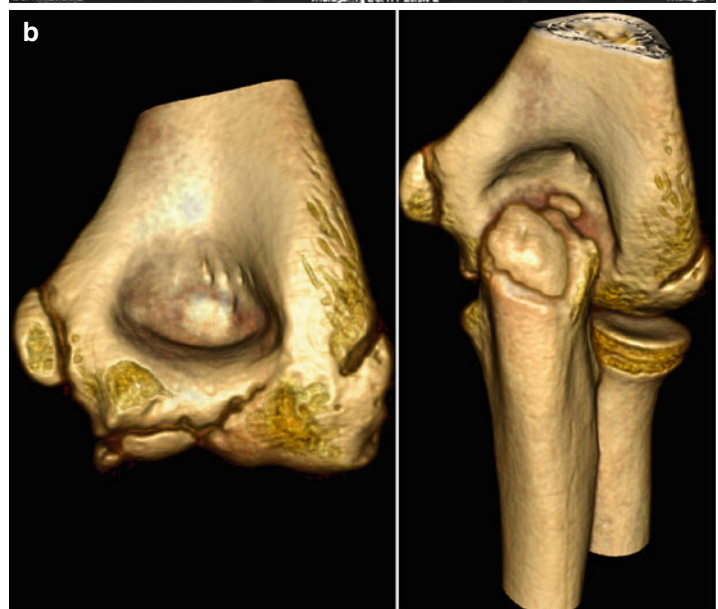
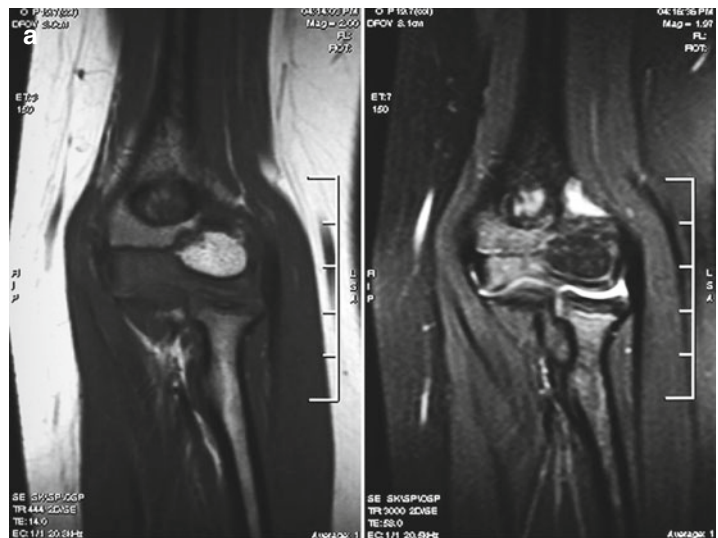
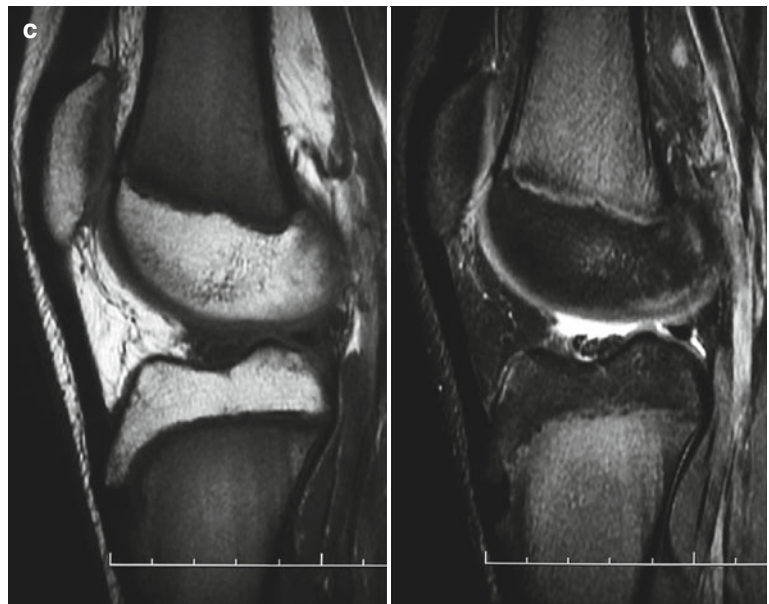
the distal epiphysis of the ulna is entirely cartilaginous, the epiphyseal cartilage is clearly seen, presenting low to intermediate signal intensity on T1-WI and intermediate to high signal intensity in the other sequences; a similar behavior is seen in the cartilaginous anlage of the carpal bones and in the cartilaginous portion of the distal epiphysis of the radius



**Fig. 2.3** Coronal T1-WI (a) and fat sat T2-WI (b) of the left hip of a 3-year-old male. The secondary ossification center of the femoral head is already present, whose bone marrow has undergone complete conversion to the fatty type, while the bone marrow of the femoral metaphysis and of the iliac bone presents predominance of the hematopoietic variety. The epiphyseal cartilage is predominantly isointense on T1-WI and

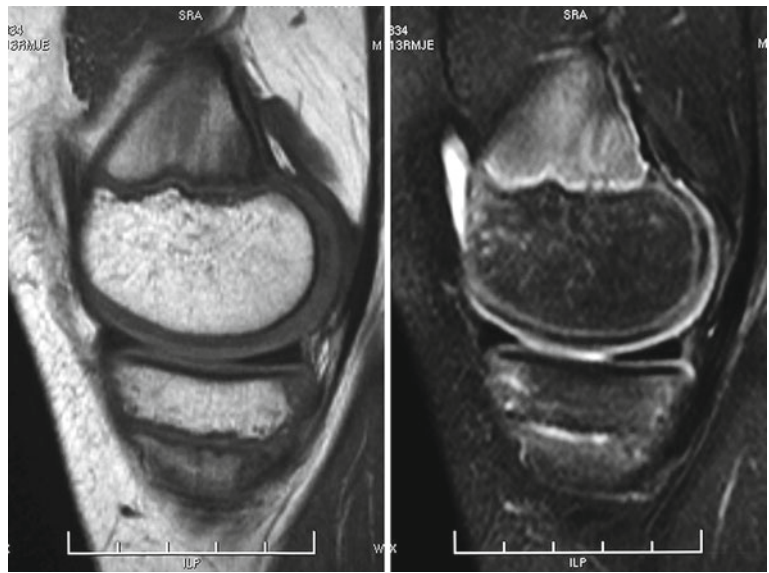shows intermediate signal intensity on fat sat T2-WI. There is a small focus of increased signal intensity on T2-WI in the apex of the epiphyseal cartilage, related to pre-ossification changes. The difference between the signal intensity of the yellow marrow (epiphyseal) and the red marrow (metaphyseal and diaphyseal) is even more striking in sagittal images of the knee of a school-aged child (c)



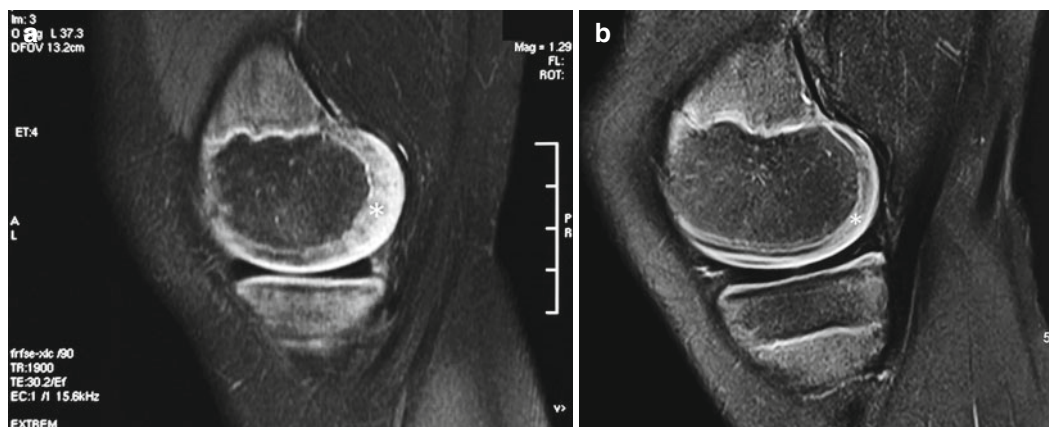
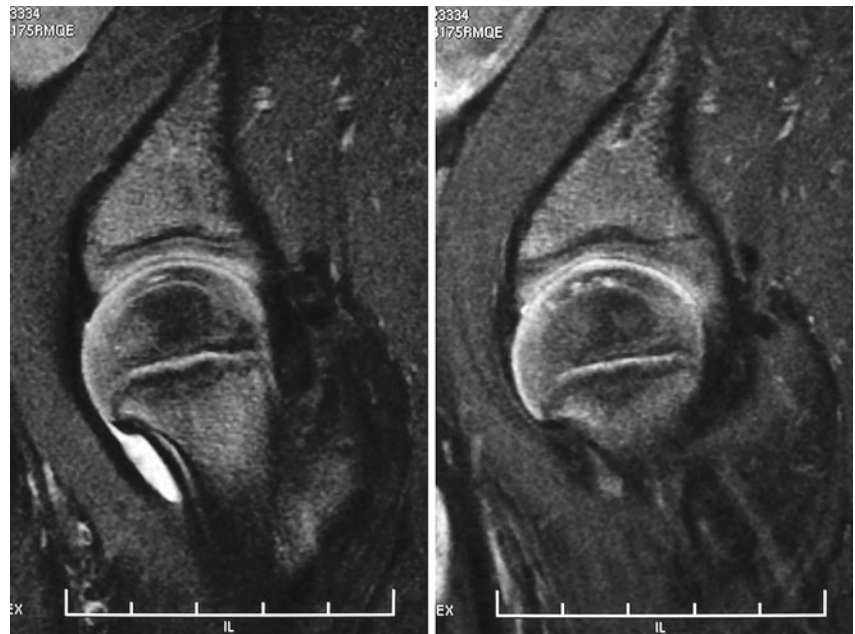
**Fig. 2.3** (continued)

**Fig. 2.4** In (a), coronal T1-WI (*left*) and fat sat T2-WI (*right*) of the left elbow of a 6-year-old female show that the ossification center of the capitulum is already filled with yellow marrow. The trochlear portion of the distal epiphysis of the humerus is completely cartilaginous, and increased signal intensity is seen in this cartilage on fat sat T2-WI, representing pre-ossification phenomena. In (b), volume-rendered CT reconstructions of the left elbow of a 13-year-old male demonstrate that all the ossification centers are ossified, with partial fusion of the ossification center of the capitulum. Despite the excellent anatomic detail of bone provided by CT, very limited information can be obtained with this imaging method about the cartilaginous structures

**Fig. 2.5** Sagittal T1-WI (*left*) and fat sat T2-WI (*right*) of the right knee of a 13-year-old male. The secondary physis and the articular cartilage of the distal femur are clearly identified on fat sat T2-WI as linear areas of high signal intensity situated between the ossified and the cartilaginous portion of the epiphysis and along the joint surface of the epiphyseal cartilage, respectively. Bone marrow conversion is already completed in the epiphyses, while there is residual red marrow in the metaphyses, with its typical flame-shaped appearance



**Fig. 2.6** Sagittal fat sat T2-WI of the left hip of a toddler. Although the epiphyseal cartilage displays predominantly intermediate signal intensity, there is low signal intensity in the weight-bearing zone, located in the uppermost portion of the epiphysis. In addition, foci of increased signal intensity are also found in the apex of the epiphyseal cartilage, related to ongoing ossification. The secondary physis appears as a thin hyperintense line surrounding the secondary ossification center, between the latter and the epiphyseal cartilage. The physis and the articular cartilage are also hyperintense if compared to the epiphyseal cartilage

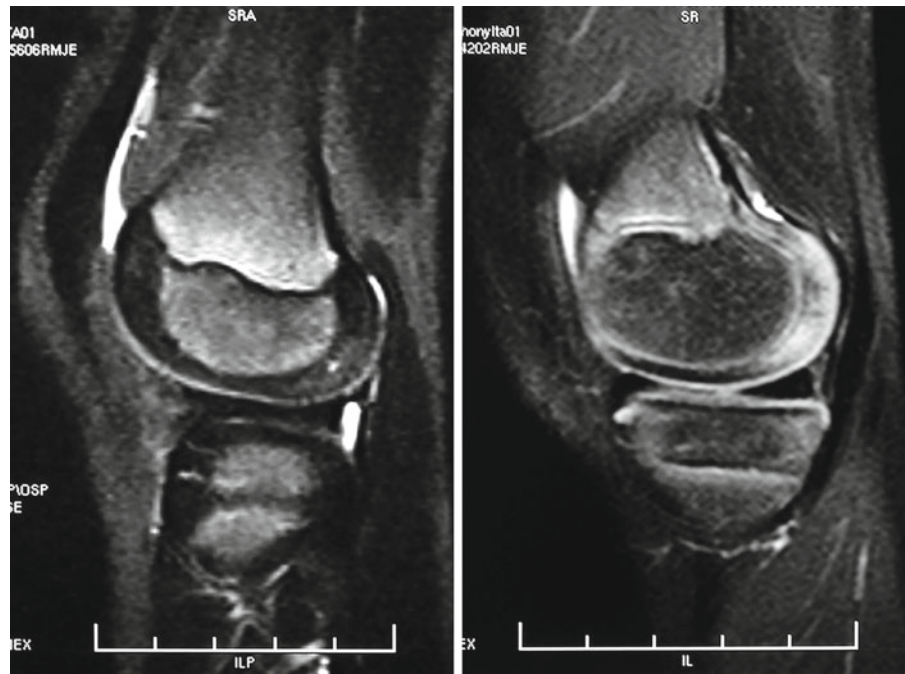


**Fig. 2.7** Sagittal PD-WI of the medial femoral condyles of two different children – the first is a 7-year-old subject (*a*) and the second one is a 13-year-old (*b*) – displaying the epiphyseal cartilage (\*) as a structure of

intermediate signal intensity between the hyperintense articular cartilage and the hypointense secondary ossification center. The ossification center is smaller, and the cartilage is proportionally thicker in younger children

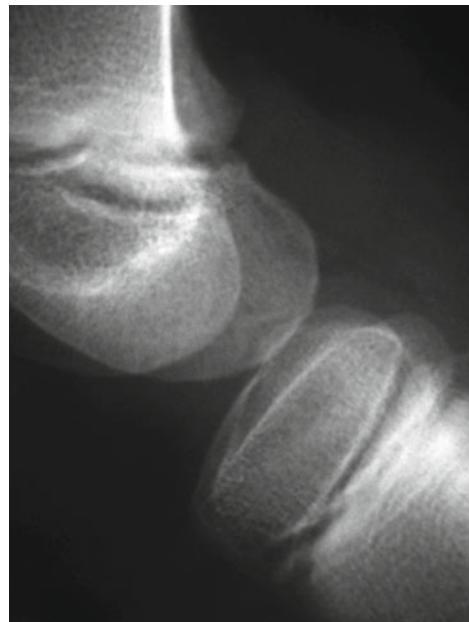


**Fig. 2.8** Sagittal fat sat T2-WI of the knees of two different male children, a 5-year-old (*left*) and a 7-year-old (*right*). There is rapid epiphyseal growth over time, with increase in the size of the secondary ossification center and reduction of the thickness of the epiphyseal cartilage. In the first image, marked hyperintensity is present in the primary spongiosa of the distal femur; a zone of increased signal intensity within the posterior portion of the epiphyseal cartilage of the femoral condyle represents ongoing ossification. The second image also shows hyperintensity of the posterior portion of the epiphyseal cartilage, more diffuse if compared to that seen in the first child. The focal area of decreased signal intensity seen in the weight-bearing zone of the epiphyseal cartilage of the femur in the second image is deprived of significance, typical of ambulating children



cartilage is homogeneous throughout the first year of life, but, as skeleton maturation takes place, focal areas of high signal intensity on T2-WI appear, more evident in the posterior aspect of the femoral condyles. Such areas are more common in preadolescent males and are typically not associated with abnormalities of the subchondral bone, being deprived of significance and representing the earliest stages of endochondral ossification (Figs. 2.3, 2.4, and 2.6). They are initially focal and heterogeneous, becoming more extensive and uniform with time (Fig. 2.8). As the child begins to walk, the weight-bearing portions of the epiphyseal cartilages present a decrease in their signal intensity on T2-WI, more evident in the knees and the hips, also deprived of importance (Figs. 2.6 and 2.8). Irregularity of the secondary ossification centers at the bone/cartilage junction is a normal finding, mostly seen during growth spurts (Fig. 2.9). Accessory ossification centers may also be present, usually adjoining the posterior aspect of the secondary ossification center of the distal femur, not associated with bone marrow edema or abnormalities of the overlying cartilage. The articular cartilage is hardly discernible on T1-WI, appearing as a thin layer of high signal intensity surrounding the immature epiphysis on T2-WI (Figs. 2.5, 2.6, 2.7, and 2.10).

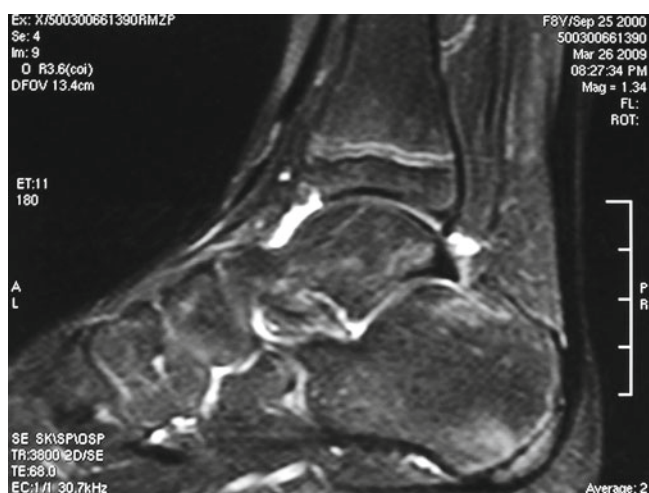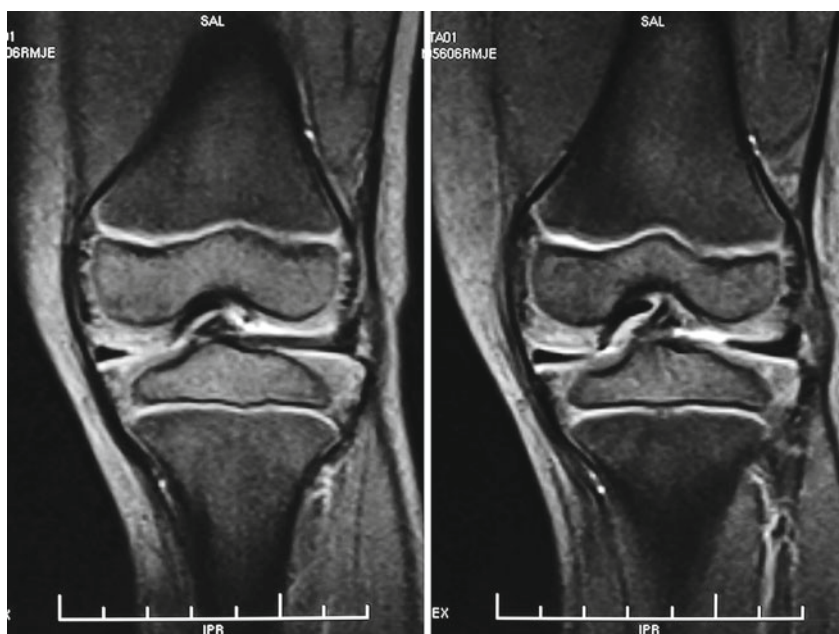
The physis is a specialized area of the bone, situated between the epiphysis and the metaphysis. It is divided into several zones, each one of them with distinct histological appearances and functions in the process of endochondral ossification. The germinal layer (resting zone) abuts the epiphysis and is composed mainly by abundant matrix and loosely organized chondrocytes, providing the cells responsible for growth; lesions of this layer (such as



**Fig. 2.9** Lateral view of the right knee of a 9-year-old female. The irregular contour of the femoral condyles is a normal finding, related to skeletal maturation

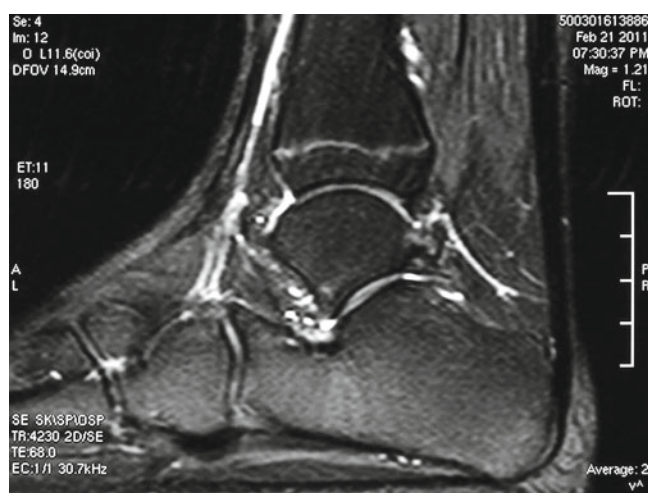
those found in transphyseal fractures, for instance) may lead to arrested bone growth. The proliferating zone is constituted by flattened chondrocytes with intense mitotic activity, which are arranged in columns and separated by bars of chondroid matrix. These columns of cells present continuous migration to the metaphysis, fed by cellular division in their basal portions. Conversely, there is

**Fig. 2.10** Coronal gradient-echo images of the left knee of a 5-year-old child. The epiphyseal cartilages of the distal femur and of the proximal tibia are clearly distinguished from the adjacent articular cartilages: the latter are noticeably brighter, with signal intensity similar to that of the physal cartilage. The smooth and regular physes are typical of small children. As the menisci are composed of fibrocartilage, they appear as triangular structures with uniform low signal intensity



**Fig. 2.11** Sagittal fat sat T2-WI of the right ankle of an 8-year-old female. The distal physis of the tibia presents the classic three-layered appearance, with high signal intensity in the physal cartilage and in the primary spongiosa and an intervening line of low signal intensity corresponding to the provisional calcification zone. The physis is almost flat, a normal finding for the patient's age. Foci of increased signal intensity are seen in the medullary bone of the hindfoot and midfoot representing perivascular residual red marrow, a finding with no significance

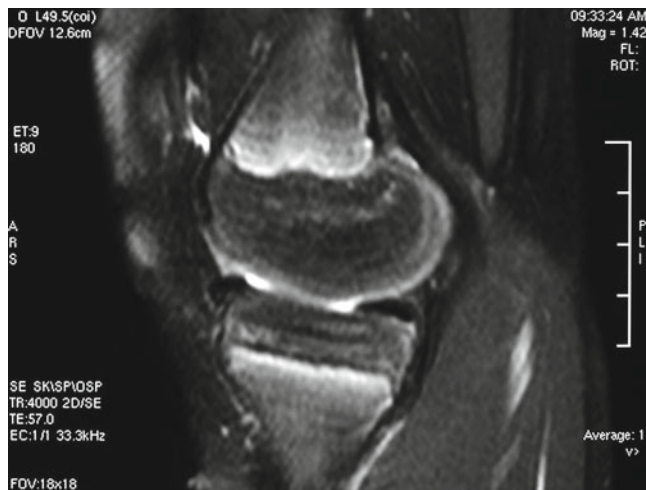no active cellular division in the hypertrophic cell zone, where the chondrocytes reach their maximum size and undergo vacuolation. Finally, after the death of the chondrocytes and upon production of alkaline phosphatase in the provisional calcification zone, the metaphyseal vessels invade the extracellular matrix, which becomes mineralized and serve as a scaffold for the osteogenesis. These vessels bring osteoprogenitor cells, which differentiate into osteoblasts and form bone in the spaces left



**Fig. 2.12** Sagittal fat sat T2-WI of the right ankle of a 12-year-old female. If compared to the child of Fig. 2.11, the distal tibial physis is wavier and presents reduced thickness, findings related to progression of bone maturation. The calcaneal apophysis is already incorporated to the body of the bone

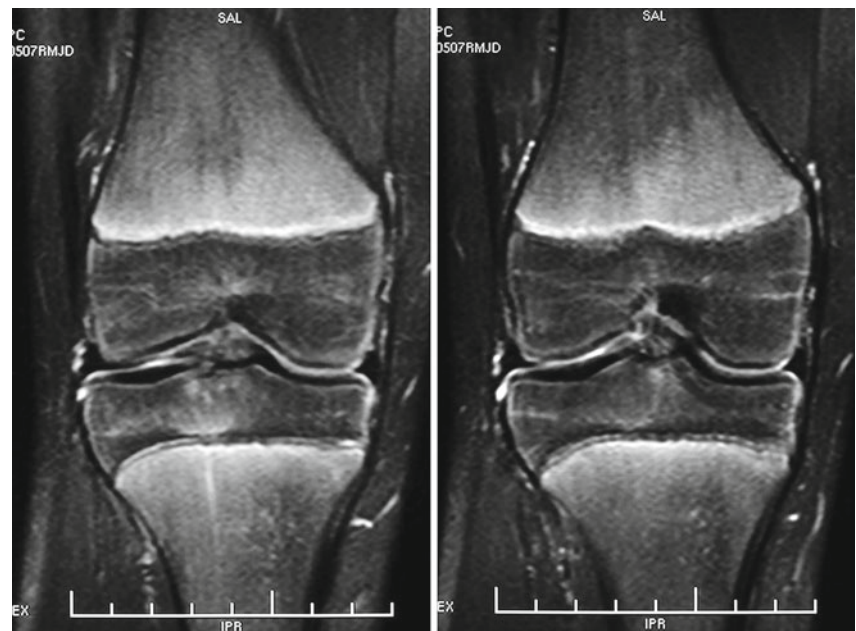
behind by the chondrocytes. The thickness of the physis is relatively uniform during growth due to a strict balance between production of cartilage and removal of chondrocytes.

The physes of young children are flat, becoming wavy as the growth advances (Figs. 2.10, 2.11, and 2.12). The primary spongiosa is the portion of the metaphysis adjacent to the physis, composed of newly formed bone, which appears hyperintense on fluid-sensitive sequences (Figs. 2.8,



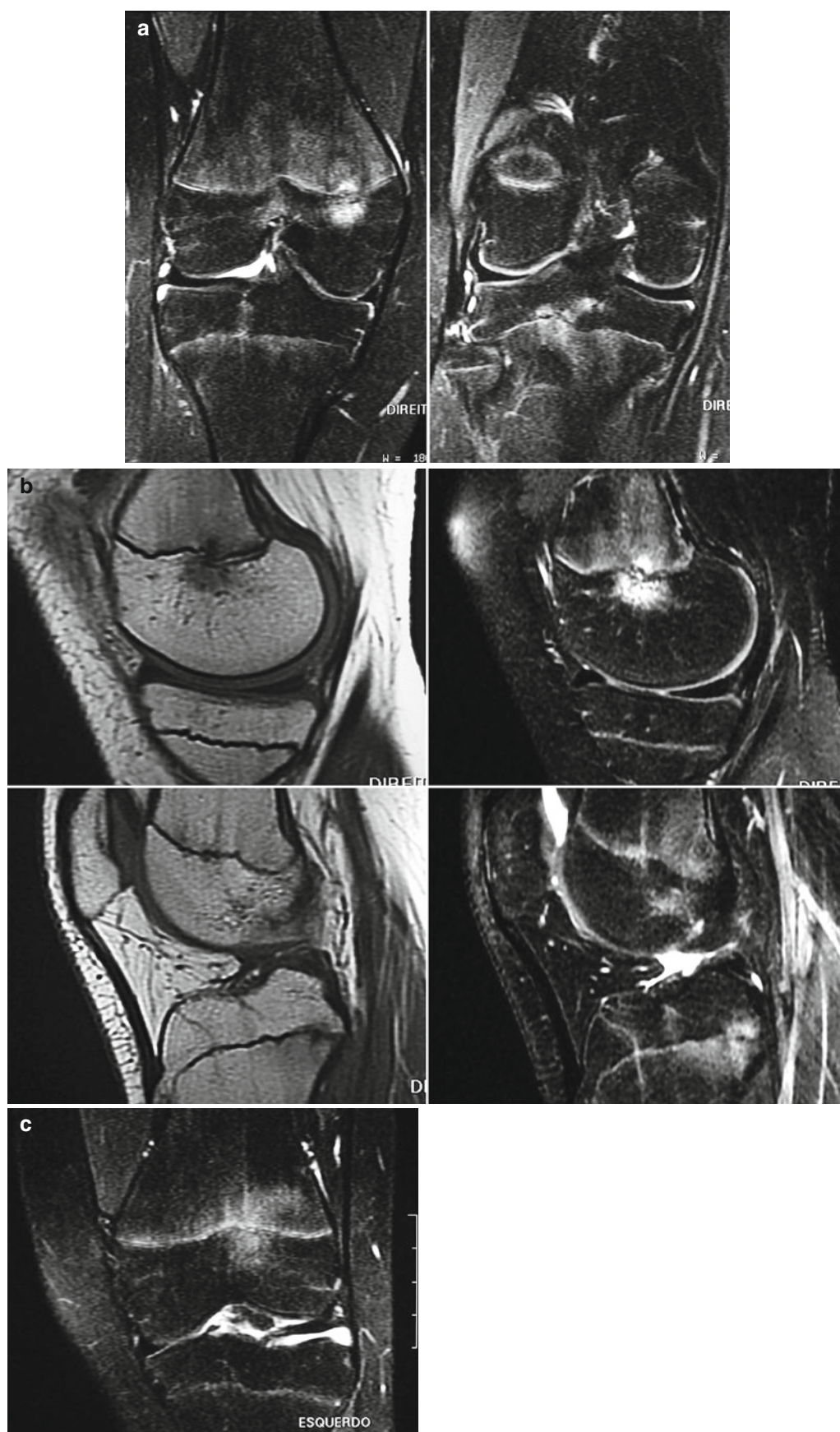
**Fig. 2.13** Sagittal T2-WI of the left knee of a 10-year-old male. There is increased signal intensity in the primary spongiosa of the distal femur and proximal tibia, which should not be confused with bone marrow edema pattern

2.11, 2.13, and 2.14). The several physal zones cannot be discriminated as distinct regions on MRI; nevertheless, the normal physis has a three-layered appearance. In addition to the primary spongiosa, it is possible to distinguish the provisional calcification zone, which is hypointense in all sequences because of its mineralized matrix, and the physal cartilage itself, which displays intermediate/high signal intensity on fluid-sensitive sequences (Figs. 2.11 and 2.14). Once bone maturation is completed, there is progressive narrowing of the physis until its eventual disappearance (Fig. 2.12), leaving only the physal scar. Areas of bone marrow edema centered about the physis are occasionally found in adolescents, notably in the knees. Such areas of focal periphyseal edema affect the epiphyseal and the metaphyseal bone marrow and may be occasionally painful, representing the early stages of physal closure (Fig. 2.15); in the authors' experience, post-contrast enhancement may also be present (Fig. 2.16). They can be found in more than one bone in the same joint or even in more than one joint at the same time. Open physes usually act as barriers between the epiphyseal and metaphyseal vascular beds, limiting the propagation of neoplastic lesions and infections (Fig. 2.17).



**Fig. 2.14** Coronal fat sat T2-WI of the right knee of a 13-year-old male. The physes display their characteristic three-layered appearance, which is more evident in the proximal tibia. Intermediate to high signal intensity can be seen in the flame-shaped red marrow of the metaphyses, notably in the distal femur

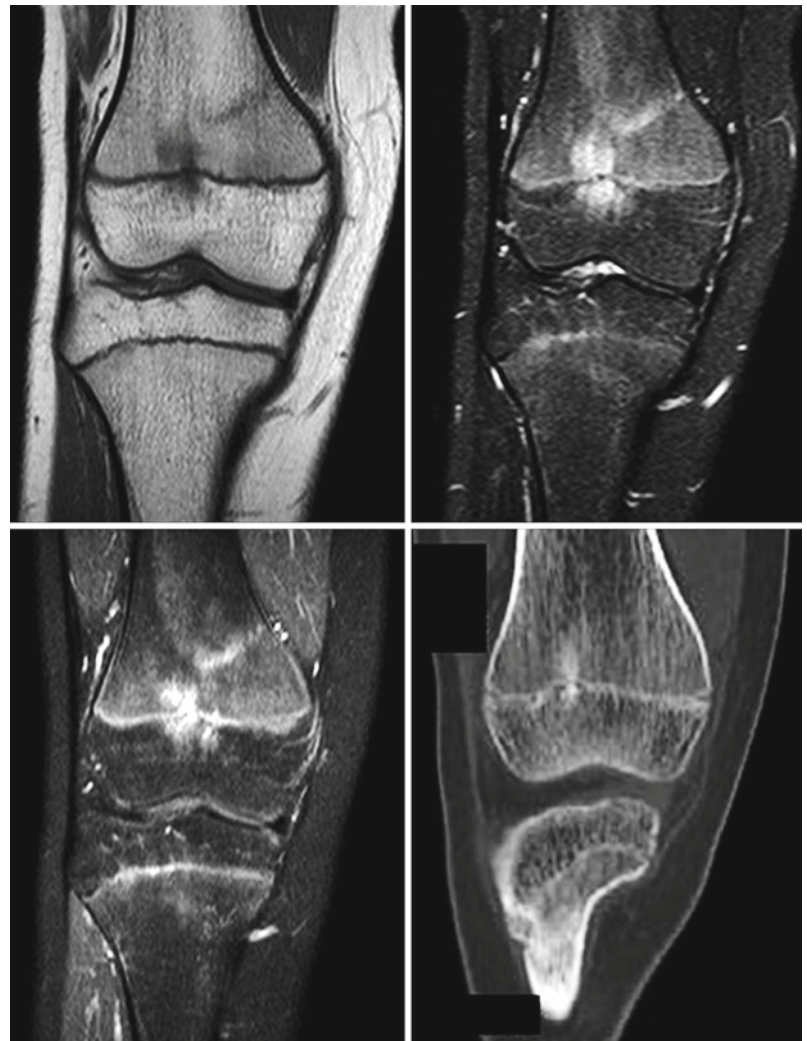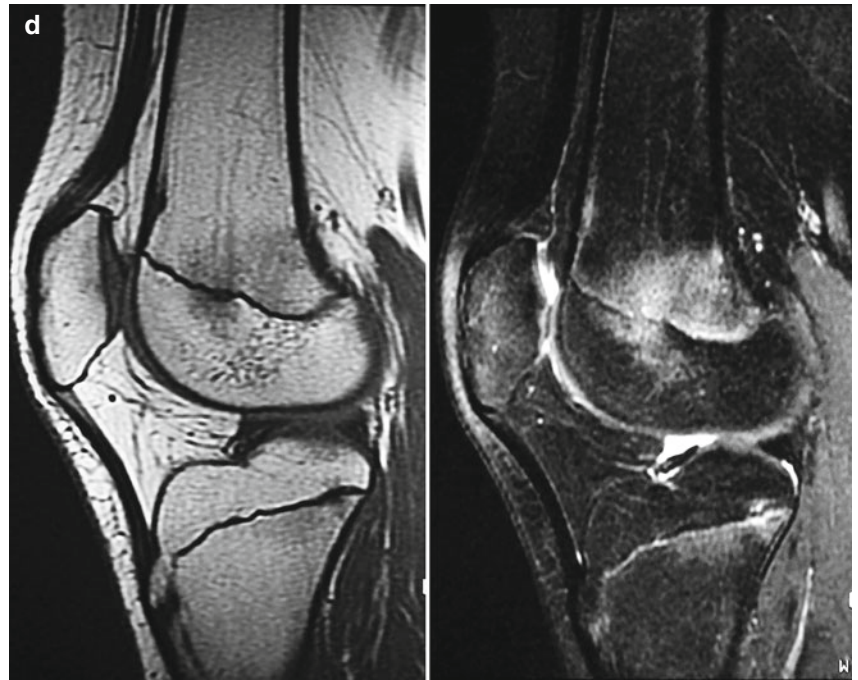




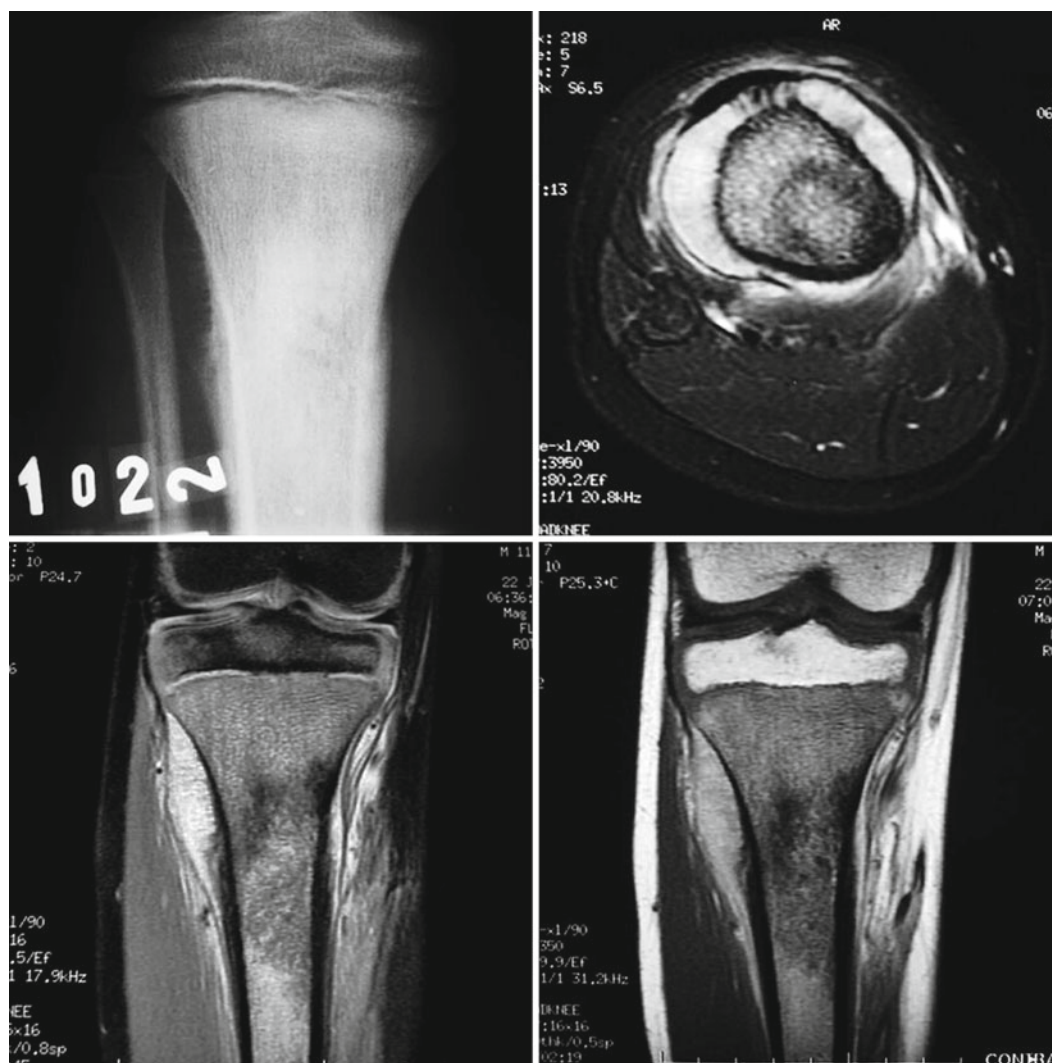**Fig. 2.15** A 14-year-old female complaining of pain in both knees. Coronal fat sat PD-WI (a) and sagittal T1-WI (b, *upper row*) and fat sat PD-WI (b, *lower row*) of the right knee reveal focal areas of bone

marrow edema pattern centered about the physes of the distal femur and proximal tibia. Similar findings can be seen in the contralateral femur (c and d)



**Fig. 2.15** (continued)

**Fig. 2.16** A 13-year-old female complaining of right-sided knee pain. Coronal T1-WI (*upper-left image*) and fat sat T2-WI (*upper-right image*) demonstrate bone marrow edema centered about the distal femoral physis, with questionable physeal narrowing. Post-gadolinium fat sat T1-WI (*lower-left image*) discloses enhancement of the edematous bone marrow, while coronal reformatted CT image of the same knee (*lower-right image*) shows sclerosis of the cancellous bone in the affected area and unequivocal focal narrowing of the growth plate



**Fig. 2.17** An 11-year-old male with aggressive sarcoma of the right proximal tibia. In addition to an anteroposterior view of the proximal leg (*upper-left image*), transverse fat sat T2-WI (*upper-right image*), coronal fat sat T2-WI (*lower-left image*), and post-gadolinium fat sat T1-WI (*lower-right image*) are also shown. Radiograph reveals heterogeneous

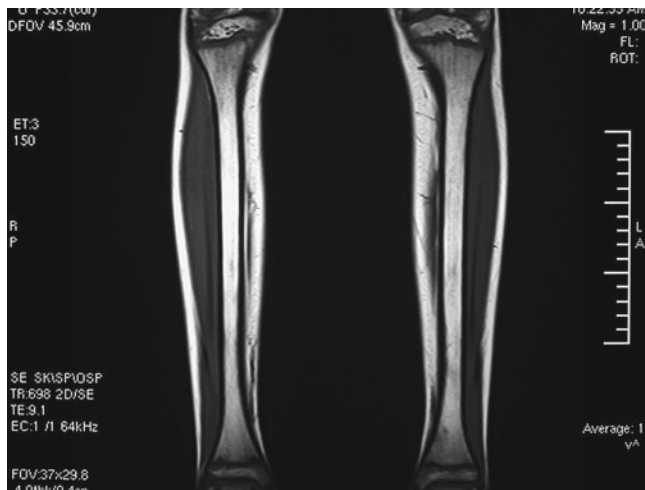bone sclerosis, spiculated periosteal reaction, and an adjacent soft-tissue mass. On MRI, the bone marrow of the proximal metadiaphysis of the tibia is diffusely infiltrated by the tumor, with extensive subperiosteal component. Nonetheless, the proximal tibial epiphysis presents normal signal intensity, as the progression of the sarcoma was halted by the physis

### 2.3 Pediatric Bone Marrow

The bone marrow is the main hematopoietic organ. As a result of its variable and dynamic composition, its appearance on imaging changes considerably during skeletal maturation. For instance, in newborns, the bone marrow is entirely of the hematopoietic type (red marrow), which presents low signal intensity on T1-WI (similar or higher than that of the skeletal muscle) and intermediate to high signal intensity on fluid-sensitive sequences (Fig. 2.3). The conversion of red marrow to

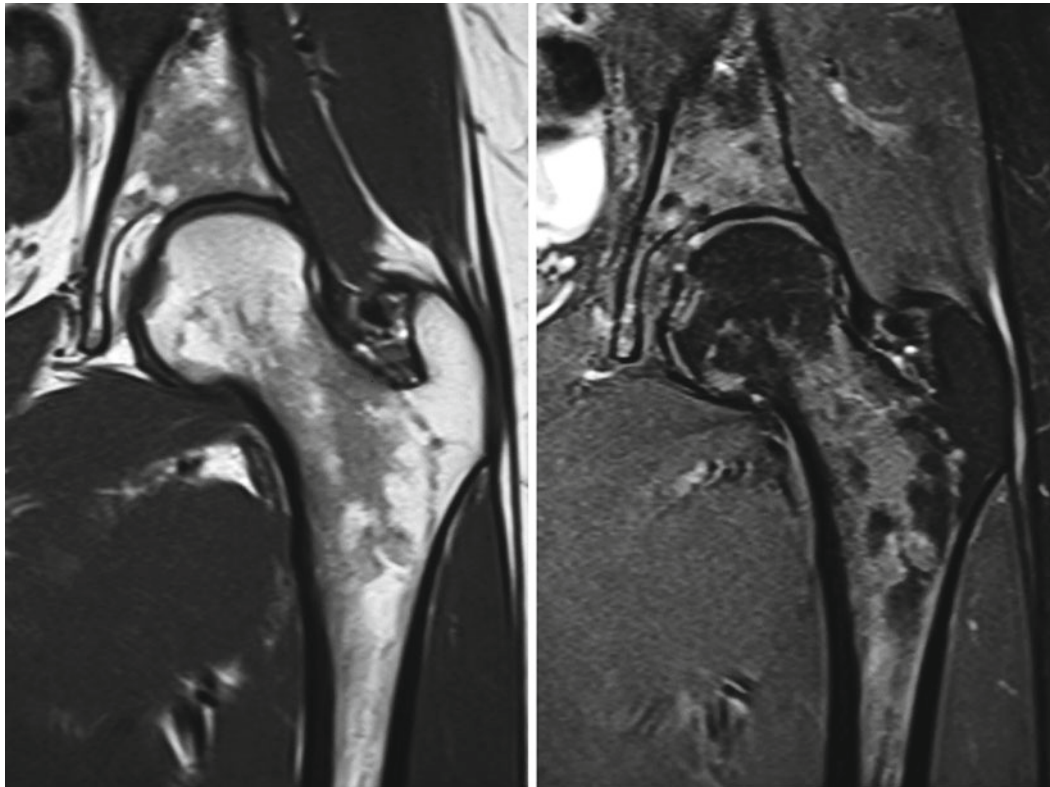
yellow (fatty) marrow in the appendicular skeleton begins in the first year of life and happens expeditiously, following a stereotyped pattern, being almost complete by the time of skeletal maturity. As the yellow marrow is composed mostly by fat, conversion leads to increase in the signal intensity of the bone marrow on T1-WI and signal drop in sequences with fat suppression, a behavior that is similar to that of the subcutaneous tissue. The conversion process starts in the distal portions of the limbs (phalanges of hands and feet) and advances centripetally to the proximal bones (humeri and femora). However, if





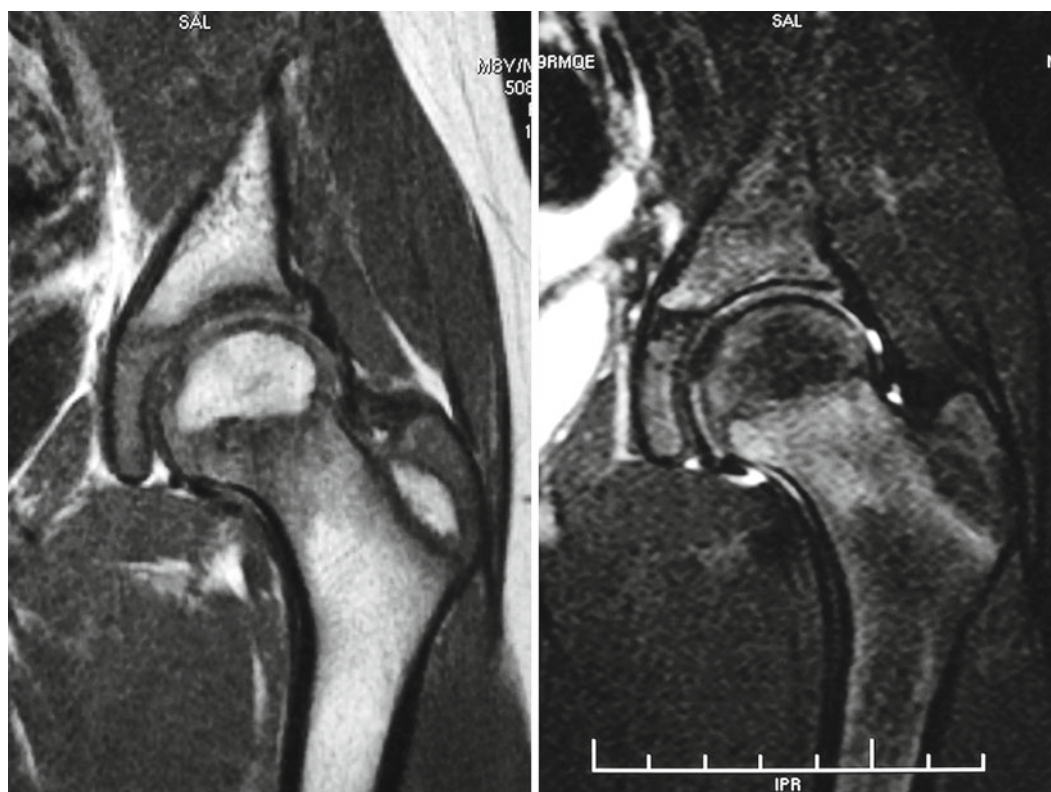
**Fig. 2.18** Coronal T1-WI of the legs of a 10-year-old male demonstrating the normal centrifugal pattern of bone marrow conversion, with preponderance of the hyperintense yellow marrow in the tibial diaphysis and residual red marrow predominantly located in the metaphyses, mainly the proximal ones

the long bones are considered individually, the pattern of marrow replacement is centrifugal, beginning in the mid-diaphysis and advancing towards the metaphyses (Fig. 2.18). In the epiphyses, although the bone marrow of the newly formed secondary ossification centers is essentially of the hematopoietic type, conversion takes place within 6 months of their radiographic appearance (Figs. 2.2, 2.3, 2.4, and 2.5). On T1-WI, vertebrae are usually hypointense if compared to disks during the first year of life, becoming isointense/slightly hyperintense from the first to the fifth year and hyperintense from then on. On fluid-sensitive sequences, the signal intensity of the vertebrae presents progressive reduction if compared to the skeletal muscle, going from isointense/slightly hyperintense in young children to hypointense in older individuals. Marrow conversion is progressive and continuous in the axial skeleton, also occurring throughout adult life. In the pelvic bones, marrow conversion is usually more heterogeneous, intertwining areas of red marrow and yellow marrow (Fig. 2.19).



**Fig. 2.19** Coronal T1-WI (*left*) and fat sat T2-WI (*right*) of the left hip of a 35-year-old female. There is residual red marrow intertwined with yellow marrow, the former predominantly found in the proximal femoral

metadiaphysis and in the iliac bone. Red marrow is no longer present in the femoral epiphysis and in the greater trochanter, which are completely filled by yellow marrow



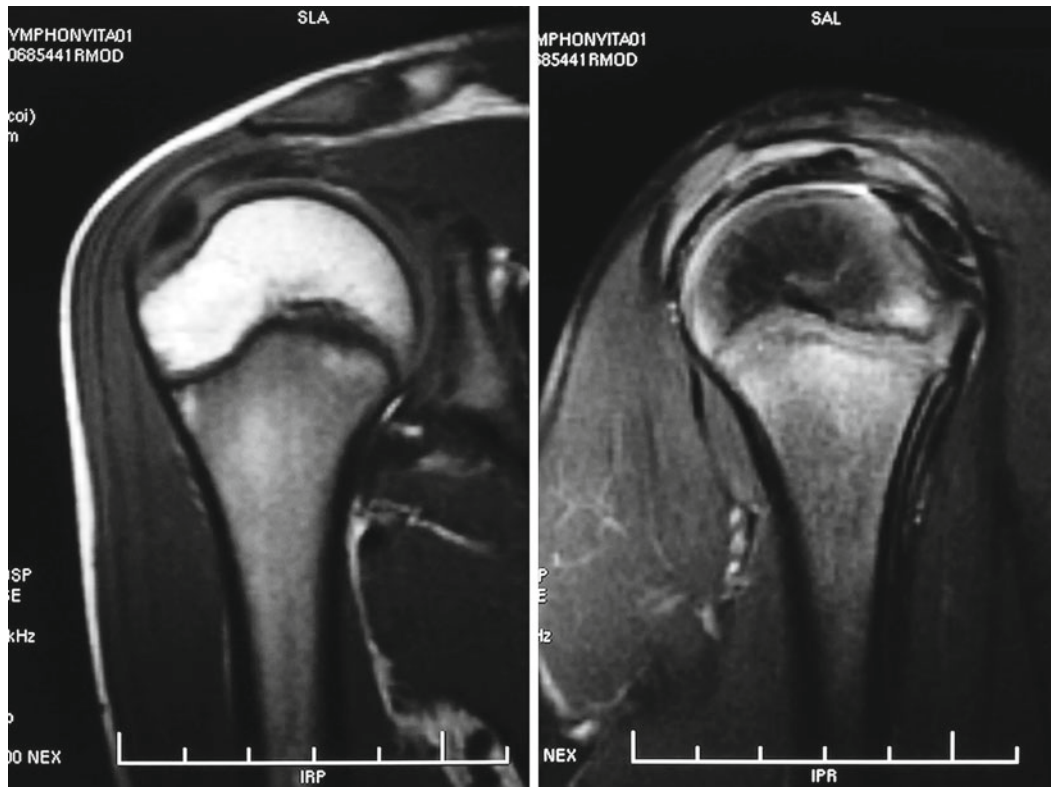
**Fig. 2.20** Coronal T1-WI (*left*) and fat sat T2-WI (*right*) of the left hip of an 8-year-old male. A thick cartilaginous anlage is still present in greater trochanter apophysis, while ossification of the femoral head is

far more advanced. The secondary ossification center of the femoral epiphysis shows complete conversion to yellow marrow, while red marrow is still predominant in the metaphysis

It is important to keep in mind some normal and peculiar aspects of the pediatric bone marrow that may be mistakenly construed as abnormal. Residual red marrow adjacent to the metaphysis, for instance, has a typical “flame-shaped” appearance, based on the physis and showing imprecise borders; it blends gradually with the adjacent yellow marrow, without trabecular distortion or associated mass effect (Figs. 2.5, 2.14, 2.18, and 2.20). The vast majority of pathologic marrow lesions will display very low signal intensity on T1-WI and marked hyperintensity in fluid-sensitive sequences (Fig. 2.17). T1 is the most important imaging sequence for this kind of assessment, as fluid-sensitive sequences frequently overestimate

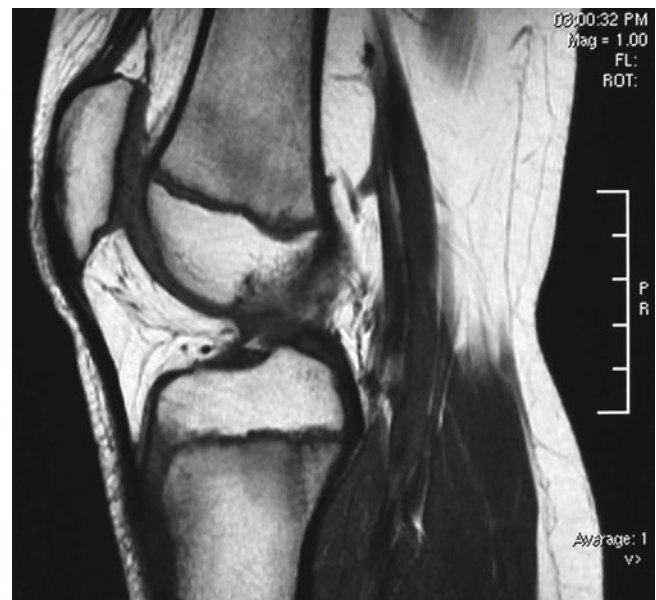
the signal intensity of the red marrow (Figs. 2.20, 2.21, and 2.22). Residual red marrow is commonly found in the proximal metaphysis of the long bones of young adults and should not be confused with marrow infiltration (Fig. 2.19). Additionally, a significant percentage of asymptomatic children will present residual perivascular islets of red marrow in their ankles and feet, usually bilateral and symmetric, without clinical significance (Fig. 2.11). Postgadolinium enhancement is found in the normal bone marrow, mainly in the red marrow of young children (Fig. 2.23), and in the primary spongiosa. Physeal enhancement is more prominent than that of the epiphyseal cartilage (Fig. 2.23).





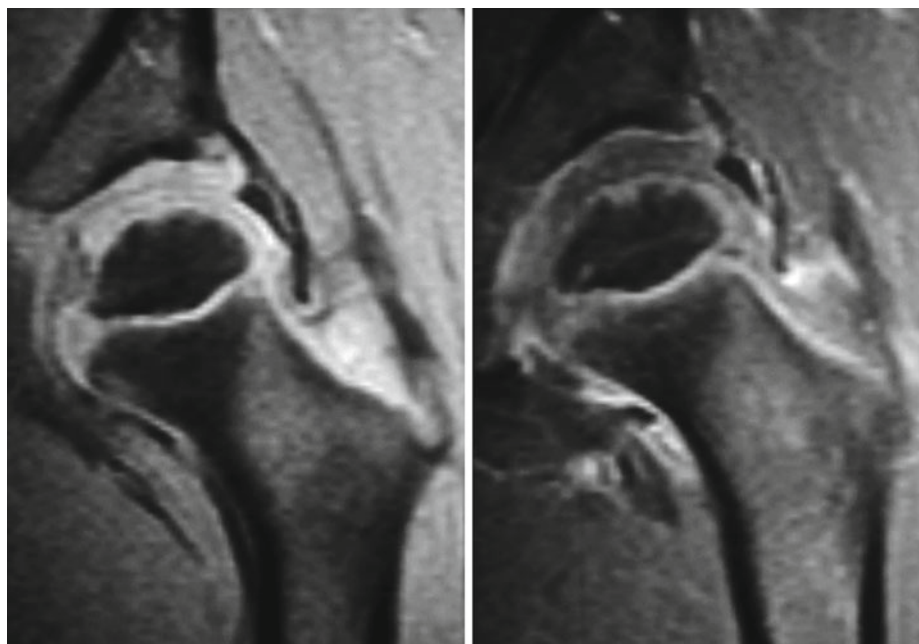
**Fig. 2.21** Coronal T1-WI (*left*) and sagittal fat sat T2-WI (*right*) of the right shoulder of a 10-year-old male. The secondary ossification center of the proximal epiphysis of the humerus presents complete bone marrow conversion, and its signal intensity is identical to that of the

subcutaneous fat in all sequences. Marrow conversion of the diaphyseal and metaphyseal regions is still happening, with predominance of red marrow in juxtaphyseal areas, characterized by intermediate signal intensity on T1-WI and high signal intensity on fat sat T2-WI



**Fig. 2.22** Sagittal T1-WI of the left knee of a 13-year-old male demonstrating the appropriateness of T1-weighted sequences for the assessment of bone marrow. While the epiphyseal yellow marrow presents high signal intensity, similar to that of the subcutaneous fat, metaphyseal red marrow presents low signal intensity. However, red marrow is hyperintense if compared to the skeletal muscle, excluding the possibility of marrow infiltration

**Fig. 2.23** Contrast-enhanced MRI of the left hip of a 13-year-old male, coronal fat sat T1-WI before (*left*) and after (*right*) intravenous administration of gadolinium. Enhancement of the red marrow (mostly diaphyseal) is more intense than that of the yellow marrow (mainly epiphyseal and metaphyseal). Physeal enhancement is more intense than that seen in the epiphyseal cartilage



#### Key Points

- The epiphyseal cartilage and the physis act together as a functional unit, responsible for longitudinal growth of the bone. The appearance of these structures change along the course of skeletal development, and awareness of these normal changes will avoid erroneous interpretation.
- The epiphysis is entirely cartilaginous in newborns, undergoing progressive ossification that begins in its innermost portion, the secondary ossification center. Changes in the signal intensity of the epiphyseal cartilage related to pre-ossification phenomena should not be confused with cartilaginous injuries.
- The physis has a typical three-layered appearance on fluid-sensitive sequences, constituted by the hyperintense physeal cartilage, the hypointense provisional calcification zone, and the hyperintense primary spongiosa. In adolescents, areas of focal periphyseal edema can be found and are probably related to closure of the growth plates.
- The appearance of the normal bone marrow changes significantly with growth. In newborns, the marrow is entirely of the hematopoietic type (red), presenting progressive conversion to fatty (yellow) marrow as the skeletal maturation advances. Residual areas of red marrow intertwined with yellow marrow are a major pitfall in MRI interpretation.

#### Recommended Readings

- Barnewolt CE, Shapiro F, Jaramillo D (1997) Normal gadolinium-enhanced MR images of the developing appendicular skeleton: part 1. Cartilaginous epiphysis and physis. *AJR Am J Roentgenol* 169(1):183–189
- Burdiles A, Babyn PS (2009) Pediatric bone marrow MR imaging. *Magn Reson Imaging Clin N Am* 17(3):391–409
- Ecklund K, Jaramillo D (2001) Imaging of growth disturbance in children. *Radiol Clin North Am* 39(4):823–841
- Jans LB, Jaremko JL, Ditchfield M, Verstraete KL (2011) Evolution of femoral condylar ossification at MR imaging: frequency and patient age distribution. *Radiology* 258(3):880–888
- Jaramillo D (2008) Cartilage imaging. *Pediatr Radiol* 38(Suppl 2):S256–S258
- Jaramillo D, Hoffer FA (1992) Cartilaginous epiphysis and growth plate: normal and abnormal MR imaging findings. *AJR Am J Roentgenol* 158(5):1105–1110
- Kan JH (2008) Major pitfalls in musculoskeletal imaging-MRI. *Pediatr Radiol* 38(Suppl 2):S251–S255
- Kellenberger CJ (2009) Pitfalls in paediatric musculoskeletal imaging. *Pediatr Radiol* 39(Suppl 3):372–381
- Khanna PC, Thapa MM (2009) The growing skeleton: MR imaging appearances of developing cartilage. *Magn Reson Imaging Clin N Am* 17(3):411–421
- Laor T, Jaramillo D (2009) MR imaging insights into skeletal maturation: what is normal? *Radiology* 250(1):28–38
- Murphy DT, Moynagh MR, Eustace SJ, Kavanagh EC (2010) Bone marrow. *Magn Reson Imaging Clin N Am* 18(4):727–735
- Parfitt AM, Travers R, Rauch F, Glorieux FH (2000) Structural and cellular changes during bone growth in healthy children. *Bone* 27(4):487–494
- Vande Berg BC, Malghem J, Lecouvet FE, Maldague B (2001) La moelle osseuse normale: aspects dynamiques en imagerie par résonance magnétique. *J Radiol* 82(2):127–135
- Varich LJ, Laor T, Jaramillo D (2000) Normal maturation of the distal femoral epiphyseal cartilage: age-related changes at MR imaging. *Radiology* 214(3):705–709
- Zbojniec AM, Laor T (2011) Focal Periphyseal Edema (FOPE) zone on MRI of the adolescent knee: a potentially painful manifestation of physiologic physeal fusion? *AJR Am J Roentgenol* 197(4):998–1004



Joint Imaging in Childhood and Adolescence

Viana, S.L.; Machado Ribeiro, M.C.; Beber Machado, B.

2013, XI, 328 p., Hardcover

ISBN: 978-3-642-35875-3