

Chapter 2

The Cytoarchitectonic Map of Constantin von Economo and Georg N. Koskinas

Lazaros C. Triarhou

Abstract In 1925 Constantin von Economo (1876–1931) and Georg N. Koskinas (1885–1975), working in the Psychiatric Clinic of Julius Wagner-Jauregg (1857–1940) at the University of Vienna, published their monumental *Atlas and Textbook of Cytoarchitectonics of the Adult Human Cerebral Cortex*, following in the footsteps of Theodor Meynert (1833–1892) and Korbinian Brodmann (1868–1918). Von Economo and Koskinas provided a much more detailed verbal and pictorial description of the variations in cellular structure (cytoarchitecture) of cerebral cortical layers, compared to Brodmann. By dissecting each gyrus and sulcus perpendicularly to its axis, von Economo and Koskinas successfully addressed the core problem of flattening out the convoluted polyhedral surface of the human cerebral mantle. They defined five structural cortical *types* (agranular, frontal, parietal, polar, and granulous) and 107 cytoarchitectonic area *modifications* (35 frontal, 13 limbic, 6 insular, 18 parietal, 7 occipital, 14 temporal, and 14 hippocampal). Their numerous discoveries include the *koniocortex*, i.e. the dusty appearance of sensory areas, and the identification, at the boundaries of koniocortex with ordinary isocortex in parietal, temporal and occipital areas, of thin bands with giant pyramidal cells, the so-called *parasensory zones*. Von Economo and Koskinas also provided the first comprehensive description of the distinct rod and corkscrew cells in cingulate and frontoinsular areas known today as “von Economo neurons” that are putatively involved in social behavior and the pathophysiology of neurodevelopmental and mental diseases. The cortical cytoarchitectonics system of von Economo and Koskinas may be especially meaningful in conjunction with modern studies on functional imaging in the human brain.

L.C. Triarhou (✉)

Economo-Koskinas Wing for Integrative and Evolutionary Neuroscience, University of Macedonia, Egnatia 156, Bldg. Z-312, 54006 Thessaloniki, Greece
e-mail: triarhou@uom.gr

2.1 Introduction

“The cortex is both chaos and order, and therein lies its strength.” With these words the neuroanatomist Gerhardt von Bonin (1890–1979) summarized in his classical essay on the cerebral cortex (von Bonin 1950) the quintessence of the cerebral hemispheric mantle.

The inextricability of cerebral morphology and function was exemplified in the writings of the neurobiologist Christfried Jakob (1866–1956): “Form is stabilized function and function is change of form; the organism is a single entity that presents itself as form in the latent state and as function in the kinetic state. . . . Form, structure and function are inseparable, if not identical, and only scholastic science has managed to separate them. . . . Only a basis that is fundamentally biological, morphostructural and histophysiological at the same time, unified in an ample ontogenetic and phylogenetic context, can let us address in legitimate ways the fundamental questions of modern neuro- and psychobiopathology” (Jakob 1939, 1941; Triarhou 2010; Triarhou and del Cerro 2006).

One of the overarching grand challenges of neuroscience for the twenty-first century is how does the brain work and produce mental activity and how does physical activity in the brain give rise to behavior (Hougan and Altevogt 2008). It is argued that the field of understanding how the mind works may move forward to its full potential only when we gain a better insight into the physical instantiation of nervous systems by constructing connectional maps that integrate anatomy, neuronal activity and function.

In the early twentieth century, the holding tenet among neuroanatomists was that deciphering cortical cell architecture is a preamble to understanding the mind. Essential contributions to cortical histology by Félix Vicq d’Azyr (1748–1794), Theodor Meynert (1833–1892), Vladimir A. Betz (1834–1894), W. Bevan Lewis (1847–1929), Santiago Ramón y Cajal (1852–1934), Theodor Kaes (1852–1913), Christfried Jakob (1866–1956), Alfred Walter Campbell (1868–1937), Korbinian Brodmann (1868–1918), Oskar Vogt (1870–1959), Sir Grafton Elliot Smith (1871–1937), and Cécile Mugnier-Vogt (1875–1962) formed the basis upon which Baron Constantin von Economo (1876–1931) and Georg N. Koskinas (1885–1975), from patrician Greek families rooted in the Hellenic regions of Macedonia and Lacedaemonia, respectively (Fig. 2.1), produced their *magnum opus* on the adult human cerebral cortex (von Economo and Koskinas 1925). The historical merit and its modern perspective are discussed elsewhere (von Economo 2009; von Economo and Koskinas 2008; Zilles 2004; Zilles and Amunts 2012).

With his landmark monograph, Brodmann (1909) defined 44 cortical cytoarchitectonic areas in the human brain (and a total of 52 areas in the primate brain overall). He studied cortical cytoarchitecture in numerous mammals, from the hedgehog, with its unusually large archipallium, to primates and humans, and introduced the terms *homogenetic* and *heterogenetic formations* to denote two different basic cortical patterns with either the typical six layers or lacking the six-layer stage, respectively (Garey 2006; Zilles and Amunts 2010).



Fig. 2.1 Constantin von Economo (1876–1931), Professor of Psychiatry and Neurology at the University of Vienna, *left*, and Georg N. Koskinas (1885–1975), former Assistant at the Psychiatric and Neurological Clinic of the University of Athens, *right*. For his discovery of encephalitis lethargica, von Economo was nominated three times for the Nobel Prize in Physiology or Medicine between 1926 and 1932. Koskinas returned to Greece in 1927; after an unsuccessful application for the chair of Neurology at the University of Athens, he devoted himself to private practice in the suburb of Kifisia (Triarhou 2005) (Photo credits: Bildarchiv und Grafiksammlung der Österreichischen Nationalbibliothek, Vienna (Economo); Helios Encyclopedic Lexicon, Athens (Koskinas). Used by permission and protected by copyright law. Copying, redistribution or retransmission without the author’s express written permission is prohibited)

Vogt and Vogt (1919) laid the foundations of myeloarchitectonics (the architecture of fiber pathways) and defined the structural features of *allocortex*, *proisocortex* and *isocortex*; they also analyzed the differences between *paleocortical*, *archicortical*, and *neocortical* regions (Vogt and Vogt 1919; Vogt 1927; Zilles 2004; Zilles and Amunts 2012).

Von Economo commenced his work on cortical cytoarchitectonics in 1912, and Koskinas joined him in 1919. Their Atlas and Text Volume were published in 1925, and included 150 new discoveries (Koskinas 1931). Von Economo and Koskinas (1925, 2008) defined 107 area *modifications*, and more than 60 area *transitions* (von Economo 2009), virtually raising the “resolution” of our cortical cytoarchitectonic register, compared to Brodmann’s data, by a factor of four.

In subsequent decades, by combining cytoarchitectonics with myeloarchitectonics, Sanides (1962, 1964) placed emphasis on transitions or gradations that accompany “streams” of neocortical regions coming from paleocortical and archicortical sources (Pandya and Sanides 1973), while Vogt and Vogt (1919) had already spoken of “areal gradations”.

Comprehensive tables correlating the 107 cortical areas defined by von Economo and Koskinas with the Brodmann areas can be found in a previous review article (Triarhou 2007b) and in the English edition of the Atlas (von Economo and Koskinas 2008).

The work of von Economo and Koskinas represents a gigantic intellectual and technical effort (van Bogaert and Théodoridès 1979). Their attempt to bring the

existing knowledge into a more orderly pattern was emphatically acknowledged by von Bonin (1950) and Bailey and von Bonin (1951).

Spyridon Dontas (1878–1958), Professor of Physiology and Pharmacology at the University of Athens and President of the Academy of Athens, had remarked in 1926 upon meeting Koskinas: “The work of von Economo and Koskinas is monumental and constitutes a milestone of science, charting new paths for understanding the brain from an anatomical, physiological and pathological viewpoint. It stands as the first comprehensive reference on the architecture of the adult human cerebrum and will persevere as a perpetual scientific testimony” (Triarhou 2012).

The brain map and the systematic area naming by von Economo and Koskinas have regrettably not passed into widespread general use. However, it is clear that they brought together concepts and ideas of cortical organization and structure that had been developing over the preceding 30 years and which remain with us in the present era of cortical research; moreover, they introduced original terms and, by applying in a systematic manner nomenclatures derived from other authors and themselves, they codified the language that we use to describe the cortex to this day, essentially providing the first “ontology” of the cerebral cortex (Jones 2010).

2.2 Method

At the outset of their studies, von Economo and Koskinas devised an entire system of new methods to overcome the existing obstacles and difficulties, from the autopsy to the photographic documentation (Koskinas 1926, 1931; von Economo 2009; von Economo and Koskinas 2008). The following are some of the introduced innovations.

2.2.1 Sectioning

Instead of the widely adopted method of sectioning the whole brain serially, perpendicular to its fronto-occipital axis, von Economo and Koskinas obtained tissue sections always perpendicular to the axis of each gyrus or sulcus and in directions corresponding to their convoluted pattern (Figs. 2.2 and 2.3). They arrived at that idea by considering that, in order to be able to compare the various brain areas cytoarchitectonically, sections had to have a consistent orientation relative to the gyral surface, insofar as only then could the breadth of the entire cerebral cortex and of each cortical layer as well be represented in the sections in a precise way.

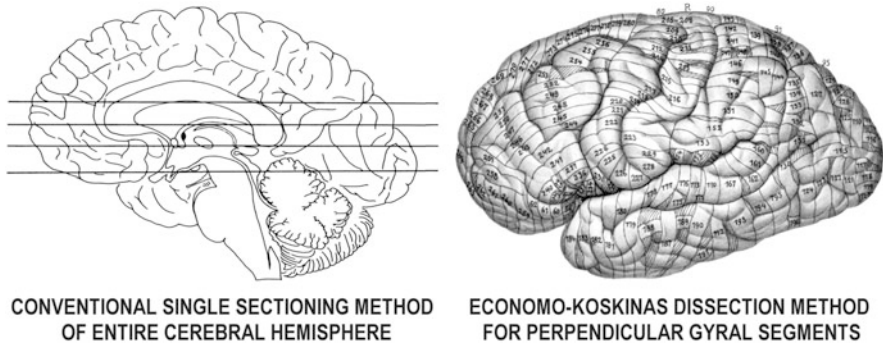


Fig. 2.2 The difference between the widely used method of obtaining whole single sections of the cerebral hemispheres, *left*, and the method devised by von Economo and Koskinas (1925, 2008) for dissecting each hemisphere into 250–350 tissue blocks, 4 mm in thickness, always perpendicular to the axis of each gyral or sulcal segment, *right*; hatched areas indicate “cancelled” tissue

2.2.2 Staining

The staining of the preparations was perfected such that a uniform tone was achieved not only of the single sections, but of all the series of sections into which each brain had been divided. That was mandated by the need, firstly, to define gradual differences of histological elements in neighboring areas of the cerebral cortex, and secondly, to achieve consistent photographic registrations.

2.2.3 Specimen Depiction

Most of the previous histological studies on cortical cytoarchitecture depicted their results schematically, and therefore subjectively. Instead of schematic drawings, and aiming at an exact documentation of the specimens, with all the relationships of the diverse neurons, von Economo and Koskinas used photography, which is the most objective testimony regarding form, size and arrangement, and turned to branches of science such as advanced optics and photochemistry.

The stained cortical sections were photographed using Carl Zeiss Planar lenses, which are special macro objectives with a considerably larger field than the common microscopy objectives, especially valuable for large area objects under relatively large magnifications. Planar lenses are used without an eyepiece. Additional details on technique can be found in my historical notes on Koskinas (Triarhou 2005) and von Economo (Triarhou 2006).

The depth of field that von Economo and Koskinas achieved in their photomicrographs, as well as the clarity and detail with which individual neurons can be visualized is remarkable. Their plates probably still represent the most comprehensive set of high resolution images of cortical histology ever assembled (Jones 2008).

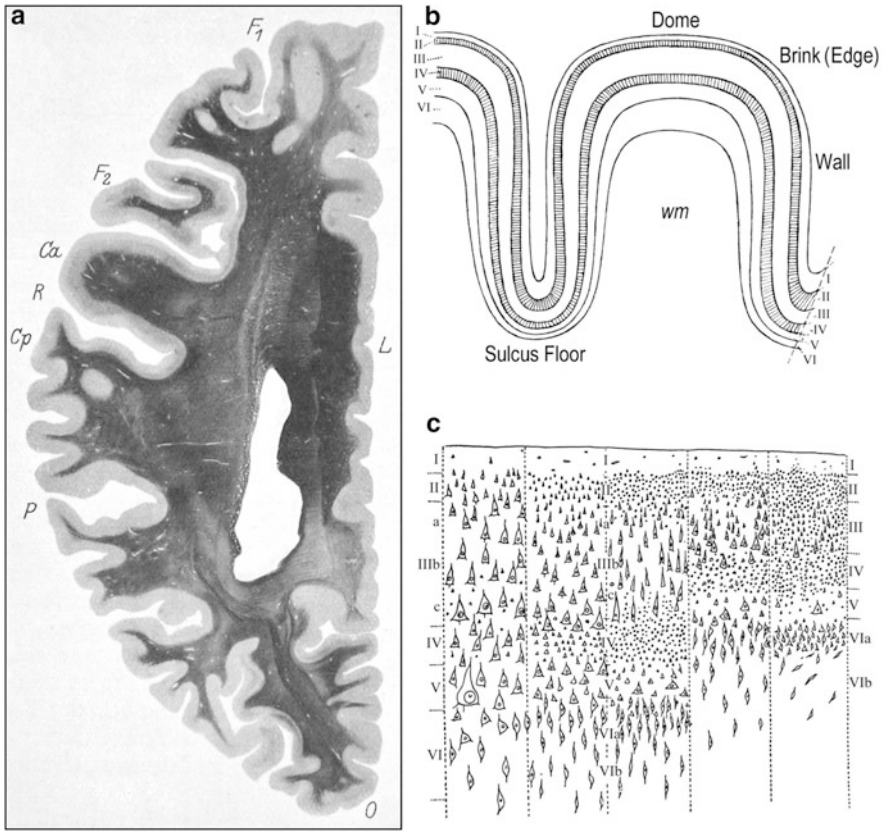


Fig. 2.3 (a) In obtaining sections of the entire cerebral hemisphere through conventional sectioning techniques, the real variations in layer thickness and cellular architecture cannot be studied consistently. The horizontal section through the left human cerebral hemisphere depicts such sizeable regional differences in cortical thickness and the random orientation of the gyri (von Economo and Koskinas 1925). Weigert method. F_1 and F_2 , superior and middle frontal gyrus; Ca , precentral gyrus; R , central sulcus; Cp , postcentral gyrus, P , parietal lobe; O , occipital lobe; L , limbic gyrus. (b) A schematic drawing that depicts the varying thickness of the six cortical layers (I through VI) at the level of the *dome*, *brink (edge)*, *wall* and *valley (sulcus floor)* in a cortical gyrus. The two granular layers (external and internal) are hatched; *wm*, subcortical white matter (von Economo 2009). (c) The five fundamental structural types of isocortex: 1, agranular; 2, frontal; 3, parietal; 4, polar; 5, granulous or *koniocortex* (von Economo 1925, 1929, 2009; von Economo and Koskinas 1925, 2008)

2.3 General Part

The “General Part” of the Text Volume (von Economo and Koskinas 1925) covers introductory concepts on the cerebral cortex and its nerve cells, the structure and the development of the cortical layers, the composition and the meaning of the cortical laminar structure, the definition of cortical areas, and methodological issues (Fig. 2.4).

Brodmann (1909) grouped his 44 human cortical areas as 4 postcentral, 2 precentral, 8 frontal, 4 parietal, 3 occipital, 10 temporal, 6 cingulate, 3 retrosplenial, and 4 hippocampal.

Von Economo and Koskinas (1925, 2008) divided the cortex into seven lobes, which they denoted by their initials. The lobes were further subdivided into regions: the frontal lobe (F) into prerolandic, anterior (prefrontal) and orbitomedial (orbitomedial) regions; the superior limbic lobe (L) into anterior, posterior and retrosplenial regions; the parietal lobe (P) into postcentral (anterior parietal), superior, inferior and basal regions; and the temporal lobe (T) into supratemporal, temporal proper, fusiform and temporopolar regions. The insular (I) and occipital (O) lobes were not subdivided. The inferior limbic lobe consists of the hippocampus (H). For cytoarchitectonic area designations, they did not continue Brodmann’s system of random numbers, but instead used letter codes, consisting of a Roman capital letter (the initial of the lobe), followed by a calligraphic capital to note the sequence of a gyrus within a lobe (e.g. FB means the second gyrus of the frontal lobe), and a Latin or Greek subscript for characteristic microscopic features (e.g. m = magnocellular, p = parvicellular, γ = gigantopyramidal).

Von Economo and Koskinas (1925, 2008) defined five fundamental “supercategories” of structural cortical types (agranular, frontal, parietal, polar and granulous) (Fig. 2.3c), further arranged into 54 *ground*, 76 *variant* and 107 cytoarchitectonic *modification* areas, plus more than 60 *transition* areas (von Economo 1925, 2009; von Economo and Horn 1930). Topographically, the 107 modification areas of von Economo and Koskinas are grouped into 35 frontal, 13 superior limbic, 6 insular, 18 parietal, 7 occipital, 14 temporal, and 14 inferior limbic or hippocampal (Figs. 2.5 and 2.6). Of the 107 modifications, 22 are allocortical, 22 heterotypic isocortical, and 63 homotypic isocortical. Von Economo and Koskinas (1925, 2008) separately analyzed the *dome*, *edge*, *wall* and *floor* of each cortical gyrus (Fig. 2.3b).

For certain cortical areas with a granular appearance of their cells in most layers, especially of gyral walls, associated primarily with sensory functions, von Economo and Koskinas (1923, 1925) introduced the term *koniocortex* to denote their dusty appearance.

Von Economo and Koskinas (1925, 2008) regularly saw a special type in a small band in sublayer IIIc at the boundary between any koniocortex (or sensory isocortex) and the ordinary surrounding isocortex in sensory parietal, occipital and temporal areas. Such zones contain giant pyramidal cells. They called these margin regions with magnocellular characteristics *parasensory zones*.

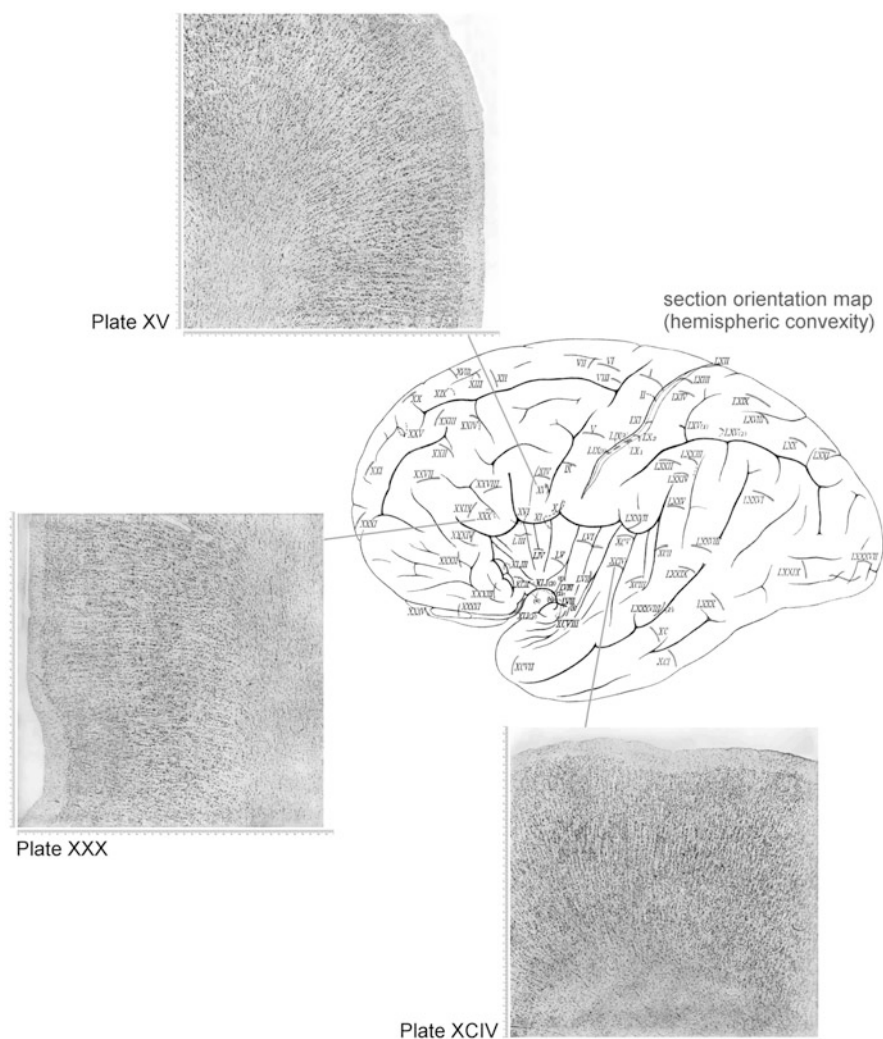


Fig. 2.4 Schematic map of the lateral (*convex*) facies of the hemispheric surface and three microphotographic plates from the Atlas of von Economo and Koskinas (2008), shown as examples: *Plate XV* – Magnocellular intermedio-agranular frontal area FCB_m (*Broca's area*) at the *foot* of the inferior frontal gyrus, anterior wall. *Plate XXX* – Triangular granular frontal area FD_7 in the inferior frontal gyrus, wall of the notch of pars triangularis (*incisura capii*). *Plate XCIV* – Supratemporal area granulosa TC in first gyrus of Heschl (primary auditory cortex), middle, dome, with the typical “rain shower formation” (*Regenschauerformation*). The detailed descriptions of the normal histological structure of the cerebral cortex depicted in the 112 microphotographic plates of the Atlas were explained in the accompanying Text Volume (von Economo and Koskinas 1925). The printing size of the original plates was 40×40 cm at a magnification of $\times 100$, therefore covering a 4.0×4.0 mm true cortical area

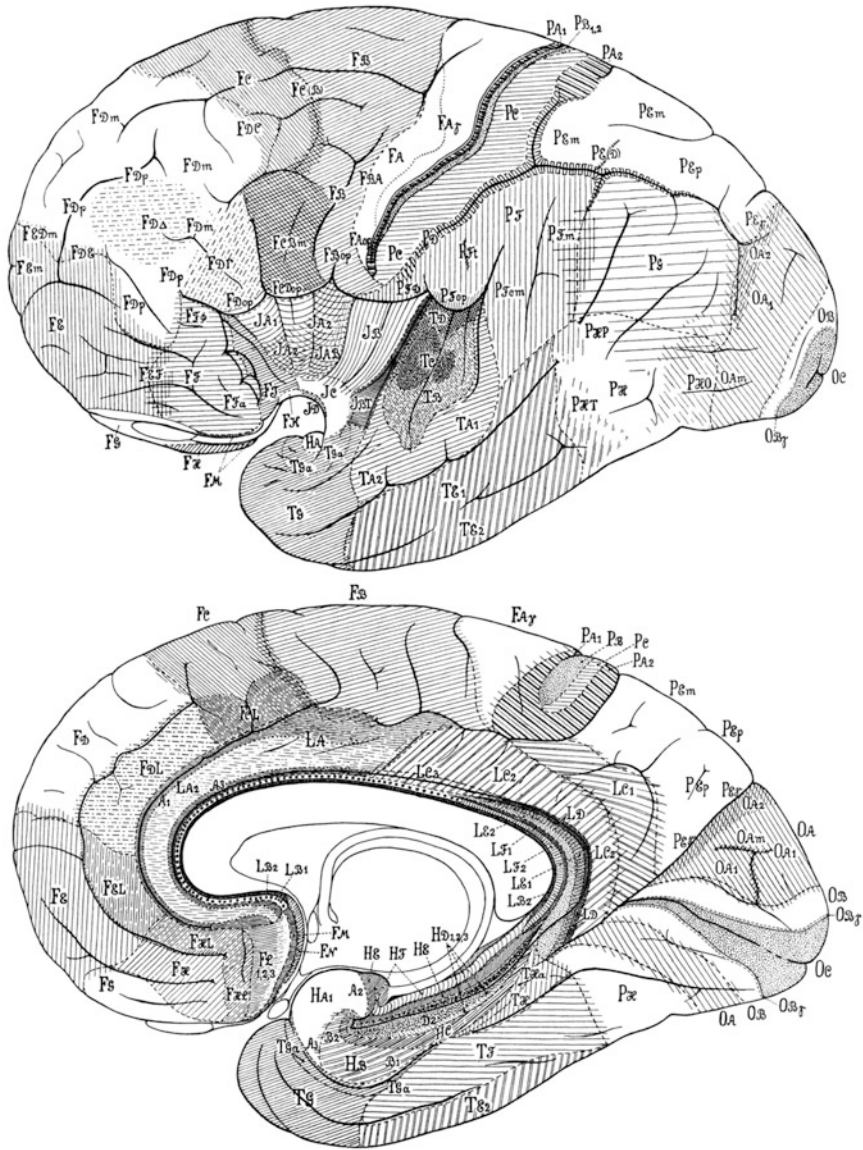


Fig. 2.5 Cytoarchitectonic maps of von Economo and Koskinas, showing cortical modification areas in the convex and median hemispheric facies of the human brain

Another crucial discovery was that of the large, spindle-shaped bipolar projection neurons in the inferior ganglionic layer (Vb) of the dome of the transverse insular gyrus, which are now called “von Economo neurons” (Watson et al. 2006) – although a more succinct term might be “von Economo-Koskinas neurons”. The

gyrus is characterized by a distinct type of cortex, distinguishable from the posteriorly lying premotor cortex in area *FB* in the precentral gyrus; it continues rostrally as area *FD_γ* (Fig. 2.4).

Anteriorly one finds portions of areas *FD* and *FE*, which are rich in granule cells. Lesions in the prefrontal region result in disturbances of attention, psychomotor activity, will and emotivity. Von Economo (2009) termed such higher mental functions, localized in the frontal regions of the brain, “the active part of the psychic personality”. Area *FA_γ* resembles the frontal core area more closely, with the consequence that a large part of area *FA* belongs to nonprimary motor cortex.

Area *FF* partly corresponds to the orbitofrontal proisocortex of the monkey that lies intercalated between the caudal orbitofrontal isocortex rostrally, and the orbitofrontal peripaleocortex caudally. Area *FF_a* in the human brain probably corresponds to the granular isocortex in the anterior part of the orbital surface of the frontal lobe in the macaque. Areas *FH* and *FHL* correspond to the paralimbic dysgranular isocortex on the ventromedial surface of the prefrontal cortex in the macaque, which lies intercalated between the frontopolar granular isocortex rostrally and the orbitomesial archicortical proisocortex of the straight gyrus caudally. Area *FJ* appears to correspond to peripaleocortex in the inferior part of the transverse gyrus of the insula, and to the orbitofrontal peripaleocortex in the monkey (de Olmos 1990). The area *FF* lies rostrally and ventrally to area *FD_γ*.

Von Economo and Koskinas (1925) mark transitional types of cortex in their maps, beyond the 107 “standard” modifications; such transitions comprise the areas *FBA*, *FC(B)*, *FCD_{op}*, *FDC*, *FDE*, *FED_m*, *FEF* and *FE_m*. Areas *FBA*, *FDC*, *FDE* and *FEF* denote transition forms (e.g. *FBA* marks the transition of area *FB* into *FA*, *FDC* the transition of *FD* into *FC*, and so on). The designation *FC(B)* implies a part of area *FC* with an admixture of the type of the neighboring area *FB*, whereas the subscript *m* in the areas *FED_m* and *FE_m* signifies cellular variations with magnocellular features. Area *FCD_{op}* is a transitional opercular variant between areas *FC_{op}* and *FD_{op}*.

2.4.2 Parietal Lobe

Brodmann (1909) defined four areas (1, 2, 3, 43) in the postcentral region, whereas von Economo and Koskinas six (*PA₁*, *PA₂*, *PB₁*, *PB₂*, *PC* and *PD*). In the parietal region, Brodmann defined four areas (5, 7, 39, 40), and von Economo and Koskinas nine (*PED*, *PE_m*, *PE_p*, *PE_γ*, *PF*, *PF_t*, *PF_{op}*, *PF_{cm}* and *PG*). The basal parietal region *PH* most likely belongs to the visual cortex and includes the functionally defined areas *V4* and *V5* (Zilles and Palomero-Gallagher 2001). The proposed subdivisions of the anterior parietal cortex by von Economo and Koskinas are still in use.

Area *PA* is located in the depths of the central sulcus. Area *PB* is “sensory koniocortex”, located on the caudal bank of the central sulcus. Concerning the primary somatosensory cortical areas and the subdivision of the posterior parietal lobe into a superior and an inferior lobule, the accepted terminology of von

Economo and Koskinas forms the basis for modern cytoarchitectonic analyses and experiments in primates (Zilles 2004). Brodmann did not delineate any transition zones in the posterior parietal lobe, whereas von Economo and Koskinas marked such transition zones between the areas *PE*, *PF*, *PG*, *PH* and *OA*, in agreement with the observations of Eidelberg and Galaburda (1984).

Beyond the standard modifications, transition parietal areas are *PC_γ*, *PE(D)*, *PFD* and *PF_m*. Areas *PC_γ* and *PF_m* denote cellular variations containing giant pyramidal and magnocellular neurons, respectively. Area *PE(D)* is a variant of area *PE* with an admixture of the neighboring cortical type *PD*. The functionally defined secondary somatosensory cortex (SII) is located in the parietal operculum, hidden within the Sylvian fissure. Brodmann areas 40 and 43 extend into the parietal operculum and are candidates for SII on topographic grounds; they partially correspond to the opercular modification *PF_{op}* and to the subcentral area *PFD*, respectively. In the supramarginal gyrus of the rostral inferior parietal cortex, von Economo and Koskinas subdivide Brodmann area 40 into the five areas *PF*, *PF_{cm}*, *PF_m*, *PF_{op}* and *PF_t*, confirmed in general lines by Caspers et al. (2006). In the caudal inferior parietal cortex, Caspers et al. (2006) distinguish a caudal region termed *PGp* and a rostral region termed *PGa*, this latter fitting to area *PG* in the angular gyrus (roughly Brodmann area 39).

2.4.3 Temporal Lobe and Insula

Based on pathological and physiological considerations, von Economo (1927, 2009) localized the understanding of word *speech* in area *TA₁* of the left hemisphere, the understanding of word *sense* in the caudal transitional region of area *TA₁* towards area *PF*, and the understanding of *music* in area *TA₂* and the temporal pole; the appreciation of higher tones in parts in the bottom of the Sylvian fissure, while that of lower tones more towards outer portions. Area *TC* is koniocortex, i.e. sensory cortex representing *primary audition*, and receiving fibers from the medial geniculate body.

Von Economo and Horn (1930) investigated the cytoarchitectonics of the auditory cortex further in the adult and juvenile human brain. They found the superior temporal surface and the length of the Sylvian fissure larger on the left side. Initial attempts at investigating the cytoarchitectonics of the auditory cortex by Campbell (1905), Rosenberg (1907) and Brodmann (1909), who had identified it with Brodmann area 41, had missed the most characteristic feature that this area shares with all other “sensory” cortices, i.e. the “granularity” (Meyer 1977); that was first described by von Economo and Koskinas (1925). Von Economo and Horn (1930) attribute the striking variations in size among individuals and between the two hemispheres possibly to handedness or differences in musicality.

The koniocortex of the human temporal lobe encompasses areas *TC* and *TD* and is located on Heschl’s gyrus (transverse temporal gyrus); area *TA* contains Wernicke’s speech area, while the cerebral “belt” areas most likely correspond to

areas TA and TB (Chiry et al. 2003; Webster and Garey 1990). Within the area TC, which closely corresponds to the “core” region of Hackett et al. (2001), von Economo and Horn (1930) describe 11 distinct types of granular cortex. The “belt” field of the human auditory cortex, on the other hand, seems to correspond to the medial portion of the koniocortical TD sector of von Economo and Koskinas (1925).

In sections cut perpendicularly to the radial orientation of layer III apical dendrites, the small pyramidal cells are arranged in short radial columns that partially extend into layers II and IV (Hackett et al. 2001); such a feature seems to correspond to what von Economo and Koskinas called the “rain shower formation” (Fig. 2.4). With regard to the columnar organization of the belt region, layer III pyramidal cells are arranged in organized vertical columns, which von Economo and Koskinas called the “organ pipe formation”.

Von Economo and Koskinas (1925) and von Economo and Horn (1930) were among the first investigators to notice individual differences of the auditory fields and marked asymmetries between the two hemispheres: Heschl’s gyrus is generally single and longer on the left side and double and shorter on the right side; the *planum temporale* (located caudally to Heschl’s gyrus, in area TB) is larger on the left side (Webster and Garey 1990). Such asymmetries may underscore the modern idea of a functional differentiation of the two cerebral hemispheres and the predilection of the left hemisphere (right ear) for verbal tests, and that of the right hemisphere (left ear) for music recognition (Brodal 1981).

In contrast to Brodmann, von Economo and Koskinas divide the medial temporal lobe into a rostral area TG and two caudal areas, TH and TF, with area TG further subdivided into a medial area TG_α and a larger lateral area TG (Suzuki and Amaral 2003). Like Elliot Smith (1907), von Economo and Koskinas also illustrate the temporal polar cortex as being continuous with the anteroventral portion of the medial temporal lobe. The nomenclature and cortical demarcations of Brodmann (1909) regarding the medial temporal lobe in primates is somewhat vague and varying across species, whereas the analyses of von Economo and Koskinas are more detailed (Suzuki and Amaral 2003). Areas TF and TH belong to the posterior part of the parahippocampal gyrus; the anterior part of the parahippocampal gyrus comprises mainly the entorhinal cortex and the associated perirhinal cortex (Amaral and Insausti 1990). Area TJ seems to be homologous to the hyperchromic, coarse-cell temporopolar peripaleocortex in the macaque (de Olmos 1990). Besides area TJ the peripaleocortical agranular claustral region (Brodmann area 16 in the *Cercopithecus*) is also homologous to a certain extent to the human area ID (Zilles 2004).

The insula includes areas IA₁, IA₂, IB, IC and ID. The gradual transition of area IA backwards over the central sulcus of the insula to area IB is denoted by von Economo and Koskinas as area IAB, which is characterized by a condensation of the granular layers and a reduction of pyramidal cell size.

2.4.4 Occipital Lobe

The primary visual area or striate cortex is area OC, the parastriate cortex is area OB, and the peristriate cortex is area OA. A borderzone at the boundaries of Brodmann areas 17 and 18, containing giant pyramidal cells in the lower part of layer III, is area OB_γ (*limes parastriatus gigantopyramidalis*). The total surface of koniocortex in the visual sensory sphere (area OC) in both hemispheres was estimated at about 50 cm² and the total number of cells at about 1.4×10^9 , i.e. 10 % of the total number of neurons of the entire cerebral cortex. Thus, the area striata appears four times richer in cells than any other cortical region (Koskinas 1969; von Economo 1927; von Economo and Koskinas 2008).

2.4.5 Superior Limbic and Inferior Limbic (Hippocampal) Gyrus

One concern in the localization of functions in the human cerebral hemispheres is the boundary between the retrosplenial/cingulate and the parahippocampal cortices. Brodmann (1909) depicted the retrosplenial cortex as fully surrounding the posterior and ventral edge of the splenium of the corpus callosum. Von Economo (1927, 2009) provided the first subregional map of the posterior cingulate gyrus and showed a termination of the retrosplenial areas LE and LD at a plane caudal but not ventral to the splenium (Vogt et al. 2001).

Every section through the retrosplenial cortex includes a segment of allocortical hippocampus and ectosplenial area LF. At allocortical-isocortical transition points in the primate telencephalon, modern anatomists recognize the concept of a “dysgranular” cytoarchitecture (a weakly defined layer IV); such points are found in orbitofrontal, insular, and anterior and posterior cingulate cortices (Vogt et al. 2001). Ngowyang (1934) had described a “dysgranular region” in the frontal lobe, associated with areas FC and FCL. Going forward, the granular layer appears sporadically, making this area “hypogranular” or “dysgranular”; forward of Brodmann area 6, the prefrontal cortex, and continuing through the frontal pole, the cortex is “eugranular” (DeMyer 1988).

The area LD is dysgranular rather than agranular, as it was originally thought (Vogt et al. 2001); its layer IV has a variable thickness, interrupted by large SMI-32 immunopositive neurons in the sublayers IIIc and Va. Brodmann (1909) referred to area 30 as agranular. Von Economo (1927, 2009) was quite explicit that area LD is not merely agranular, but that the “granulous” layer of area LE is not continuous with the isocortical layer of area LC₂. Von Economo vacillated on the presence of a layer IV in area LD and showed a layer III(IV) below layer III. A dysgranular layer IV has a variable thickness and may even disappear as the neurons of the sublayers IIIc and Va intermingle. The dysgranular concept for a cortical architecture was obviously not defined during the early years of cortical cytoarchitectonics in terms

of the chemical signature of neurons, since histochemical methods were not available. In a series of studies spanning over 30 years, Vogt et al. (2001) have described in the primate brain the dysgranular nature of area *LD* and its profound differences with the cytoarchitecture of the granular Brodmann area 23a.

The inferior limbic lobe comprises the hippocampal gyrus from the isthmus until near the temporal pole and contains the entire uncinate gyrus, the subiculum, the dentate gyrus and Ammon's horn. Above the splenium, the hippocampal rudiment, the indusium griseum, or areas *LB*₂ and *HF*, there is a single layer of densely packed SMI-32 (nonphosphorylated neurofilament) immunopositive neurons. Adjacent to the indusium griseum is the subicular rudiment or area *HE*, which has fewer and more dispersed neurons. These two areas together form the fasciolate gyrus on the dorsal surface of the corpus callosum (Vogt et al. 2001).

2.5 Discussion

Brodmann maps are commonly used to either designate cytoarchitectonic areas as such, or as a “shorthand system” to designate some region on the cerebral *surface* (DeMyer 1988). Macroscopic extrapolation of Brodmann projection maps are effected on the atlas of Talairach and Tournoux (1988), rather than being based on real microscopic cytoarchitectonics. Such specifications of Brodmann areas may lead to erroneous results in delineating cortical regions, something that may in turn lead to erroneous hypotheses regarding the involvement of specific brain systems in normal or pathological situations (Uylings et al. 2005).

Von Economo (1927, 2009) was the first to use subregional maps, which are invaluable in resolving difficult topological problems (Fig. 2.7). Talairach and Tournoux (1988) emphasize the shortcoming of Brodmann's reconstruction technique in not distinguishing areas on the gyral surfaces from areas in the sulcal depths, something may lead to miscalculations of the depth of the callosal sulcus and related areas, and placing e.g. Brodmann areas 29 and 30 on gyral surfaces. Because the architecture of each cortical area cannot yet be determined by the current imaging modalities, it is imperative that standardized atlases seeking to localize specific areas rely heavily on neuroanatomical observations, rather than Brodmann's reconstructions onto the convoluted human brain surface (Vogt et al. 2001).

On the other hand, the *perpendicular* sectioning method of von Economo and Koskinas (1925, 2008), which was consistently used to analyze the dome, wall and floor of each cortical gyrus, practically solves the generalized mapmaker's problem of flattening nonconvex polyhedral surfaces (Schwartz et al. 1989), which also constitutes a core problem in cortical research.

Microscopically-defined borders usually differ from gross anatomical landmarks; cytoarchitectonics reflect the inner organization of cortical areas and their morphofunctional correlates (Zilles 2004). Despite the integration of multifactorial descriptors such as chemoarchitecture, angioarchitecture, neurotransmitter,

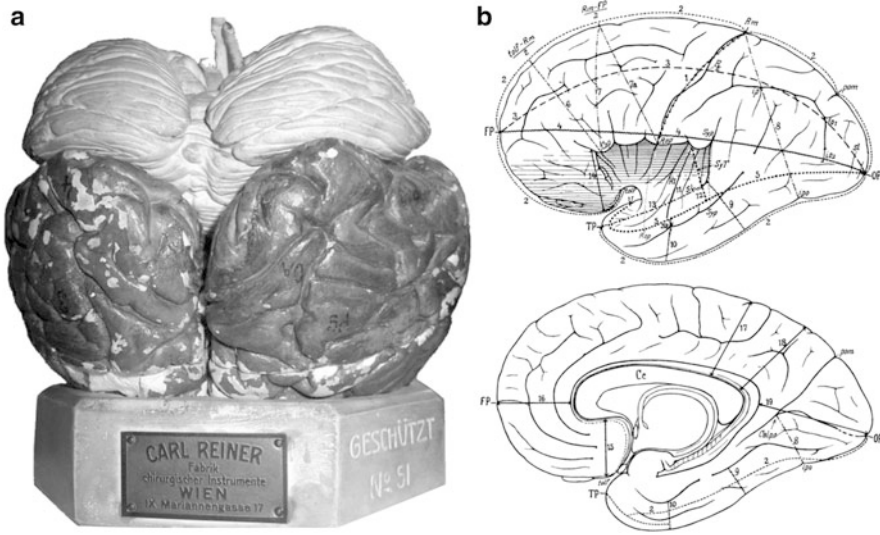


Fig. 2.7 (a) A plaster model of the human brain made in the 1920s, with cytoarchitectonics marked according to the system of von Economo and Koskinas (1925, 2008), used by von Economo (2009) for his lectures (courtesy of Fabrikation Chirurgischer Instrumente Carl Reiner GmbH, Vienna). (b) Schematic drawing of 26 encephalometric constants in the lateral and medial cerebral hemispheric facies, suggested by von Economo (1929) on the basis of macroscopic and cytoarchitectonic criteria as reference points, for future studies to determine variations among individuals, gender and talent differences, and alterations associated with nervous and mental diseases

receptor and gene expression patterns, as well as white matter tracts, it is clear that the knowledge of the classical anatomy remains fundamental (Toga and Thompson 2007). The structure of the cerebral cortical layers incorporates, and reflects, the form of their constitutive cells and functional connections; the underpinnings of neuronal connectivity at the microscopic level are paramount to interpreting any macroscopic clue yielded by neuroimaging studies.

The century-long endurance of the cytoarchitectonic analyses of Brodmann (1909) and of von Economo and Koskinas (1925) is in part due to the fact that these brain scientists did not hypothesize much about function; their only supposition was that anatomical subdivisions reflect functional variations, and that future functional and clinical studies would validate their anatomical subdivisions. In fact, there are examples of such cytoarchitectonic subdivisions in the motor, parietal and striate cortex that reflect functional differentiation to an unexpected degree (Bartels and Zeki 2005).

In a similar line of reasoning, Koskinas (1926) argued: “The mind has its organic locus, its seat, its altar in the cerebral cortex. That is why one may be justified in claiming that the anatomical and the physiological exploration of that noblest of the organs deserves the utmost attention of science.” And later wrote: “Provided that, as

a general principle, each physiological function presupposes a corresponding anatomical basis, one understands how important the study of brain structure becomes. From a precise knowledge of the structure of the cerebral cortex, we may expect to shed light upon issues of the utmost importance, such as the anatomical basis of mental phenomena and the relationship between certain attributes and brain structure. But can we not hypothesize that the limitations of anatomically tracing deficits of the mind is simply a matter of the sophistication of our methods and the acuity of our foresight?" (Koskinas 1931).

The underlying concept is that cytoarchitectonic differences indicate functional differences (the "neural hardware" that includes cell types, connectivity, synaptic interactions and molecular events) and that functional differences necessitate cytoarchitectonic differences; by being "blind" with respect to function, the cytoarchitectonics approach ensures a degree of objectivity and data longevity, since observers document mere facts (Bartels and Zeki 2005).

Modern "probabilistic" atlases of the human brain bridge high-resolution *in vivo* data with neurocytology, and spatially normalize them to a common reference space; thus, they provide the means for moving from a descriptive to a hypothesis-driven science (Mazziotta et al. 1995). Nonetheless, in hypothesis-driven neuroimaging research, the interpretation of findings may vary depending on the specific paradigm, and attributing a function to a given area rarely goes unchallenged (Bartels and Zeki 2005).

In the fad of "cognitive brain mapping" and its purported representations in the human brain, color images generated by software can be adjusted to denote so-called "activations" with much ambiguity, and occasionally lead to fallacious findings unworthy of attempted replication. "Functional segregation", i.e. the common notion that mental functions are localized in cell clusters at specific cortical sites, is based on the old, hard-dying conception that a particular conscious process must have a delineated seat in the brain (Smith 2010), as "modern phrenologists, equipped with the powerful tools of functional MRI, seek to relate tiny pseudo-colored patches of slightly enhanced cortical activity associated with some limited cognitive function to an underlying structural correlate" (Jones 2008).

Functional MRI, as one technique that allows a correlation between structure and function, has limitations insofar as the measurements are not in real time and the spatial resolution only recently reached the mm level. Even the hypothetical development of a technique, which would noninvasively image neural activity at a spatial resolution of 1 mm and a temporal resolution of 1 msec, would still appear coarse relative to the size of the neuronal soma (5–100 μm) or the synaptic gap (20–40 nm) (Hougan and Altevogt 2008).

A key element in defining cortical areas is connectivity, and the guiding principle of neurohistologists that cortical areas form parts of connectional networks is now being adopted by the neuroimaging community; besides the streams of intrinsic cortico-cortical connections, no cortical area is without re-entrant projections from the thalamus, while each cortical area is undoubtedly governed, like the thalamocortical connections, by ontogenetic mechanisms (Jones 2008).

Particular emphasis on the U-shaped fibers of the frontal lobe and its connections with subcortical nuclei of the thalamus and the medial temporal lobe was placed by Christfried Jakob in his hodological approach of the early 1900s (Théodoridou and Triarhou 2012). Those pathways are currently emphasized in imaging studies (Catani et al. 2012). Jakob had identified all the major tracts of the limbic circuitry early on, preceding James W. Papez (1883–1958) by almost three decades (Triarhou 2008, 2009). Bearing a direct relevance to the clinic, Jakob's network approach provided a prescient anatomical framework for the concept of “diaschisis” – as elaborated by Constantin von Monakow (1853–1930) in 1914 to highlight the possible recovery of dysfunctional distant regions connected to destroyed areas – and for what would eventually become an intense area of research on the neural underpinnings of memory, emotion and behavioral disorders associated with frontal lobe damage (Catani and Stuss 2012).

As the necessity emerges to move from brain localization to connectivity imaging, methods such as high-resolution two-photon imaging are used to visualize functionally-defined afferent inputs on cortical dendritic spines in vivo with single-synapse resolution (Chen et al. 2011), and the relationship between structure and function in cortical synaptic circuits is studied by combining in vivo physiology with network anatomy. For example, a functional property of specific cortical neurons can be characterized by two-photon calcium imaging and a portion of these neurons' local interconnections can be traced with large-scale electron microscopy of serial thin sections (Bock et al. 2011). Thus, it is becoming possible to address hitherto intractable neurobiological questions through the technological advances that permit the combination of functional imaging and neuronal wiring (Briggman et al. 2011) through a high-speed reconstruction of neurite connectivity while performing reliable analyses of large neuroanatomical datasets (Helmstaedter et al. 2011).

The novel approaches for analyzing brain imaging data aim at providing levels of specificity with narrower confidence intervals in determining the dynamics of local neural population responses to their native temporal resolution (Tyler and Likova 2011). Furthermore, to better understand the anatomical organization of structures that form the basis of cognitive information processing, morphological data may be distilled and synthesized into a single interactive visualization that represents a fundamental blueprint upon which cognitive functions must be implemented (Solari and Stoner 2011). In such a framework, functional circuits corresponding to memory, cognition and cortical information flow are described in terms of distinguishable neuronal groups and cortical systems in order to elucidate the basis of distinct homotypical cognitive architecture in multiple independent visualizations that constitute an annotated view of “neuroanatomical consilience” (Solari and Stoner 2011).

Acknowledgments The author gratefully acknowledges the support of Karger Publishers, the Bodossakis Foundation, the Academy of Athens, the Hellenic Ministry of National Education, the Hellenic Neurological Society, and the University of Macedonia in his effort to revive the neuroanatomical works of von Economo and Koskinas, as well as the invaluable encouragement by the family members of the two eminent scientists.

References

- Amaral DG, Insausti R (1990) Hippocampal formation. In: Paxinos G (ed) *The human nervous system*. Academic, San Diego, pp 711–755
- Bailey P, von Bonin G (1951) *The isocortex of man*. University of Illinois Press, Urbana
- Bartels A, Zeki S (2005) The chronoarchitecture of the cerebral cortex. *Philos Trans R Soc Lond [Biol Sci]* 360:733–750
- Bock DD, Allen Lee W-C, Kerlin AM, Andermann ML, Hood G, Wetzel AW, Yurgenson S, Soucy ER, Kim HS, Reid RC (2011) Network anatomy and in vivo physiology of visual cortical neurons. *Nature* 471:177–182
- Briggman KL, Helmstaedter M, Denk W (2011) Wiring specificity in the direction-selectivity circuit of the retina. *Nature* 471:183–188
- Brodal A (1981) *Neurological anatomy in relation to clinical medicine*. Oxford University Press, Oxford
- Brodmann K (1909) *Vergleichende Lokalisationslehre der Großhirnrinde*. J.A. Barth, Leipzig
- Campbell AW (1905) *Histological studies on the localization of cerebral function*. Cambridge University Press, Cambridge
- Caspers S, Geyer S, Schleicher A, Mohlberg H, Amunts K, Zilles K (2006) The human inferior parietal cortex: cytoarchitectonic parcellation and interindividual variability. *Neuroimage* 33:430–448
- Catani M, Stuss DR (2012) At the forefront of clinical neuroscience. *Cortex* 48:1–6
- Catani M, Dell’Acqua F, Vergani F, Malik F, Hodge H, Roy P, Valabregue R, Thiebaut de Schotten M (2012) Short frontal lobe connections of the human brain. *Cortex* 48:273–291
- Chen X, Leischner U, Rochefort NL, Nelken I, Konnerth A (2011) Functional mapping of single spines in cortical neurons in vivo. *Nature* 475:501–505
- Chiry O, Tardif E, Magistretti PJ, Clarke S (2003) Patterns of calcium-binding proteins support parallel and hierarchical organization of human auditory areas. *Eur J Neurosci* 17:397–410
- de Olmos J (1990) Amygdaloid nuclear gray complex. In: Paxinos G (ed) *The human nervous system*. Academic, San Diego, pp 583–710
- DeMyer W (1988) *Neuroanatomy*. Harwal Publishing, Malvern
- Eidelberg D, Galaburda AM (1984) Inferior parietal lobule: divergent architectonic asymmetries in the human brain. *Arch Neurol* 41:843–852
- Elliot Smith G (1907) A new topographical survey of the human cerebral cortex, being an account of the distribution of the anatomically distinct cortical areas and their relationship to the cerebral sulci. *J Anat Physiol (Lond)* 41:237–254
- Garey LJ (2006) *Brodmann’s localisation in the cerebral cortex*. Springer, New York
- Hackett TA, Preuss TM, Kaas JH (2001) Architectonic identification of the core region in auditory cortex of macaques, chimpanzees, and humans. *J Comp Neurol* 441:197–222
- Helmstaedter M, Briggman KL, Denk W (2011) High-accuracy neurite reconstruction for high-throughput neuroanatomy. *Nat Neurosci* 14:1081–1088
- Hougan M, Altevogt B (2008) From molecules to minds—challenges for the 21st century: workshop summary. National Academies, Washington, DC
- Jakob C (1939) *Folia neurobiológica Argentina, Atlas I: El cerebro humano—su anatomía sistemática y topográfica*. Aniceto López Editor, Buenos Aires
- Jakob C (1941) *Folia neurobiológica Argentina, Tomo I: neurobiología general*. Aniceto López Editor, Buenos Aires
- Jones EG (2008) Cortical maps and modern phrenology. *Brain* 131:2227–2233
- Jones EG (2010) Cellular structure of the human cerebral cortex. *Brain* 133:945–946
- Koskinas GN (1926) Cytoarchitectonics of the human cerebral cortex. *Proc Athens Med Soc* 92:44–48
- Koskinas GN (1931) *Scientific works published in German*. Pyrsus, Athens
- Koskinas GN (1969) *Lobus occipitalis: makroskopische und mikroskopische Beschreibung*. Privately Published, Athens

- Mazziotta JC, Toga AW, Evans AC, Fox PT, Lancaster JL (1995) Digital brain atlases. *Trends Neurosci* 18:210–211
- Meyer A (1977) The search for a morphological substrate in the brains of eminent persons including musicians: a historical review. In: Critchley M, Henson RA (eds) *Music and the brain: studies in the neurology of music*. William Heinemann, London, pp 255–281
- Ngowyang G (1934) *Die Cytoarchitektonik des menschlichen Stirnhirns I. Cytoarchitektonische Felderung der Regio granularis und Regio dysgranularis*. Monogr Natl Res Inst Psychol Acad Sin (Shanghai) 7:1–68
- Pandya DN, Sanides F (1973) Architectonic parcellation of the temporal operculum in rhesus monkey and its projection pattern. *Z Anat Entwickl-Geschichte* 139:127–161
- Rosenberg L (1907) Histologische Untersuchung über die Cytoarchitektonik der Heschl'schen Windungen. *Neurol Cbl* 14:685–686
- Sanides F (1962) *Die Architektonik des menschlichen Stirnhirns*. Springer, Berlin/Göttingen/Heidelberg
- Sanides F (1964) The cyto-myeloarchitecture of the human frontal lobe and its relation to phylogenetic differentiation of the cerebral cortex. *J Hirnforsch* 47:269–282
- Schwartz EL, Shaw A, Wolfson E (1989) A numerical solution to the generalized mapmaker's problem: flattening nonconvex polyhedral surfaces. *IEEE Trans Pattern Anal Mach Intell* 11:1005–1008
- Smith DF (2010) Cognitive brain mapping for better or worse. *Perspect Biol Med* 53:321–329
- Solari SVH, Stoner R (2011) Cognitive consilience: primate non-primary neuroanatomical circuits underlying cognition. *Front Neuroanat* 5:1–23. doi:[10.3389/fnana.2011.00065](https://doi.org/10.3389/fnana.2011.00065) (article 65)
- Suzuki WA, Amaral DG (2003) Where are the perirhinal and parahippocampal cortices? A historical overview of the nomenclature and boundaries applied to the primate medial temporal lobe. *Neuroscience* 120:893–906
- Talairach J, Tournoux P (1988) *Co-planar stereotaxic atlas of the human brain. 3-dimensional proportional system: an approach to cerebral imaging* (trans: Rayport M). G. Thieme Verlag, Stuttgart
- Théodoridou ZD, Triarhou LC (2012) Challenging the supremacy of the frontal lobe: early views (1906–1909) of Christfried Jakob on the human cerebral cortex. *Cortex* 48:15–25
- Toga AW, Thompson PM (2007) What is where and why it is important. *Neuroimage* 37:1045–1049
- Triarhou LC (2005) Georg N. Koskinas (1885–1975) and his scientific contributions to the normal and pathological anatomy of the human brain. *Brain Res Bull* 68:121–139
- Triarhou LC (2006) The signalling contributions of Constantin von Economo to basic, clinical and evolutionary neuroscience. *Brain Res Bull* 69:223–243
- Triarhou LC (2007a) The Economo-Koskinas atlas revisited: cytoarchitectonics and functional context. *Stereotact Funct Neurosurg* 85:195–203
- Triarhou LC (2007b) A proposed number system for the 107 cortical areas of Economo and Koskinas, and Brodmann area correlations. *Stereot Funct Neurosurg* 85:204–215
- Triarhou LC (2008) Centenary of Christfried Jakob's discovery of the visceral brain: an unheeded precedence in affective neuroscience. *Neurosci Biobehav Rev* 32:984–1000
- Triarhou LC (2009) Tripartite concepts of mind and brain, with special emphasis on the neuroevolutionary postulates of Christfried Jakob and Paul MacLean. In: Weingarten SP, Penat HO (eds) *Cognitive psychology research developments*. Nova, Hauppauge, pp 183–208
- Triarhou LC (2010) Revisiting Christfried Jakob's concept of the dual onto-phylogenetic origin and ubiquitous function of the cerebral cortex: a century of progress. *Brain Struct Funct* 214:319–338
- Triarhou LC (2012) Cytoarchitectonics of the human cerebral cortex: the 1926 presentation by Georg N. Koskinas (1885–1975) to the Athens Medical Society. In: Bright P (ed) *Neuroimaging—cognitive and clinical neuroscience*. InTech Publishers, Rijeka/Vienna, pp 1–16

- Triarhou LC, del Cerro M (2006) Semicentennial tribute to the ingenious neurobiologist Christfried Jakob (1866–1956)—2. Publications from the second Argentina period, 1913–1949. *Eur Neurol* 56:189–198
- Tyler CW, Likova LT (2011) Estimating neural signal dynamics in the human brain. *Front Syst Neurosci* 5:1–17. doi:[10.3389/fnsys.2011.00033](https://doi.org/10.3389/fnsys.2011.00033) (article 33)
- Uylings HBM, Rajkowska G, Sanz-Arigita E, Amunts K, Zilles K (2005) Consequences of large interindividual variability for human brain atlases: converging macroscopical imaging and microscopical neuroanatomy. *Anat Embryol* 210:423–431
- van Bogaert L, Théodoridès J (1979) Constantin von Economo: the man and the scientist. Verlag der Österreichischen Akademie der Wissenschaften, Vienna
- Vogt O (1927) Architektonik der menschlichen Hirnrinde. *Zbl Gesamte Neurol Psychiatrie* 45:510–512
- Vogt C, Vogt O (1919) Allgemeinere Ergebnisse unserer Hirnforschung. *J Psychol Neurol (Leipz)* 25:279–461
- Vogt BA, Vogt LJ, Perl DP, Hof PR (2001) Cytology of human caudomedial cingulate, retrosplenial, and caudal parahippocampal cortices. *J Comp Neurol* 438:353–376
- von Bonin G (1950) Essay on the cerebral cortex. Charles C. Thomas, Springfield
- von Economo C (1925) Die fünf Bautypen der Grosshirnrinde. *Schweiz Arch Neurol Psychiatrie* 16:260–269
- von Economo C (1927) Zellaufbau der Grosshirnrinde des Menschen: Zehn Vorlesungen. Julius Springer, Berlin
- von Economo C (1929) Wie sollen wir Elitegehirne verarbeiten? *Z Gesamte Neurol Psychiatrie* 121:323–409
- von Economo C (2009) Cellular structure of the human cerebral cortex (trans, ed: Triarhou LC). Karger, Basel
- von Economo C, Horn L (1930) Über Windungsrelief, Maße und Rindenarchitektonik der Supratemporalfläche, ihre individuellen und ihre Seitenunterschiede. *Z Gesamte Neurol Psychiatrie* 130:678–757
- von Economo C, Koskinas GN (1923) Die sensiblen Zonen des Großhirns. *Klin Wochenschr* 2:905
- von Economo C, Koskinas GN (1925) Die Cytoarchitektonik der Hirnrinde des Erwachsenen Menschen: Textband und Atlas mit 112 Mikrophotographischen Tafeln. Springer, Vienna
- von Economo C, Koskinas GN (2008) Atlas of cytoarchitectonics of the adult human cerebral cortex (trans, rev, ed: Triarhou LC). Karger, Basel
- Watson KK, Jones TK, Allman JM (2006) Dendritic architecture of the von Economo neurons. *Neuroscience* 141:1107–1112
- Webster WR, Garey LJ (1990) Auditory system. In: Paxinos G (ed) *The human nervous system*. Academic, San Diego, pp 889–944
- Zilles K (2004) Architecture of the human cerebral cortex: regional and laminar organization. In: Paxinos G, Mai JK (eds) *The human nervous system*, 2nd edn. Elsevier/Academic, Amsterdam/London, pp 997–1055
- Zilles K, Amunts K (2010) Centenary of Brodmann's map: conception and fate. *Nat Rev Neurosci* 11:139–145
- Zilles K, Amunts K (2012) Architecture of the cerebral cortex. In: Mai JK, Paxinos G (eds) *The human nervous system*, 3rd edn. Elsevier/Academic, Amsterdam/London, pp 836–895
- Zilles K, Palomero-Gallagher N (2001) Cyto-, myelo-, and receptor architectonics of the human parietal cortex. *Neuroimage* 14:S8–S20

Microstructural Parcellation of the Human Cerebral
Cortex

From Brodmann's Post-Mortem Map to in Vivo Mapping
with High-Field Magnetic Resonance Imaging

Geyer, S.; Turner, R. (Eds.)

2013, VIII, 257 p. 187 illus., 39 illus. in color., Hardcover

ISBN: 978-3-642-37823-2