

---

# A Review of Rotator Cuff Classifications in Current Use

# 2

Paulo Santoro Belangero, Benno Ejnisman and Guillermo Arce

---

## 2.1 Background

To better understand the natural history of rotator cuff disease and its treatment, it is crucial to find a reliable method of classifying or describing rotator cuff tears. We can then use this classification to identify appropriate treatments for each type of tear that lead to the best outcomes. There are many rotator cuff classification systems in use today, making it difficult to compare results and to agree on proper treatment. In addition, when using any system, surgeons may not always agree on how a particular tear is classified.

After a comprehensive search in the literature available, Kuhn et al. were able to identify nine rotator cuff tear classifications systems that have been recommended to describe partial and full-thickness rotator cuff tears [1]. Each of these systems has been used in studying the outcomes of various treatments for rotator cuff tears. They developed a reliability study of 5 classification's systems: DeOrio (1984), Ellman (1995), Harryman (1991), Patte (1990), and Wolfgang (1974) [2–6]. The results from

---

P. S. Belangero (✉)  
Federal University of Sao Paulo, Estado de Israel 435 Ap131, São Paulo,  
SP 04022-001, Brazil  
e-mail: psbelangero@gmail.com

B. Ejnisman  
CETE-UNIFESP-EPM, Rua Vanderley 466 Ap232, São Paulo,  
SP 5011001, Brazil  
e-mail: bennoale@uol.com.br

G. Arce  
Department of Orthopaedic Surgery, Insituto Argentino de Diagnostico y Tratamiento,  
Marcelo T. de Alvear 2400, 1122 Buenos Aires, Argentina  
e-mail: guillermorace@ciudad.com.ar

that study demonstrated that experienced clinicians show very high agreement when deciding whether a rotator cuff tear is a partial-thickness tear or a full-thickness tear. In addition, clinicians are adept at agreeing on the side involved (articular or bursal) when a partial-thickness tear is identified. However, clinicians could not agree on the depth of the partial-thickness tears [1]. With regard to full-thickness tears, the results suggested that none of the classification systems resulted in excellent agreement [1].

Many factors as size, shape, retraction and fatty infiltration, are now recognized as being important in the preoperative assessment of the patient with a symptomatic rotator cuff tear. These factors are necessary to dictate appropriate surgical treatment and to counsel the patient on realistic expectations of postoperative outcome [7]. Any universal classification system should include these factors.

Most of the classifications systems in use today were developed for either for full or partial thickness tears. The first step in deciding on a universal classification system is to critically review each of these systems.

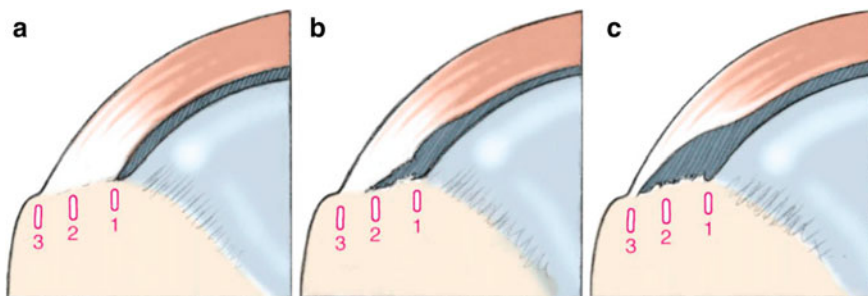
---

## 2.2 Partial-Thickness Tears Classifications

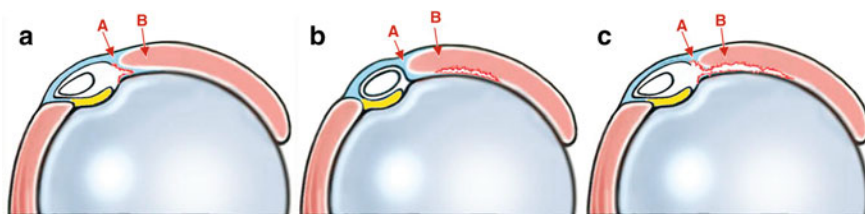
Ellman [8] was the first to popularize a system to classify partial thickness tears based on intra-operative findings. In his system, a Grade 1 tear is <3 mm deep, a Grade 2 is tear 3–6 mm in depth but not exceeding one-half of the tendon thickness and a Grade 3 tear >6 mm deep. Others have simplified the system referring to 6 mm or less (<50 %) or >6 mm (greater than 50 %). While there are not any studies on reliability, this system is used by many to decide on the type of surgical treatment. Snyder [9] included a more detailed classification of partial tears in his system (see below). His system has not been validated for reliability. Neither system includes interstitial tears that do not communicate with either the articular or bursal surfaces.

More recently, Habermeyer et al. have developed a new arthroscopic classification of articular-sided supraspinatus footprint lesions and a prospective comparison with Snyder's and Ellman's classification [10, 11]. They realized that, neither the classification of Snyder nor that of Ellman reproduced the extension of the partial-thickness rotator cuff tear in the transverse and coronal planes related to its etiologic pathomorphology [11]. Their system includes a gradation of the thickness of the partial articular-side tear as does Ellman and Snyder (see Fig. 2.1). It also includes a classification of tear size and location in the sagittal plane (see Fig. 2.2).

Although this system seems to be more complete than the previous, its still is an arthroscopic classification, which limits its use. It has not been validated for reliability and does not include a classification of bursal-side or interstitial tears.



**Fig. 2.1** The Habermayer classification of partial tears in the coronal plane. Longitudinal extension of articular-sided supraspinatus tendon tears in coronal plane. **a** Type 1 tear: small tear within transition zone from cartilage to bone. **b** Type 2 tear: extension of tear up to center of footprint. **c** Type 3 tear: extension of tear up to greater tuberosity (Reprinted with permission)



**Fig. 2.2** Habermayer classification of partial tears in the sagittal plane. Sagittal extension of articular-sided supraspinatus tendon tears in transverse plane. **a** Type A tear: tear of coracohumeral ligament continuing into medial border of supraspinatus tendon. **b** Type B tear: isolated tear within crescent zone. **c** Type C tear: tear extending from lateral border of pulley system over medial border of supraspinatus tendon up to area of crescent zone (Reprinted with permission)

## 2.3 Full-Thickness Tear Classification Systems

Today, many factors are felt to be important in describing full-thickness rotator cuff tears. These include: size, number of tendons involved, tear shape tissue quality, and CT/MRI assessment of fatty infiltration and atrophy of the muscles attached to the torn tendons. In a review of the commonly used systems, not one included all of these factors.

## 2.4 Tear Size

One of the most commonly used classification systems was developed by DeOrto and Cofield [2]. They classified tears by the anterior-posterior length of the tendon that was torn off of the humeral head as measured at the time of surgery. The

system classified tears as *small* if the tear was less than one cm, *medium* if the tear was between 1 and 3 cm, *large* 3–5 cm, and *massive* if the tear was greater than 5 cm in length. Bayne and Bateman [12] used a similar, but less commonly used system in which they classified tears as *Grade 1* if the tear was less than 1 cm after surgical debridement, *Grade 2*: 1–3 cm after debridement, *Grade 3*: 3–5 cm and *Grade 4*: global tear, no cuff left. It would appear that the classifications are similar and could be used interchangeably, but there have been no direct comparisons. The major drawback is these are not 3-Dimensional, so they can overestimate the difficulty of repair [13]. For example, a tear classified as *large* or *Grade 3* could be a 4 cm tear with minimal retraction and healthy, robust tissue, or a 4 cm tear retracted to the labrum with thin, friable tissue. In addition, they do not identify which tendon(s) are involved. Most surgeons would agree that a repair 2 cm tear of the supraspinatus may have a very different outcome when compared to a 2 cm tear of the subscapularis. These classifications do not normalized to the patient's size, so the value of the absolute size of the rotator cuff tear remains in question [1]. Finally, important factors related to surgical procedures as tear shape and fatty infiltration are not included. Nevertheless, the DeOrio and Cofield classification is one of the two most systems most commonly used in the orthopaedic literature.

---

## 2.5 Number of Compromised Tendons

Harryman [4] developed a classification system based on the number of tendons involved in the tear identified at the time of surgery. Stage 1A is a partial thickness tear, Stage 1B is a full-thickness tear isolated to the supraspinatus. Stage II includes the supraspinatus and at a portion of the infraspinatus. Stage III includes the entire supraspinatus, the infraspinatus and the subscapularis tendons. Stage IV is rotator cuff arthropathy. This system has not been validated.

Classifications systems based in the number of tendons involved as Harryman's [4] are important predicting the extent of surgical procedure necessary to repair the tear [14], but do not differentiate the tear pattern or method of repair [13].

---

## 2.6 Tear Shape

Ellman and Gartsman [3] developed a classification system to take into account the three dimensional nature of rotator cuff tears. *Crescent-shaped* tears are wide (anterior-posterior) with minimal retraction. *Reverse-L* and *L-shaped* tears have some portion of the tendon torn off of the humeral head and then extend into the tendon medially forming the shape of the letter L or a backwards L. The medial-lateral tear often is through the rotator interval between the subscapularis and supraspinatus, or in the interval between the supraspinatus and infraspinatus. *Trapezoidal* tears are larger looking like a trapezoid and *Massive* tears are larger

and irreparable. The classification, like the previous ones, is based on the findings at the time of surgery. It has not been validated.

One large drawback to each of the systems described above is the inability to use them pre-operatively to give the patient a prognosis for a successful outcome. The ideal classification system, once validated, should not only describe and categorize tear patterns, but it should also eventually be used to predict the type of surgery necessary to repair the tear and give a patient an idea of the eventual outcome of the surgical procedure. Because these systems classify the tear only during surgery, they cannot be used to prognostic purposes. We are not aware of any study that applies these classifications to pre-operative imaging.

Burkhart [13] developed a geometric classification system based on pre-operative MRI imaging. He classified the tear pattern into 4 shapes and felt that this shape was correlated to outcome. Measuring the tear on both sagittal and coronal MRI images, *Type 1* tears are crescent-shaped tears that are relatively short in the coronal image and wide on the sagittal image. *Type 2* tears are longitudinal (U-shaped and L-shaped) tears that are relatively long on the coronal and short on the sagittal images. *Type 3* tears are massive and contracted tears being both long on the coronal and wide on the sagittal images. *Type 4* tears include a massive tear and glenohumeral arthrosis and loss of acromiohumeral distance indicative of rotator cuff arthropathy. The advantage of this system is that it is used pre-operatively.

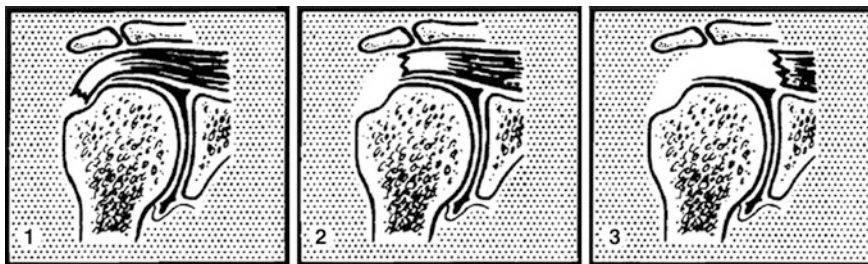These classifications rely in tear exclusively configuration alone. Although they add information that can help the surgical preparation (and prognosis in Burkhart's), they lack information about size, retraction and tendon quality.

---

## 2.7 Others (Complete/Complex)

Patte [5] developed a system that incorporated several factors including: (1) Extent of the rotator cuff tears; (2) Topography of the tear in sagittal plane; (3) Topography of the tear in frontal plane; (4) Topography quality of the muscles of the torn tendons; and (5) State of the long head of the biceps as measured on pre-operative imaging. Patte's classification is divided in 5 main categories and which one of then is further separated in many items. The most commonly used portion of the classification is retraction of the supraspinatus tendon in the coronal plane as shown below. Stage I is a tear with minimal retraction, Stage II is a tear retracted medial to the humeral head footprint but not to the glenoid, and Stage III is a tear retracted to the level of the glenoid (Fig. 2.3).

The Patte classification has been found to have consistently moderate agreement in assessing tear retraction in various studies [1, 15]. It has also been shown to have some prognostic value after rotator cuff repair [18]. However, size, shape and tissue quality as well as differentiation of the tendons involved are not included.



**Fig. 2.3** Patte classification of rotator cuff tears. The Patte score assesses the degree of tendon retraction in the frontal plane on MRI: full-thickness tear with little tendon retraction (1), retraction of tendon to level of humeral head (2), and retraction of tendon to level of glenoid (3) (Reprinted with permission)

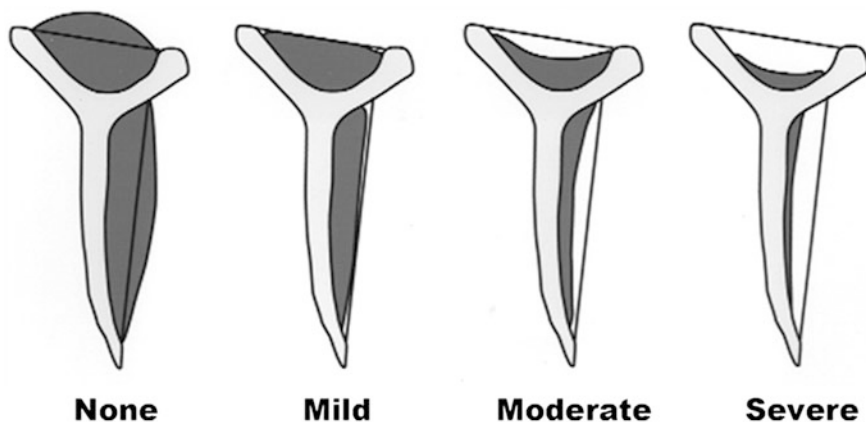
Snyder [9] developed a comprehensive classification to describe the extent of the tear, the location and the size. The location of the tear is classified as *Articular*, *Bursal*, or *Complete* thickness tears. Partial Thickness Tears are subclassified as 0—normal, 1—minimal superficial bursal or synovial irritation or slight capsular fraying over a small area, 2—Fraying and failure of some rotator cuff fibers in addition to synovial bursal or capsular injury, 3—More severe rotator cuff injury fraying and fragmentation of tendon fibers often involving the whole of a cuff tendon, usually <3 cm or 4—Very severe partial rotator cuff tear that contains a sizeable flap tear and more than one tendon. These descriptions are more qualitative than quantitative and do not have adequate inter-observer agreement.

Full Thickness tears are classified as: C1—Small complete tear, pinhole sized, C2—Moderate tear <2 cm of only one tendon without retraction, C3—Large complete tear with an entire tendon with minimal retraction usually 3–4 cm, C4—Massive rotator cuff tear involving 2 or more rotator cuff tendon with associated retraction and scarring of the remaining tendon. This system, as the others does not include all of the factors felt to be important in fully classifying tears of the rotator cuff tendons.

It is clear that the more complex the system, the less likely the agreement will be; on the other hand, a good classification should give solid information about type of surgery, difficulties and prognosis.

## 2.8 Tendon Quality

It has been shown that repair integrity is related to preoperative tear size and fatty infiltration on preoperative magnetic resonance imaging (MRI) [16, 17]. It has also been shown that fatty infiltration and muscle atrophy do not improve after successful structural repair of the rotator cuff and their presence correlates with poor



**Fig. 2.4** Warner classification of rotator cuff atrophy. The Warner grading of muscle atrophy is based on the relation of the muscle to a straight line connecting either the coracoid to the scapular spine (assessing the supraspinatus) or the coracoid to the tip of the scapula (assessing the infraspinatus) (Reprinted with permission)

functional outcomes [18, 19]. Thus, a complete rotator cuff classification system should include information about the pre-operative muscle atrophy and fatty infiltration of the rotator cuff muscles.

Thomazeau [10] classified the supraspinatus muscle belly based on the occupation ratio in the supraspinatus fossa in T1-weighted oblique-sagittal images (MRI). Stage I was normal or slightly atrophied, Stage II showed moderate atrophy, and Stage III was serious or severe atrophy. Warner et al. described a grading scale for muscle atrophy based on the oblique sagittal-plane magnetic resonance images [6] (see Fig. 2.4).

The system grades the atrophy of either the supraspinatus or infraspinatus muscle belly as none, mild, moderate or severe. Studies have shown moderate inter-observer agreement using this classification [6]. Atrophy of the infraspinatus has been shown to correlate with outcome in at least one study [18].

Goutallier introduced a classification of fatty infiltration of the supraspinatus based on the presence of fatty streaks within the muscle belly using CT images; Stage 0 is normal muscle, Stage I: muscle with some fatty streaks, Stage II: fatty infiltration is important, but there still more muscle than fat, Stage III: there is as much fat as muscle and Stage IV: more fat than muscle is present. This classification system is often quoted but studies have not shown good inter-observer agreement [6] and have not, as of yet been correlated to outcome. Fuchs has published a similar classification using MRI.

## 2.9 Conclusion

A surgeon's decision-making algorithm is often based on evidence derived from outcome studies. To appropriately apply study results to clinical practice, a reliance on standardized patient study populations is necessary. This is often based on commonly used classification schemes [7]. Our review has not identified any classification system in current use that includes all of the factors felt to be important in classifying rotator cuff tear patterns. Thus, a new system that includes tear size, location, shape, retraction, location and tissue quality that displays high inter and intra-observer reliability is necessary. (Please see references [20, 21] at the end of the chapter.)

---

## References

1. Kuhn JE, Dunn WR, Ma B et al (2007) Interobserver agreement in the classification of rotator cuff tears. *Am J Sports Med* 35:437–441
2. DeOrio JK, Cofield RH (1984) Results of a second attempt at surgical repair of a failed initial rotator cuff repair. *J Bone Joint Surg Am* 66:563–567
3. Ellman H (1993) Rotator cuff disorders. In: Ellman H, Gartsman GM (eds) *Arthroscopic shoulder surgery and related disorders*. Lea and Febiger, Philadelphia, pp 98–119
4. Harryman DT, Mack LA, Wang K, Jackins SE, Richardson ML, Matsen FA (1991) Repairs of the rotator cuff. Correlation of functional results with integrity of the cuff. *J Bone Joint Surg Am* 73:982–989
5. Patte D (1990) Classification of rotator cuff lesions. *Clin Orthop Relat Res* 254:81–86
6. Wolfgang GL (1974) Surgical repairs of tears of the rotator cuff of the shoulder. *J Bone Joint Surg Am* 56:14–26
7. Lippe J, Spang JT, Leger RR, Arciero RA, Mazzocca AD, Shea KP (2012) Inter-rater agreement of the Goutallier, Patte, and Warner classification scores using preoperative magnetic resonance imaging in patients with rotator cuff tears. *Arthrosc: J Arthrosc Relat Surg* 28(2)(February):154–159
8. Ellman H (1990) Diagnosis and treatment of incomplete rotator cuff tears. *Clin Orthop Relat Res* 254:64–74
9. Snyder SJ (2003) Arthroscopic classification of rotator cuff lesions and surgical decision making. In: Snyder SJ (ed) *Shoulder arthroscopy*. Lippincott Williams & Wilkins, Philadelphia, pp 201–207
10. Habermeyer P, Magosch P, Lichtenberg S (2006) Classifications of rotator cuff. In: Walch G, Boileau P (eds) *Classifications and scores of the shoulder*. Springer, Berlin
11. Habermeyer P, Krieter MC, Tang K-L, Lichtenberg S, Magosch P (2008) A new arthroscopic classification of articular-sided supraspinatus footprint lesions: a prospective comparison with Snyder's and Ellman's classification. *J Shoulder Elbow Surg* (Nov–Dec) 17(6):909–913
12. Bayne O, Bateman J (1984) Long-term results of surgical repair of full-thickness rotator cuff tears. In: Bateman JE, Welsh R (eds) *Surgery of the shoulder*. CV Mosby, Philadelphia, pp 167–171
13. Davidson J, Burkhart SS (2010) The geometric classification of rotator cuff tears: a system linking tear pattern to treatment and prognosis. *Arthroscopy* 26:417–424
14. Nho SJ, Brown BS, Lyman S, Adler RS, Altchek DW, MacGillivray JD (2009) Prospective analysis of arthroscopic rotator cuff repair: prognostic factors affecting clinical and ultrasound outcome. *J Shoulder Elbow Surg* (Jan–Feb 2009) 18(1):13–20. Epub: 16 Sept 2008



15. Spencer EE, Dunn WR, Wright RW et al (2008) Interobserver agreement in the classification of rotator cuff tears using magnetic resonance imaging. *Am J Sports Med* 36:99–103
16. Goutallier D, Postel JM, Bernageau J, Lavau L, Voisin MC (1994) Fatty muscle degeneration in cuff ruptures. Pre- and postoperative evaluation by CT scan. *Clin Orthop Relat Res* 304:78–83
17. Oh JH, Kim SH, Ji HM, Jo KH, Bin SW, Gong HS (2009) Prognostic factors affecting anatomic outcome of rotator cuff repair and correlation with functional outcome. *Arthroscopy* 25:30–39
18. Gladstone JN, Bishop JY, Lo IK, Flatow EL (2007) Fatty infiltration and atrophy of the rotator cuff do not improve after rotator cuff repair and correlate with poor functional outcome. *Am J Sports Med* 35:719–728
19. Melis B, Nemoz C, Walch G (2009) Muscle fatty infiltration in rotator cuff tears: Descriptive analysis of 1688 cases. *Orthop Traumatol Surg Res* 95:319–324
20. Fuchs B, Weishaupt D, Zanetti M, Hodler J, Gerber C (1999) Fatty degeneration of the muscles of the rotator cuff: assessment by computed tomography versus magnetic resonance imaging. *J Shoulder Elbow Surg* 8:599–605
21. Warner JJP, Higgins L, Parsons IM IV, Dowdy P (2001) Diagnosis and treatment of anterosuperior rotator cuff tears. *J Shoulder Elbow Surg* 10:37–46

Shoulder Concepts 2013: Consensus and Concerns  
Proceedings of the ISAKOS Upper Extremity Committees  
2009-2013

Arce, G.; Bak, K.; Shea, K.P.; Savoie III, F.H.; Kibler, W.B.;  
Itoi, E.; Mazzocca, A.D.; Beitzel, K.; Calvo, E.; Ejnisman, B.  
(Eds.)

2013, X, 98 p. 29 illus., 21 illus. in color., Softcover

ISBN: 978-3-642-38096-9