

P. Archbold, L.N. Favaro Lourenço Francisco,  
R. Kancelskis Prado, and Robert A. Magnussen

## General Information

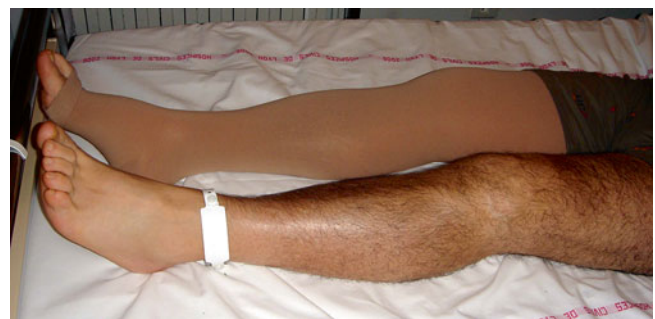It is essential that an orthopedic surgeon acquire the skills to perform arthroscopy at an early stage of his/her training. It can be compared to playing golf or driving a car, as when these skills are acquired at an early age they appear to come naturally. The subject of this chapter is not to give a general overview of the surgical options and situations encountered but instead to describe some tricks which can facilitate arthroscopy.

In this chapter, we will provide general concepts. The specific techniques and major indications will be presented in detail in the corresponding chapters.

## Surgery

### Patient Preparation

Following arrival at the hospital and prior to the administration of any medications, each patient puts a bracelet onto the lower limb that is to undergo surgery (Fig. 2.1). This gesture gives more responsibility to the patient and engages him/her in his/her own treatment. The person who prepares the lower limb for surgery then removes the bracelet in the operative theater. Consequently, the operating team is sure of the surgical side. Fortunately, in our institution, we have never had a “wrong side surgery.” General anesthesia is preferred as it offers complete amnesia of the intraoperative period and can be quickly administered. In the case of older patients, obese patients, and patients with limited respiratory capacity or a difficult airway, regional anesthesia can be used. This technique also allows for optimal pain relief in the operated limb.



**Fig. 2.1** A bracelet placed onto the operative extremity by the patient on the eve before surgery (or morning in case of outpatient treatment)

---

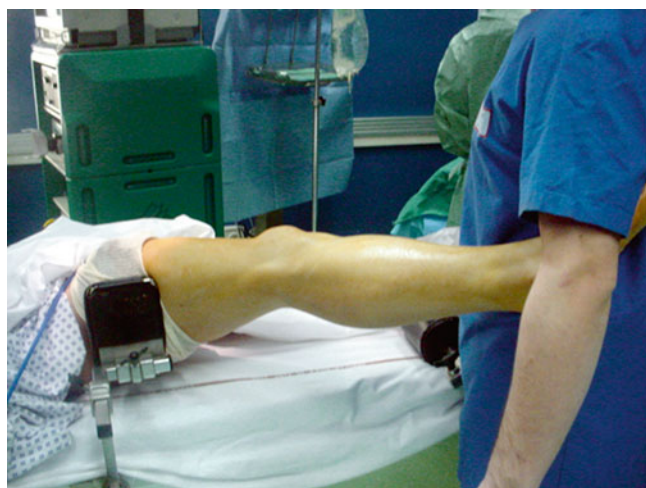P. Archbold, MD (✉)  
The Ulster Independent Clinic, 245 Stranmillis Road,  
BT95JH Belfast, Northern Ireland, UK  
e-mail: [poolerarchbold@aol.com](mailto:poolerarchbold@aol.com)

L.N. Favaro Lourenço Francisco, MD • R.K. Prado, MD  
São Paulo, Brazil  
e-mail: [lucionuno@hotmail.com](mailto:lucionuno@hotmail.com); [rodrigo27prado@hotmail.com](mailto:rodrigo27prado@hotmail.com)

R.A. Magnussen, MD, MPH  
Department of Orthopaedic Surgery,  
Sports Health and Performance Institute,  
The Ohio State University, Suite 3100,  
2050 Kenny road, Columbus, OH 43221, USA  
e-mail: [robert.magnussen@gmail.com](mailto:robert.magnussen@gmail.com)

## Patient Positioning

The patient is placed on the operating table in the supine position. A vertical post is positioned at the proximal third of the thigh to resist a valgus stress on the knee (Fig. 2.2), and a tourniquet is placed high around the thigh. The quality and ease of the arthroscopy is facilitated by the ability to place the knee in valgus (for improved visualization of the medial compartment) and by the use of the tourniquet to facilitate hemostasis and visualization. A second horizontal post is positioned distally on the table to hold the knee in a 90° flexed position. This technique has the advantage of allowing the knee to be held at both 90° of flexion (when the heel of the foot rests on the post) and at 110° of flexion (when the toes of the foot rest on the post). A further advantage is that this



**Fig. 2.2** Valgus stress on the knee using a vertical post laterally positioned at the proximal third of the thigh

setup can be used to combine arthroscopic and open surgery (e.g., arthroscopic and open surgery on the patella or an osteotomy (Fig. 2.3a, b).

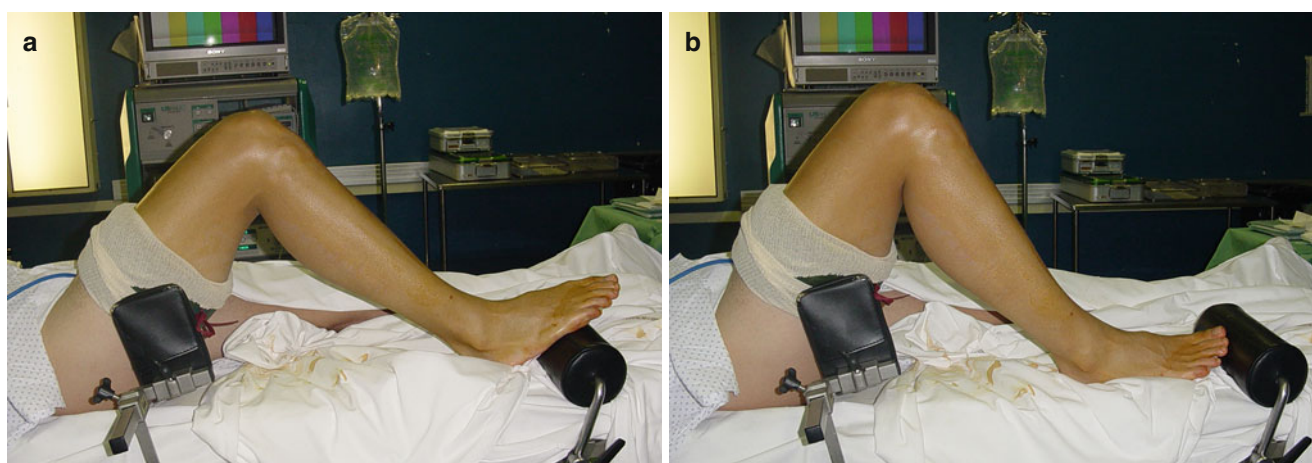
The lower limb is sterilely prepared using Betadine (or chlorhexidine in the situation of an iodine allergy). The foot is covered with a surgical glove size 9 and then the lower limb is covered with a stocking and subsequently an extremity sheet. The limb is elevated for several seconds and the tourniquet is inflated. The pressure of the tourniquet should be a minimum of 200 mmHg above the diastolic blood pressure or in absolute numbers approximately 300 mmHg. It should never be inflated longer than 120 min.

## Instrumentation

The essential piece of equipment is an arthroscopic tower including a camera, a monitor, and a light source. An arthroscopic pump, a shaver, and a recording device are useful aids and are routinely used in our department. Image recording is considered very important not only to document the intervention but also to inform the patient as to the surgical findings in a simple and accurate way.

In our department, we have three fully equipped arthroscopic towers available for three operating rooms and a sufficiently large number of arthroscopes and cameras. The arthroscopic infusion fluid chosen is an isotonic saline solution. A minimal pressure of 50 mmHg suffices to obtain an acceptable distension of the knee joint.

The sleeve for the arthroscope has an inlet and an outlet. We use a 4 mm diameter lens with 30° angulation. In case of reconstruction of the PCL or arthroscopy in the posterior region of the knee, a 70° arthroscope can be used.



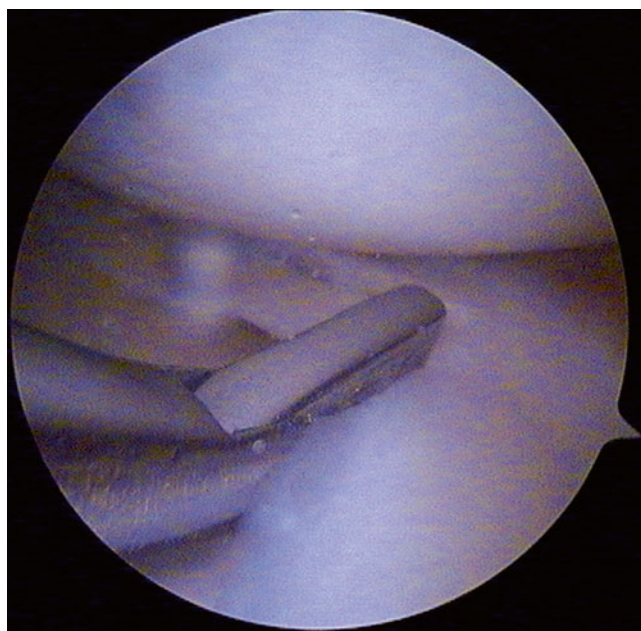
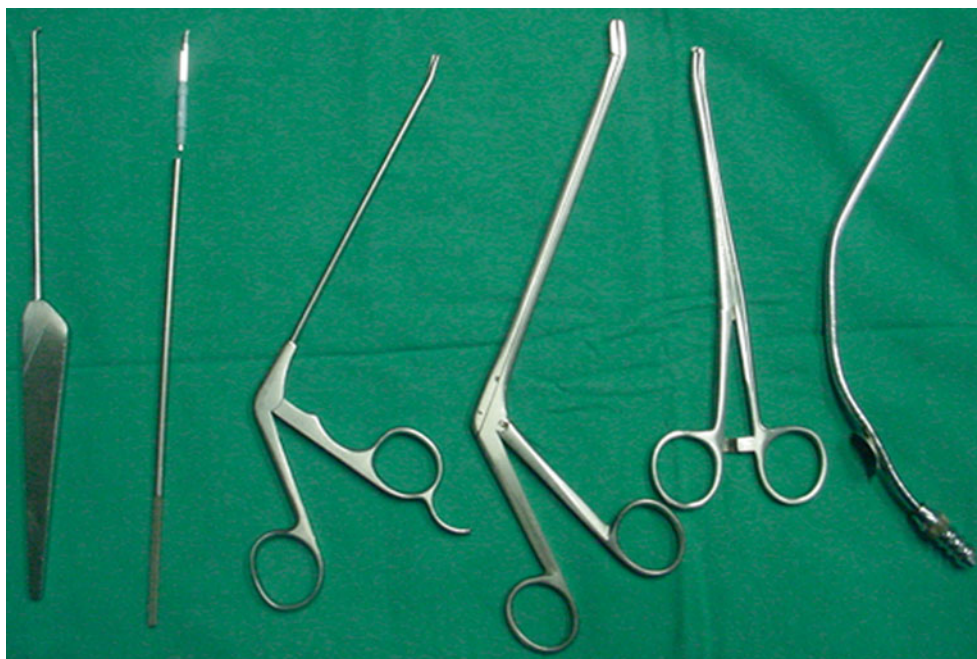**Fig. 2.3** Patient positioning. A horizontal post is positioned distally on the table to hold the knee in a 90° flexed position (a) or at 110° of flexion when the toes rest on the post (b)

## Surgical Instruments

The list of available instrumentation becomes longer each day as arthroscopic techniques advance. Certain instruments, however, are indispensable and make form the “basic

toolbox”: the probe, the arthroscopic scissors, a punch, a large grasper, and a cannula (Fig. 2.4). The punch, which is the indispensable instrument for performing a meniscectomy, has a straight tip and a slightly angled shaft to facilitate sliding under the femoral condyle (Fig. 2.5).

**Fig. 2.4** Surgical devices used in our practice – from left to right: probe, beaver knife, punch, biopsy forceps, grasping forceps (Wolf forceps), and suction cannula



**Fig. 2.5** Meniscectomy using the punch



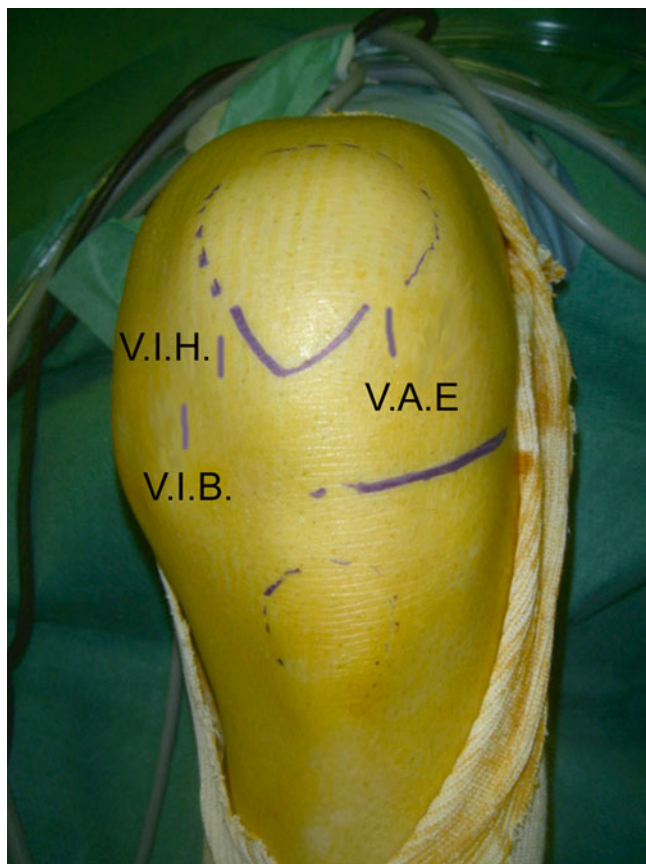
## Surgical Technique

### Portals

Triangulation is the most effective arthroscopic technique. It requires two portals, which can be made in a variety of positions:

- The anterolateral portal
- Two anteromedial portals
- The superolateral portal
- The superomedial portal
- The posteromedial portal
- The posterolateral portal
- The lateral parapatellar portal of Patel
- The posteromedial and posterolateral portals as described by Ph. Beaufile

The anterolateral and the two anteromedial portals are the most frequently used. Using these three portals, one can perform 95 % of the surgical procedures. The other portals are considered accessory portals (Fig. 2.6). The choice of the medial portal depends on the indication and on the arthroscopic finding. One should never hesitate to make an additional third portal or to reverse the location of the camera and instrumentation between portals. Attempting to use inadequate portals to avoid an additional incision will surely lead to mistakes.



**Fig. 2.6** Left knee, anatomical landmarks (anterior tibial tuberosity, patella, lateral tibial plateau), and anterolateral, low anteromedial, and high anteromedial portals

### The Anterolateral Portal

This portal is used to introduce the camera. It allows good visualization of the joint. The skin landmarks are medially, the lateral edge of the patellar tendon; inferiorly, the lateral tibial plateau; and superiorly, the lateral femoral condyle. The entry point of the portal is just inferolateral to the patella. An 11 blade is introduced with the blade angled proximally (to protect the meniscus), and a vertical incision is made in the soft spot situated between the lateral tibial plateau, the lateral femoral condyle, and the inferolateral patella.

If the incision is placed too low, the available space to position the camera will be reduced and there is a risk of damaging or cutting the anterior horn of the lateral meniscus. This situation is often encountered in cases of patella baja or when the surgeon opts to reuse a previous skin incision.

### The Two Anteromedial Portals

#### The Lower Anteromedial Portal

This portal provides access to the anteromedial joint space, which is situated just above the medial meniscus. In order to avoid damage to the medial meniscus some strict rules must be adhered to. The knee should be flexed at 90° with the foot positioned on the distal post. Please note that the lower anteromedial portal is situated closer to the femorotibial joint line than the anterolateral portal. The inferomedial portal is also farther from the patella tendon. With the scope in the anterolateral portal, one can transilluminate this medial area for guidance.

This skin incision is again made with an 11 blade directed superiorly (and never inferiorly!). The skin incision is vertical and 5–8 mm in length. Under arthroscopic control, the blade is visualized as it enters the joint just proximal to the superior surface of the medial meniscus. One can now turn the scalpel 90° and widen the capsular incision horizontally just above the meniscus. This portal, which is just above the superior surface of the medial meniscus, allows easy access to the medial compartment for a successful meniscectomy. A portal placed too centrally will enter in the area of Hoffa's fat pad, significantly limiting visualization.

#### The Superior Anteromedial Portal

Symmetrical to the anterolateral portal, thus more central and more proximal than the lower anteromedial portal, this portal gives improved access to the intercondylar notch. In the figure-of-four position, this portal provides perfect visualization of the lateral compartment and provides optimal access to treat lateral meniscal lesions. Both the lower and superior anteromedial portals can be used in combination.

### The Superolateral Portal

This portal, superior and lateral to the patella, gives access to the patellofemoral compartment, the suprapatellar pouch, and the lateral condylar gutter. This portal can be used for the evaluation of patellofemoral cartilage and patellar tracking as well as for arthroscopic synovectomy and arthrolysis.

### The Superomedial Portal

This portal is symmetrical to the superolateral portal but on the medial side of the patella. The entry point is slightly more proximal (approximately 2–3 cm above the patella) to allow easy instrumentation.

### The Posteromedial Portal

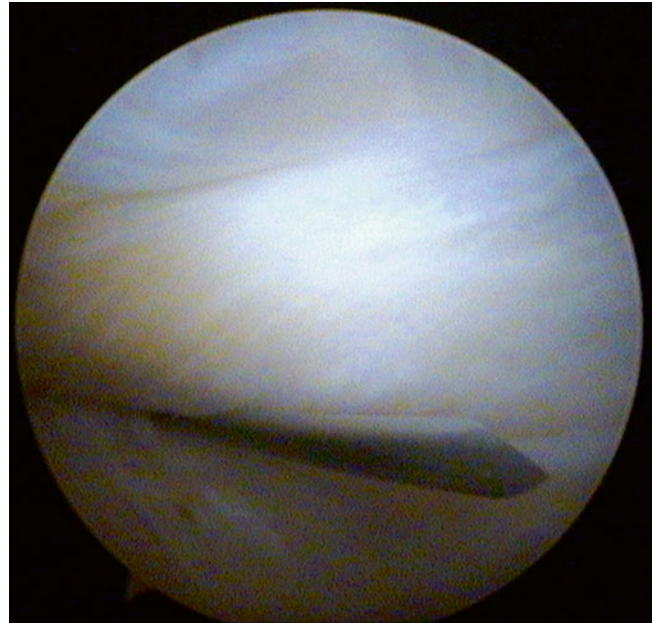
This portal is used to visualize the posterior compartment and posterior horn of the medial meniscus. The tibial insertion of the posterior cruciate ligament can also be visualized. The skin incision should be proximal enough to allow the entry point on the capsule to be in contact with the posterior part of the medial condyle. This positioning allows optimal orientation of the instruments. A skin incision that is situated too distal will increase the difficulty of the surgery.

In order to facilitate the correct positioning of the skin incision, a spinal needle can be introduced. The knee should be positioned in the figure-of-four position and the capsule of the knee completely distended (Fig. 2.7). The capsular entry point of the needle can be visualized by transillumination with the camera placed through the intercondylar notch (Fig. 2.8).

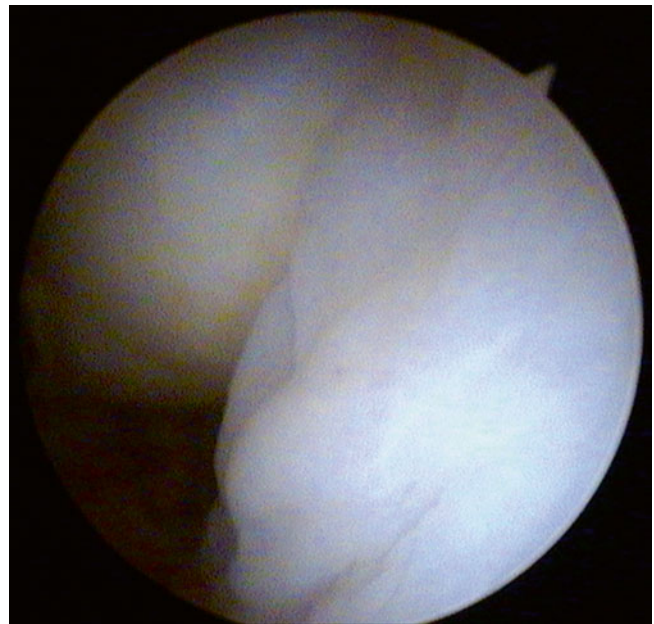
### The Posterolateral Portal

This approach can be used to visualize the posterolateral compartment and the posterior horn of the lateral meniscus. As for the posteromedial approach, a spinal needle can be used to help determine the exact site of the skin incision. The needle is introduced just superior to the lateral femoral condyle with the knee in a 90° flexed position.

The tip of the needle can be visualized with the arthroscope placed in the intercondylar notch. The skin incision is subsequently made with an 11 blade guided by the spinal needle and oriented toward the condyle. The combination of the posteromedial and posterolateral portals has been previously described in detail by Philippe Beaufils.



**Fig. 2.7** Posteromedial portal, left knee. A spinal needle is inserted through the capsule distended by arthroscopy fluid



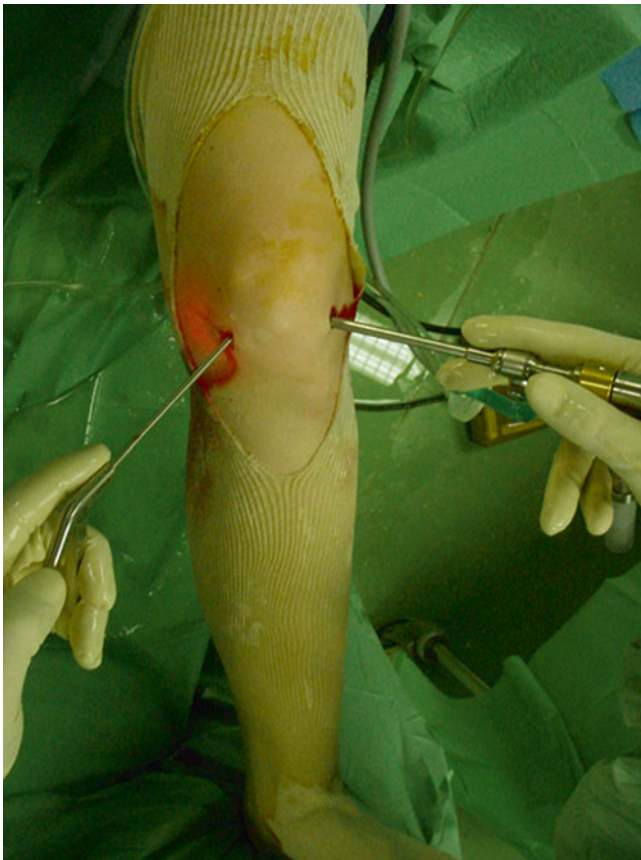**Fig. 2.8** Posteromedial portal, left knee. The ACL (*right*) and the posterior lateral femoral condyle (*left*) are visualized



### The Lateral Parapatellar Portal of Patel

This portal is situated along the lateral border of the patella but more laterally and proximally than the classic anterolateral portal. This approach gives an excellent view on the lateral femorotibial compartment and in particular the anterior horn of the lateral meniscus.

All the abovementioned portals can be used for instrumentation, but the anterolateral and anteromedial portals are the most frequently used (Fig. 2.9). We have never used the transpatellar portal described by Gillquist. Some surgeons use it in order to have a better visualization of the posterior aspect of the notch.



**Fig. 2.9** Portals, left knee. Anterolateral portal (arthroscope, *right*) and low anteromedial portal (instrument, *left*)

### Arthroscopic Steps

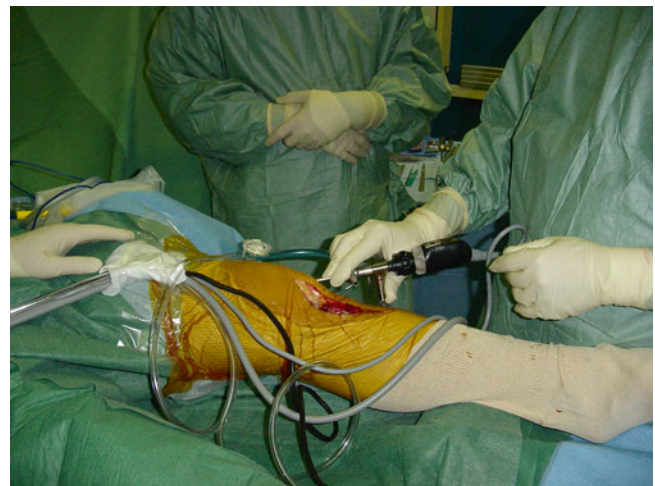After anesthetic induction, the knee is reexamined to complete the physical examination. The sleeve and obturator are introduced through the anterolateral portal in the direction of the femoral notch with a knee in the 90° flexed position. The sleeve is then directed to the suprapatellar pouch while extending the knee. The inflow cannula is subsequently connected and the joint is distended. The obturator is removed and the camera is introduced. The intra-articular examination is performed in a systematic fashion. The sequence of the surgical steps is inspection, then palpation, and subsequently treatment. By beginning with the inspection of the knee, one can adapt and choose the necessary portals for instrumentation.

The knee cavity is inspected in a systematic sequence:

- The patellar femoral compartment
- The medial and lateral tibiofemoral compartment
- The intercondylar notch

### The Patellofemoral Compartment

The lower limb is extended in neutral rotation to rest on the operating table. The exploration starts in the suprapatellar pouch. We do not use an outflow sleeve for lavage except in cases of a significant hemarthrosis. The camera is introduced through the anterolateral portal and the lens is angled



**Fig. 2.10** Placing the arthroscope to examine the patellofemoral joint

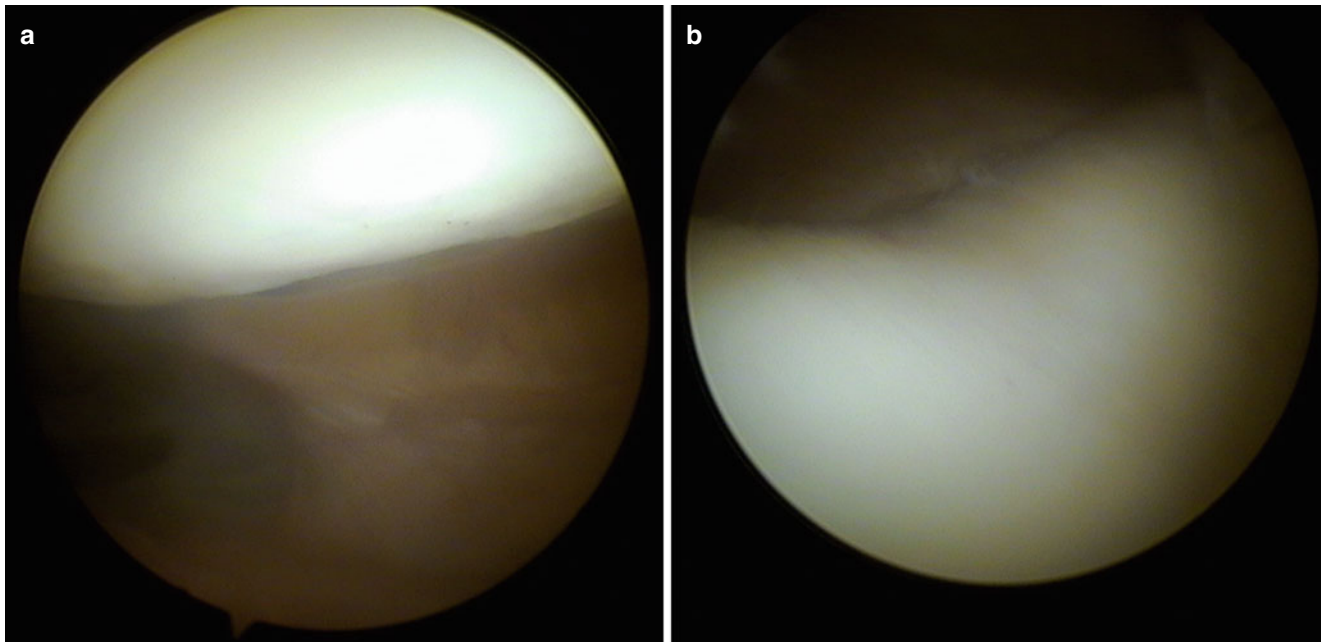
proximally (Fig. 2.10). The intra-articular space is opened up by distention.

With the camera lens oriented proximally and in the direction of the patella, one can examine the medial facet, the lateral facet, and the central ridge of the patella (Fig. 2.11).

Excellent visualization of the patellofemoral compartment can also be achieved through the suprapatellar portal (frequently used in the case of episodic dislocation of the patella). After inspection of the patella and trochlea, the arthroscope is progressively retracted to the point where adequate visualization of the patellofemoral compartment is

lost. The arthroscope is now rotated into the neutral position with the camera lens orientated at 90° looking toward the suprapatellar pouch. This maneuver allows simultaneous inspection of the patella and trochlea. In particular it allows inspection of the part of the trochlea just above the notch. Although generally not inspected, this zone is frequently damaged (deceleration lesions).

The camera lens remains at the 90° and now slides along the medial femoral gutter while the hand that is holding the camera is now directed proximally, bringing the camera distally into the medial tibiofemoral joint.



**Fig. 2.11** Patellofemoral compartment: (a) Patella, (b) trochlea

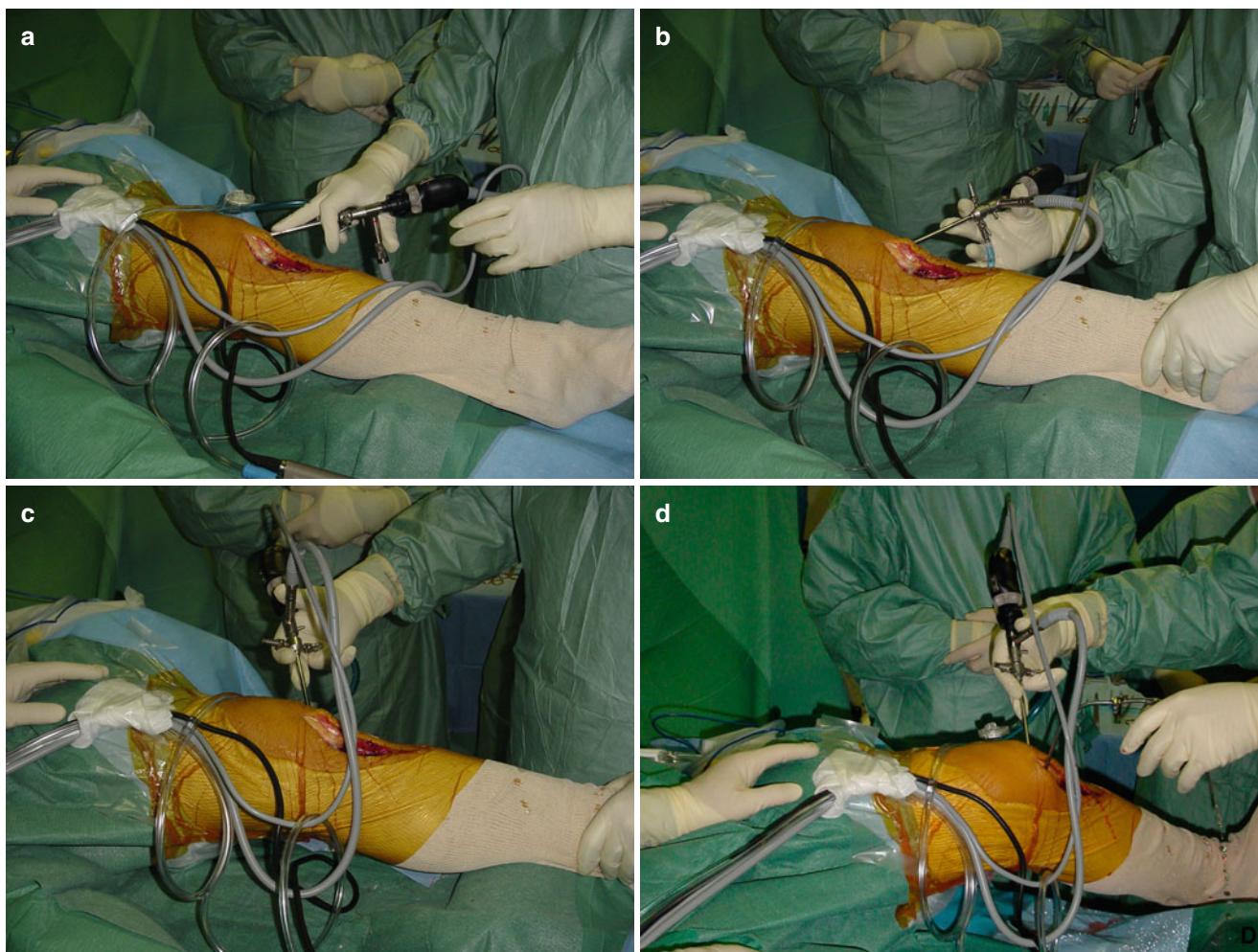


### The Medial Tibiofemoral Compartment

The lower limb is now elevated off the table and held in position by placing it on the contralateral iliac crest of the surgeon (Fig. 2.12a). Subsequently, the medial femoral condyle and the medial compartment can be visualized with the knee in about 30° of flexion (Fig. 2.12b, c). The knee can now be placed into valgus (the patient's foot is moved laterally while the thigh is held by the post) (Fig. 2.12d). It is often helpful for an assistant to place a downward force on the thigh at the level of or just distal to the tourniquet to prevent excessive knee flexion (Fig. 2.13). This maneuver helps open up the medial compartment allowing the entire body of the medial meniscus to be easily visualized. The synovial fringes can be easily identified because of the slight pink color. The free meniscus border

is checked as well as the anterior and posterior horns (Fig. 2.14). As yet we have not performed a percutaneous release of the deep fibers of the MCL to improve visualization, as has been described by H. Paessler. Pushing in the popliteal fossa with the fingers can help bring the posterior horn of the meniscus more anteriorly. Palpating the medial meniscus can be done with a probe introduced through the anteromedial portal (Fig. 2.15). The peripheral attachments of the meniscus can be evaluated, potential meniscus lesions investigated, and the quality and texture of the meniscus assessed.

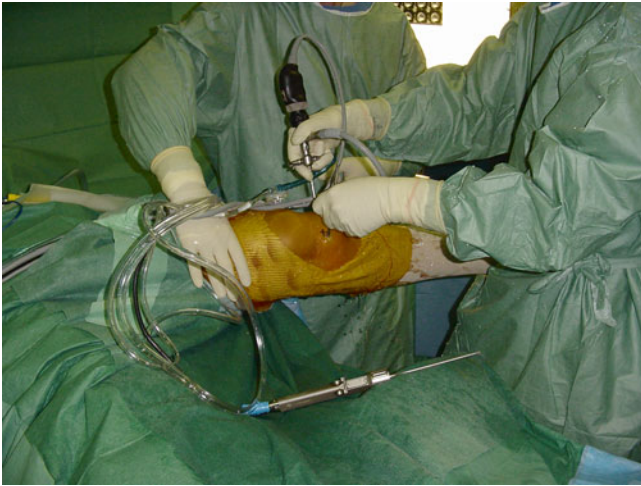The articular cartilage of the medial femoral condyle and the medial tibial plateau are palpated (Fig. 2.16). Slowly flexing the knee allows evaluation of both the integrity of the articular surface as well as the quality of the cartilage.



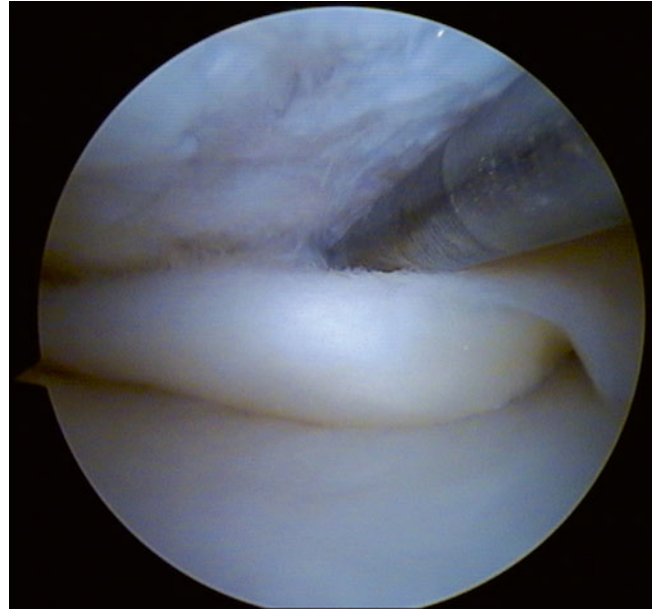
**Fig. 2.12** Changes in the position of the arthroscope from the patellofemoral compartment to the medial tibiofemoral compartment. The arthroscope looks at the suprapatellar recess (a), it is switched to

the neutral position parallel to the joint space (b), the arthroscope is rotated down in the medial tibiofemoral compartment (c) while the leg is positioned in valgus (d)

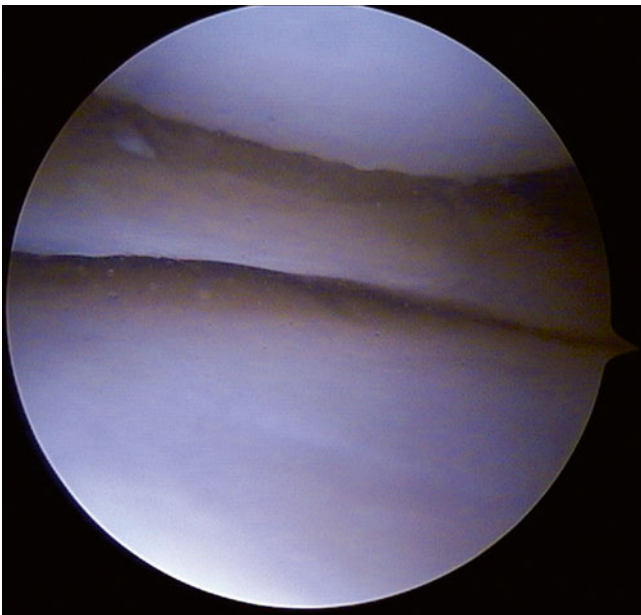




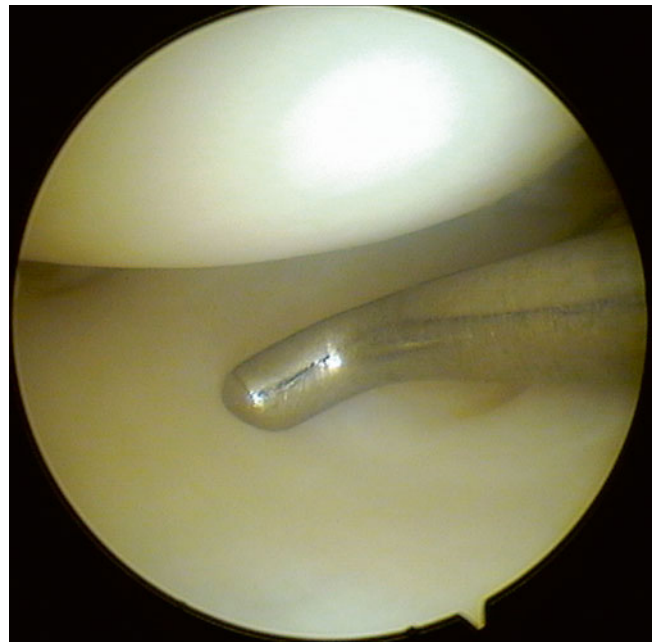
**Fig. 2.13** Position of the surgeon and assistant during a medial meniscectomy



**Fig. 2.15** Palpation of the medial meniscus, showing an unstable lesion. Note the femoral chondral lesions



**Fig. 2.14** Normal medial meniscus, body

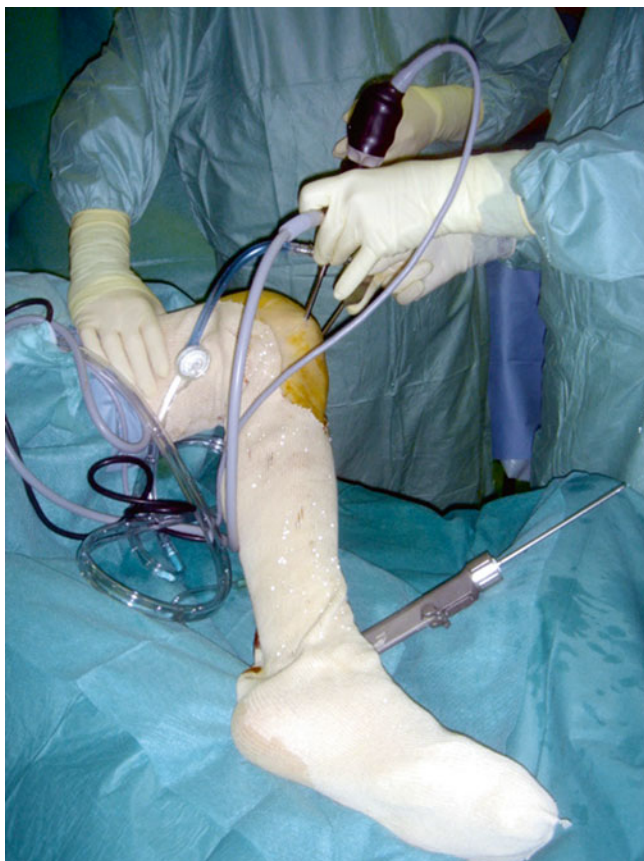

**Fig. 2.16** Palpation of tibial plateau cartilage

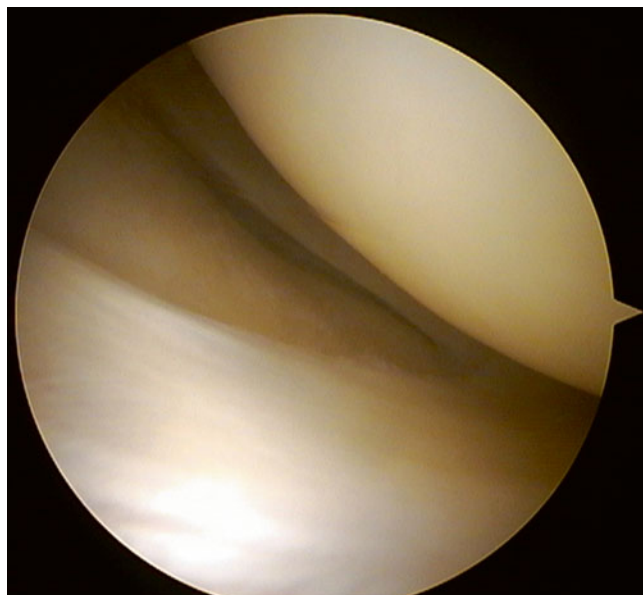
### Lateral Tibiofemoral Compartment

The arthroscope is not removed from the joint and the knee is now positioned in the Cabot (Fig. 2.17) position, i.e., the knee in varus and flexed to 90°. The foot rests on the contralateral tibia. The hip is flexed, abducted, and in external rotation. This maneuver opens up the lateral compartment (Fig. 2.18). The superior and inferior surface of the anterior, body, and posterior horn of the lateral meniscus can be visualized. The intra-articular course of the popliteal

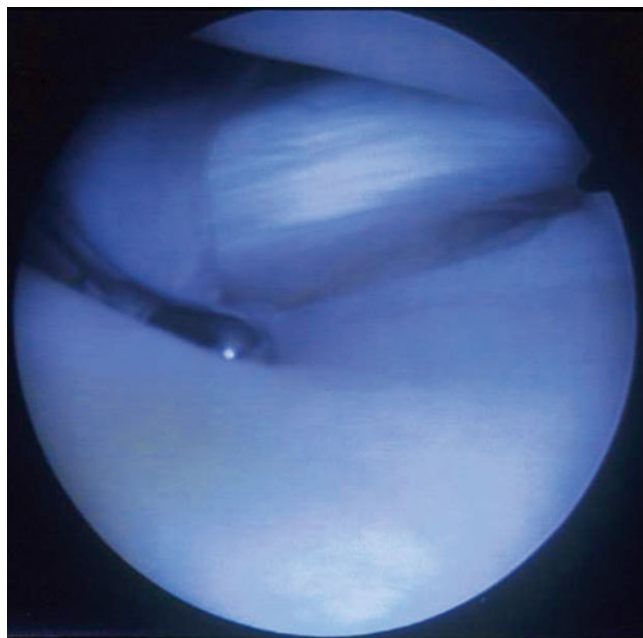
tendon can be seen. It runs anteriorly and superiorly from its origin posterior tibia to its insertion on the lateral femoral condyle. It is necessary to check the tendon and the hiatus since specific anatomic variations have been observed (Fig. 2.19). The meniscal wall and the menisco-popliteal attachments can be well visualized. Anatomical variations of the lateral meniscus can be observed and potentially treated (discoid meniscus, hypermobile meniscus).



**Fig. 2.17** Cabot (figure-of-four) position to assess the lateral tibio-femoral compartment



**Fig. 2.18** Normal lateral meniscus. Note that the meniscus is inclined to the horizontal on the screen



**Fig. 2.19** Popliteus tendon

### The Intercondylar Notch

To visualize the intercondylar notch, the knee is flexed to 90° with the foot resting on the post (Fig. 2.20). A synovial extension between the Hoffa fat and the lateral condyle also known as the ligamentum mucosum or infrapatellar plica can obstruct adequate visualization of this region. If this is the case, we routinely resect this ligamentum mucosum with the shaver at its attachment superior to the notch, allowing it to fall out of the way of the camera.

The ligament of Humphrey and the PCL can now be observed in the upper part of the intercondylar notch. They occupy the medial two-thirds of the intercondylar notch while the anterior cruciate ligament has a more horizontal course to the back of the notch where it inserts on the lateral femoral condyle. The appearance of the intercondylar notch as an inversed “U” or a capital “A” is noted in the operative report as well as the presence of any osteophytes.

The anterior cruciate ligament can be easily recognized due to its white color and covering with a thin, vascularized synovium (Fig. 2.21). The two separate bundles of the ACL can be frequently discerned. Its origin is very posterior on the lateral condyle and “low” with the knee in flexion. The tension of the ACL can be tested by palpation. The postero-lateral bundle is only under tension near full extension.

The posterior cruciate ligament is covered by the more horizontally oriented ligament of Humphrey and by

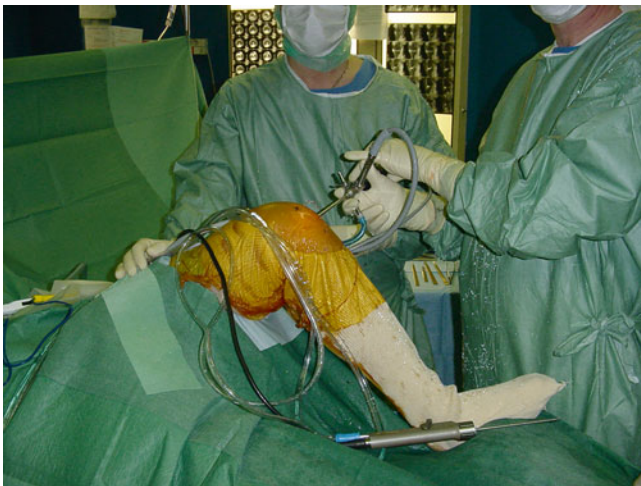synovial tissue (Fig. 2.22). The ligament of Humphrey, also known as the anterior meniscomfemoral ligament, should not be mistaken for the PCL. It originates from the posterior horn of the lateral meniscus then crosses the PCL anteriorly to insert just in front of the PCL on the medial femoral condyle. The PCL can be palpated at a level of its insertion on the femoral condyle. The surface area of the ligament of Humphrey is less than 30 % of the PCL (Fig. 2.23).

Despite the presence of the cruciate ligaments in the intercondylar notch, access to the posterior knee compartment is possible. This can be done by gently gliding the sleeve and the round-tipped obturator along the medial femoral condyle underneath the PCL with the knee at 90° of flexion.

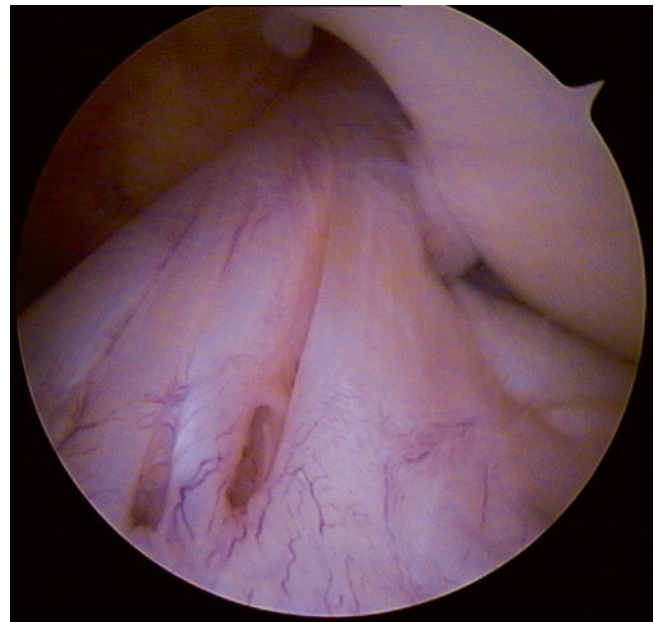
While pushing the sleeve and obturator, the knee is gently flexed up to 110°. The obturator is removed. The camera is introduced and the posterior compartment is now visualized. The insertion of the PCL (Fig. 2.24) on the tibia can be observed.

At the end of the arthroscopy, we manually apply pressure to the suprapatellar pouch and flex the knee in order to evacuate the intra-articular fluid.

Small meniscal or cartilaginous fragments can sometimes be found in the portals. As these can result in persistent irritation and induration of the wound, we pinch the portal between two fingers to remove them.

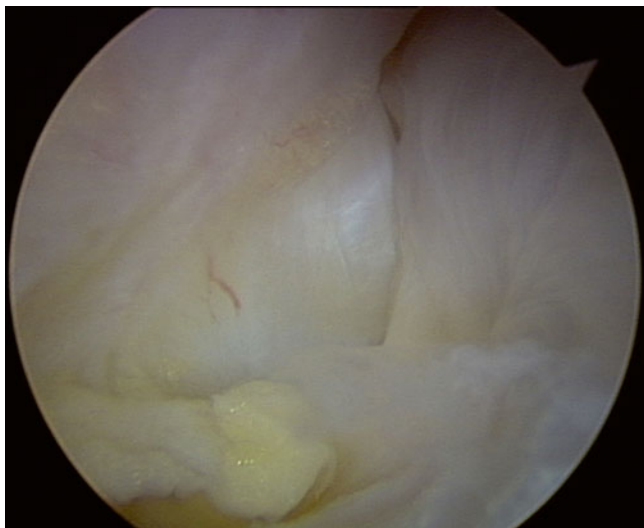


**Fig. 2.20** Position for the examination of the intercondylar notch

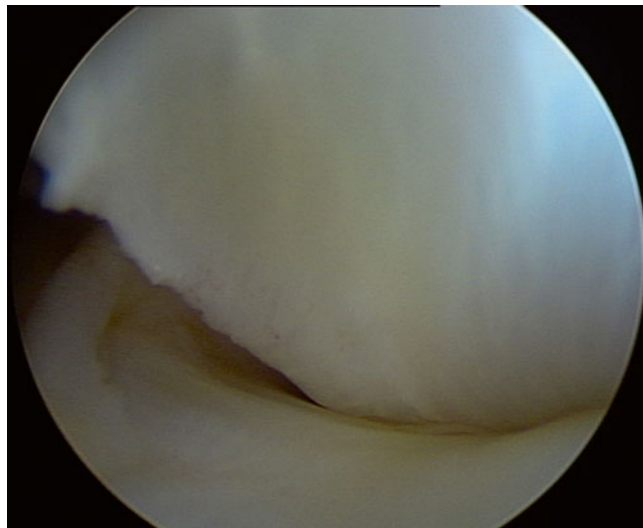


**Fig. 2.21** Anterior cruciate ligament (ACL)

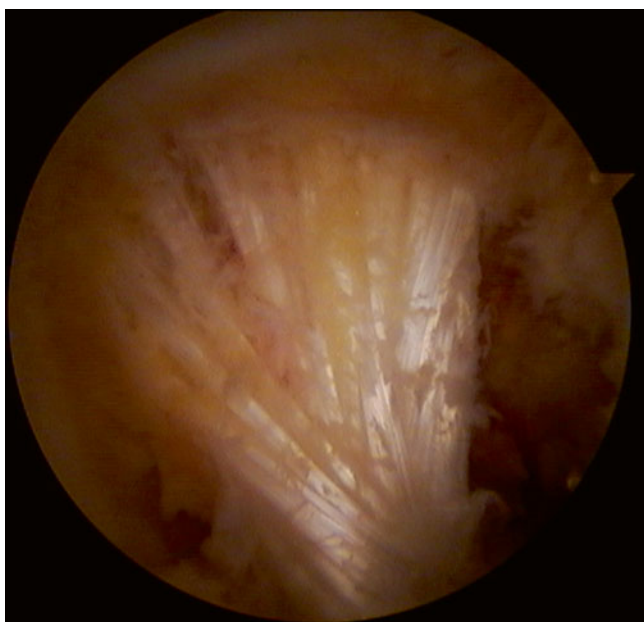




**Fig. 2.22** The intercondylar notch, left knee. The femoral origins of the PCL (*right*) and ACL (*left*, in front of the PCL) are observed



**Fig. 2.24** The tibial insertion of the PCL (left knee)



**Fig. 2.23** The ligament of Humphrey in front of the PCL, left knee

## Postoperative Care

No drain is necessary. Nonabsorbable skin sutures are removed on the tenth postoperative day. Thromboprophylaxis is not necessary except for patients at higher risk for DVT. The use of routine prophylactic antibiotics is not recommended.

Outpatient treatment is preferred unless specific medial or social concerns require an inpatient stay.

Mobilization of the knee is performed immediately and physiotherapy is prescribed for nine sessions. We allow the patients to drive a car on the third or fourth postoperative day (this delay is probably too short but a longer delay is not acceptable).

Activities of daily life are limited for the first week and professional activities are limited for 2–4 weeks, depending on the profession. All patients are reviewed at day 45 to assess postoperative recovery. Sport activities are allowed at 4–6 weeks.

The patients should always be informed before the intervention of the rare but real risk of infectious complications as well as the possibility of a longer than usual rehabilitation period. This information is essential. Arthroscopic surgery should not be considered nor presented to the patient as being harmless. Treatment failures or persistent lesions are observed in 1 % of our patients.

## Complications

Paresthesia and hypoesthesia are not commonly observed after an arthroscopy. By systematically transilluminating the skin during creation of the anteromedial portal, one can limit the frequency of lesions to the sensitive nerve branches in this area. Dysesthesias have also been reported and can lead to a complex regional pain syndrome (algodystrophy).

We have not observed skin necrosis. A possible reason could be that we do not perform arthroscopic lateral patellar release with an electrocoagulator. We have never observed tibial or femoral fractures during an arthroscopic procedure. We have observed three cases of a complete medial collateral ligament tear in our long experience over 20 years. These lesions have always healed uneventfully with conservative treatment. We have always been able to extract parts of broken instruments or meniscal fragments. Stopping inflow of the irrigation fluid can facilitate extraction.

## Other Complications

Iatrogenic intra-articular injuries can be reduced if not completely eliminated through careful attention to detail. Perhaps most importantly, the head of the shaver should always be visualized before shaving, especially in the posterior compartment in order to avoid an injury to neurovascular structures.

<http://www.springer.com/978-1-4471-5630-7>

Surgery of the Knee

Neyret, P.; Demey, G. (Eds.)

2014, IX, 419 p. 686 illus., 588 illus. in color., Hardcover

ISBN: 978-1-4471-5630-7