

---

## Introduction

The hand is one of the most complex anatomical structures in the human body. It is said that the hand is the mirror of the brain. Especially evolutionary specialization of the thumb as an opposing digit makes it the most important digit in a way providing exceptional motor abilities. Because of these complex functions, injuries to the hand severely compromise a patient's well-being, although they are rarely life-threatening. So immediate evaluation and accurate diagnosis of hand injuries carry great importance. With a thorough history, systematic examination, and knowledge of disease process of the hand, it is possible to make the clinical diagnosis with a considerable accuracy. Radiographs, electrodiagnostics [1, 2], and specialized laboratory test will only be ancillary tools to confirm the diagnosis. However, recording the clinical findings is also important in order to demand the necessary diagnostic tools and in the patient follow-up.

In this chapter an approach to clinical examination of the hand will be outlined as in order: patient history, inspection, palpation, assessing range of motion, neurologic examination, and specific tests.

---

## Patient History [3]

Patient history is the key point in the examination and provides sufficient information for tentative diagnosis. The diagnosis with 60 % accuracy can be made with only taking a good patient history. As always patient history begins in noting down the demographic information such as the patient's age, occupation, avocation, and hand dominance. The patient's general condition, systemic diseases such as diabetes mellitus, and cardiovascular problems are also important and influence the main pathology. Any previous illness and trauma should also be noted. Especially in acute trauma, site and description of the accident (cuts, crush injuries, saw accidents, chemical or burn injuries, bite wounds, closed trauma) are important in the means of making the diagnosis and deciding the subsequent treatment strategy.

Inquiring pain symptoms is also important. The pattern of pain and whether the pain fluctuates over time should be asked. Location of the pain, characteristics of the pain, and amplitude of the pain should be noted. Asking any aggravating or relieving factors and if the pain is constant or work related is also important. How does the pain affect the patient's daily living activities? What was the patient capable of doing in the past and what is he/she is capable of doing now? Accompanying symptoms beside the pain should be inquired. For example, accompanying numbness and weakness in the index and middle finger are often characteristics of carpal tunnel syndrome.

---

F. Dincer, M.D. (✉) • G. Samut  
Department of Physical and Rehabilitation Medicine,  
Faculty of Medicine, Hacettepe University Hospital,  
Hacettepe University, Ankara, Turkey  
e-mail: [fitnatdincer@gmail.com](mailto:fitnatdincer@gmail.com)

Pain aggravating with heat and often worse in the morning and with rest in the metacarpophalangeal and proximal interphalangeal joints is usually a sign of inflammatory condition, especially rheumatoid arthritis [4].

While obtaining the patient history, clinical suspicion usually develops, and other diagnostic studies and physical examination are required only for confirmation. This is why, as mentioned before, taking a careful, detailed, and comprehensive history is very important and necessary in order to make a thorough diagnosis.

---

## General Inspection

Evaluation of the patient always begins with general inspection in all kinds of physical examination, just as in hand examination. Once the patient enters the room, the examination begins, and the patient is observed as a whole, the patient's general being, posture, walking pattern, etc. After a general look, the whole upper extremity is observed. Any asymmetry of shoulders, shape of posture of the hand, and difference between both upper extremities are documented. Any swelling, deformities, and congenital abnormalities are reported. While generalized swelling may be the sign of circulatory problem, localized swelling can indicate inflammation, fracture, tumors, and ganglia originating from tendons or joints. Axial deformities may indicate a fracture. Muscle atrophy may be due to prolonged inactivity or chronic peripheral nerve compression [5] (i.e., carpal tunnel syndrome). Skin color changes can give information about the current state of vascular supply of the hand and should always be observed. Hyperemia may be a result of bacterial infection, dry and shiny skin may occur with systemic diseases such as scleroderma, and hyperpigmentation of palmar furrows is seen in hyperaldosteronism. Hypo/hyperpigmentation plus hypertrichosis and dry skin may be signs of loss of nerve function of the hand.

Inspection of the fingernails can also provide information about systemic disorders. Hollow nails suggest iron deficiency anemia. Clubbing is usually a sign of lung disorders but can also be seen in inflammatory bowel diseases, cirrhosis, etc.

Posterolateral swelling of distal interphalangeal fingers due to arthritis in postmenopausal women is observed and called as Heberden's nodes; the same pathology at proximal interphalangeal joints is called as Bouchard's nodes [6, 7] (Figs. 2.1 and 2.2).

In addition to individual swelling of finger joints, bilateral symmetrical swelling of especially metacarpophalangeal and proximal interphalangeal joints is an early sign of chronic inflammatory disorders especially rheumatoid arthritis [4]. Swelling can be accompanied by tenosynovitis, by effusions, and, in chronic conditions, by characteristic finger deformities which are:

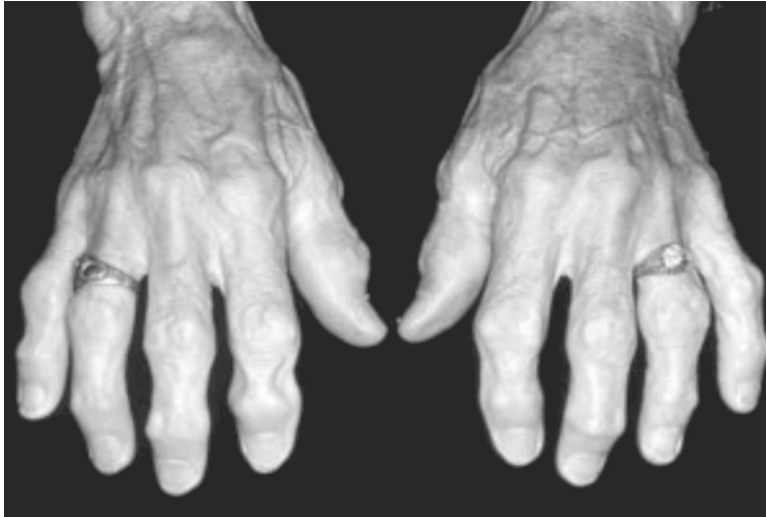- Swan neck deformity: flexion of metacarpophalangeal and distal interphalangeal joints and hyperextension of proximal interphalangeal joints
- Boutonniere deformity: flexion of proximal interphalangeal joint, extension of distal interphalangeal joint of fingers and flexion of mcp, extension of interphalangeal joint of thumb (Fig. 2.3)

Other deformities such as congenital ones should also be noted. Most frequently seen congenital anomaly is polydactyly and the second one is syndactyly. These congenital deformities may be hereditary or exogenous in origin.

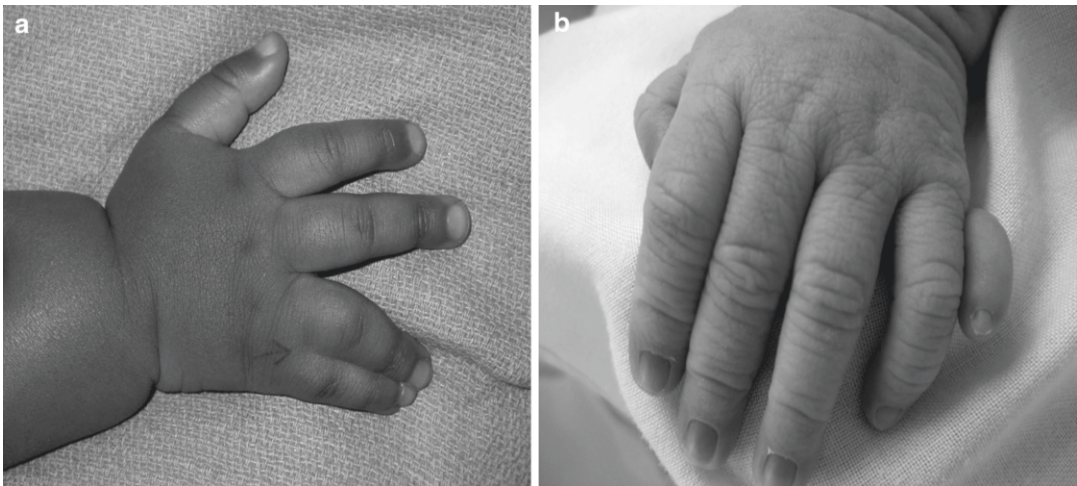---

## Palpation

Palpation is a complementary component of examination after inspection. What is seen with inspection is evaluated in more detail with palpation. Palpation includes not only soft tissue, bone, and joints of the hand but also the whole upper extremity for a thorough examination. Skin surface texture evaluation is important. The hand must be checked whether it is hot or cold, dry or moist, and smooth or rough and if there is any swelling; it should also be checked for its properties – fluctuant or fixed and soft or hard – for its dimensions and accompanying skin color changes, and for any tender points with palpation. Distal pulses are also important as they give idea about current blood supply of the hand. Palpation of major landmarks of the hand is important to make the differentiation between normal and pathological conditions.



**Fig. 2.1** Posterolateral swelling of distal and proximal interphalangeal joints due to osteoarthritis, Heberden and Bouchard nodes, respectively (Received from the [www.healthinplainenglish.com](http://www.healthinplainenglish.com) web site in 12.10.2010)



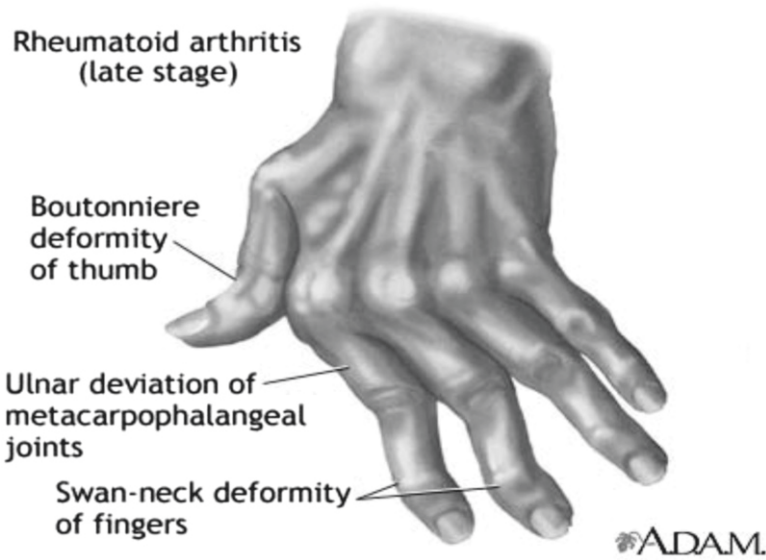
**Fig. 2.2** Congenital deformities of the hand. (a) Syndactyly on the *left* and (b) polydactyly on the *right* (Received from the [img.medscape.com/farm3.static.flickr.com](http://img.medscape.com/farm3.static.flickr.com) web site in 12.10.2010)

## Radial Styloid

This is an easily palpable and important landmark for palpation of the wrist. Tenderness at this point in postmenopausal women may indicate fracture which is usually called Colles fracture or rarely tendinitis of brachioradialis muscle which occasionally occurs in athletes performing back-hand motions [3].

## Anatomical Snuffbox and Scaphoid

Anatomical snuffbox is located distal to the radial styloid process and between abductor pollicis longus and extensor pollicis longus. It is an important landmark in two ways: First of all, radial artery passes through this hollow and can be injured in traumas to this anatomical place. Secondly, scaphoid is palpable on the floor of the hollow.



**Fig. 2.3** Characteristic finger deformities of chronic inflammatory disease of the hand (Received from the [www.clarian.org](http://www.clarian.org) web site in 12.10.2010)

Tenderness in this area usually indicates a scaphoid fracture which is the most frequently fractured carpal bone (Fig. 2.4).

### Trapezium and the Base of the First Metacarpal

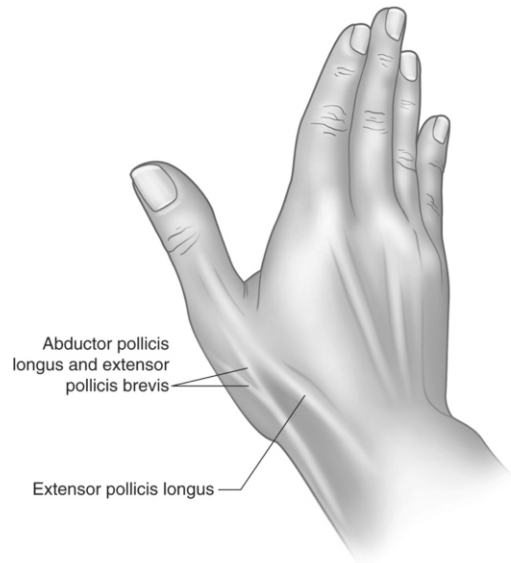
Trapezium is palpable just distal to scaphoid. Palpation of this area will be painful especially in degenerative osteoarthritis of the hand.

### Capitate

Capitate is palpable proximal to the largest and most prominent of all metacarpal bases, the third metacarpal.

### Lunate and Lister's Tubercle

Lister's tubercle lies on the dorsal aspect of the distal radius directly in line with the third metacarpal. Lunate is located distally to Lister's tubercle and prone to dislocation, fracture, and



**Fig. 2.4** Anatomical snuffbox of the hand. It is located distal to radial styloid between abductor pollicis longus and extensor pollicis longus tendons

avascular necrosis. Tenderness in this area especially with the wrist motion is an important indicator of lunate damage.

## Ulnar Styloid

Ulnar styloid is another important and easily palpated anatomical landmark. The pain of flexor carpi ulnaris tendinitis is usually located in this area. This styloid process is also vulnerable to the traumatic injuries especially falls.

## Triquetrum and Pisiform


Triquetrum is distal to ulnar styloid, and pisiform is distal to triquetrum. Flexor retinaculum, extensor retinaculum, abductor digiti minimi, and fibrous complex of ulnocarpal compartment insert to pisiform.

## Hamate and Guyon's Canal

Hamate is located distally to pisiform, but it is difficult to palpate, because it lies deep in the hand and is covered by soft tissues. Guyon's canal is between the hook of hamate and pisiform, and it is an important anatomical structure because ulnar artery and nerve pass through, and it is prone to compression with acute or chronic trauma.

## Assessment of Range of Motion

Range of motion assessment is an essential component of hand function evaluation. Limitation of the motions severely impairs hand function. This is why thorough evaluation of range of motion of each joint carries great importance. Range of motion evaluation can be elicited with or without goniometry. However, using goniometry improves reliability of measurements although there is not much literature supporting this statement [8]. It was found that intra-observer reliability is high [8, 9]. Intra-observer reliability is higher than interobserver reliability, but several measurements should be taken by the same examiner. Placing the goniometer dorsally or laterally has equal reliability [10], and each technique can be used in order to measure range of motion (Fig. 2.5).



**Fig. 2.5** Hand goniometer (Received from the [http://www.bpp2.com/physical\\_therapy\\_products/1310.html](http://www.bpp2.com/physical_therapy_products/1310.html) web site in 12.10.2010)

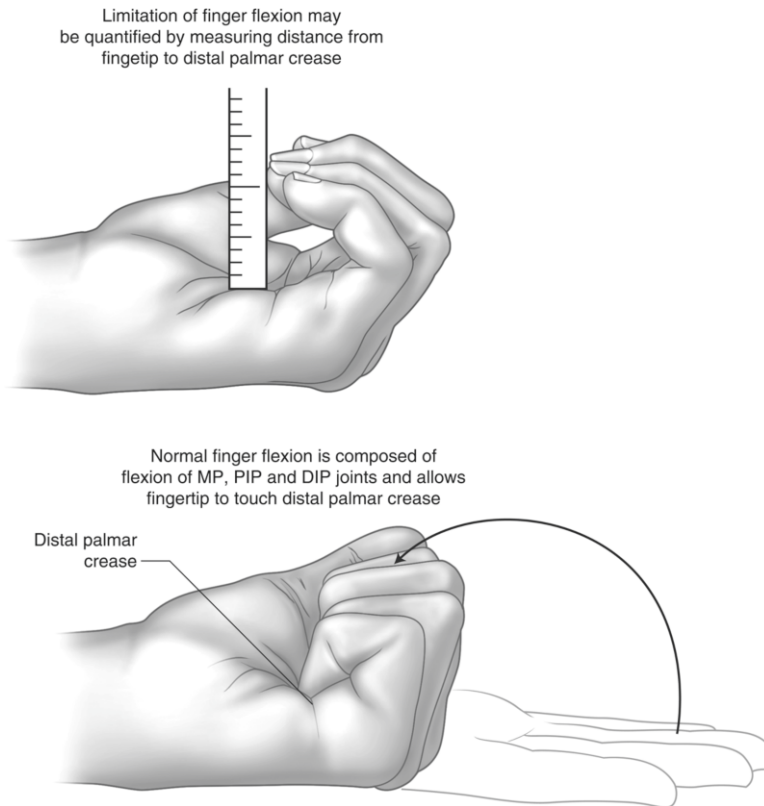
Range of motion evaluation involves active and passive motion measurements. Initially active range of motion and then passive range of motion are evaluated. Active motion refers to the motion achieved by patient's own muscle power. Passive motion refers to the freedom of motion of a joint when an external force is applied. If the patient is capable of doing full range of active motion, passive range of motion evaluation will not be necessary. Flexion is evaluated with the hand in "fisted" position (maximal metacarpophalangeal, proximal interphalangeal, distal interphalangeal flexion), and extension is evaluated with all these three joints in full extension [11].

Total motion values allow one number to represent the total motion capacity of a finger. In order to estimate this number, total extension deficits, including hyperextension, are added together, and the sum is subtracted from total flexion capacity. Passive range of motion tells us if the joint is stiff or not, whereas total passive motion indicates as a functional unit finger lacks motion. Another technique that evaluates lack of overall finger flexion is measuring the distance between the finger pulp and distal palmar crease while the hand is in fisted position. This is an easier way to evaluate finger flexion deficit and more comprehensible in the clinic [11] (Fig. 2.6).

## Range of Motion of the Wrist

Measuring rotational movements of radioulnar joint is difficult because of long axis of the movement and lack of anatomical lever arms. In order





**Fig. 2.6** Overall finger flexion measurement. To evaluate overall finger flexion, the distance between finger pulp and distal palmar crease is measured with the hand in fist position

to make the correct measurement, the patient may be sitting or standing, but the elbow must be flexed  $90^\circ$  with the arm and must be close to the side of the body. The forearm should be in mid-position defined as “0°” [11].

### Supination

For supination the patient rotates the forearm to its maximum palm-up position. Stationary arm of the goniometer is placed along the humeral shaft and movable arm across the volar aspect of the wrist at the level of ulnar styloid. Normal range of motion of supination is  $0^\circ$ – $80^\circ/90^\circ$  [11].

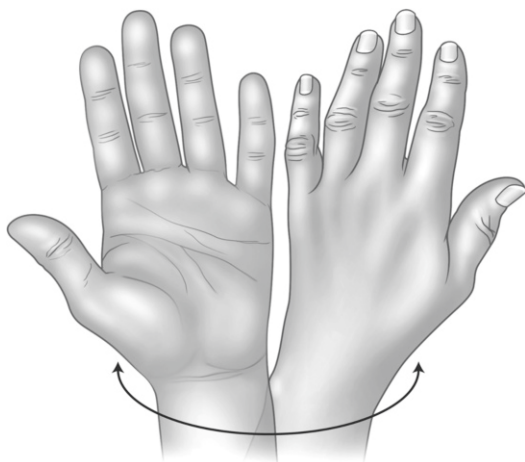
### Pronation

Starting position for pronation is the same as for supination, but this time the patient rotates the

forearm into maximum palm-down position. The goniometer is placed similarly as for the supination measurement. The only difference is the change of position of the hand. Normal range of pronation of the wrist is  $0^\circ$ – $80^\circ/90^\circ$  [11] (Fig. 2.7).

### Flexion

For assessing flexion range of motion of the wrist, the goniometer can be placed laterally or dorsally. For lateral placement the goniometer is placed along the radial border of the forearm and the second metacarpal bone. The elbow must be in flexed position, and the forearm and wrist must be in neutral position. When the wrist is flexed, the stationary arm of goniometer is placed along the radius, and the movable arm



**Fig. 2.7** Pronation and supination of the wrist. Normal range of pronation and supination of the wrist is  $0^{\circ}$ – $80^{\circ}/90^{\circ}$

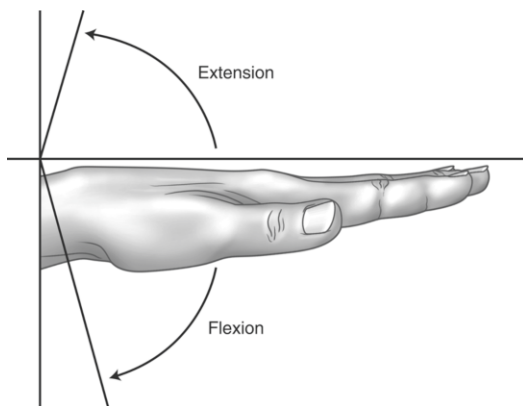
is placed along the second metacarpal bone. Axis of goniometer is placed approximately at the level of radius. Wrist flexion with the goniometer placed dorsally requires elbow flexion, forearm pronation, and the wrist in neutral position. The stationary arm is placed along the forearm and the movable arm along the third metacarpal. Normal range of flexion of wrist is  $0^{\circ}$ – $80^{\circ}$  [11].

### Extension

Starting position for wrist extension measurement is the same as for wrist flexion. After proper positioning, the wrist is extended maximally; fingers can be allowed to flex passively. The stationary arm of goniometer is placed along the long axis of the forearm, and the movable arm is placed along the long axis of the third metacarpal on the volar surface. Normal range of motion for extension of wrist is  $0^{\circ}$ – $70^{\circ}$  [11] (Fig. 2.8).

### Radial/Ulnar Deviation

Assessment of radial and ulnar deviation of the wrist is elicited by the wrist in neutral position and the forearm in pronation. The goniometer is placed in mid-position dorsally. The movable arm of goniometer is placed along the long axis of third metacarpal bone. Then the wrist is angled towards the thumb and little finger for radial and



**Fig. 2.8** Flexion and extension range of the wrist. Normal range of flexion wrist is  $0^{\circ}$ – $80^{\circ}$ . And normal range of extension of the wrist is  $0^{\circ}$ – $70^{\circ}$

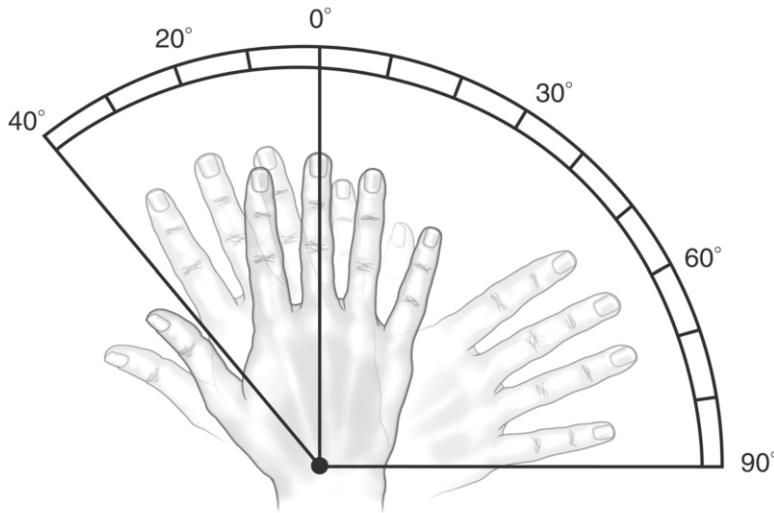
ulnar deviation, respectively. Normal range of radial deviation is  $0^{\circ}$ – $20^{\circ}$ , and ulnar deviation is  $0^{\circ}$ – $30^{\circ}$  [11] (Fig. 2.9).

## Range of Motion of Fingers

In order to assess range of motion of fingers thoroughly, the wrist must be in neutral position to allow tendon excursion of long flexors and extensors of the fingers. Flexion of one finger is measured by maximally flexing the other three fingers, and extension of one finger is measured by maximally extending the other three fingers actively.

### Metacarpophalangeal (MCP) Joint

Lateral or dorsal placement of the goniometer is possible for assessing MCP joint motion. Usually dorsal placement is preferred because it is easier to apply. In dorsal placement, the stationary arm of goniometer is placed over the dorsum of metacarpal bone (MC), and the movable arm is placed along the long axis of proximal phalanx. In lateral placement, the stationary arm of goniometry is placed on the longitudinal axis of MC, and the movable arm is placed on the longitudinal axis of the proximal phalanx. For the second and third fingers, the goniometer is placed on the radial side of the fingers, and for the fourth and fifth fingers, the goniometer is



**Fig. 2.9** Radial and ulnar deviation of the wrist. Normal range of radial deviation is  $0^{\circ}$ – $20^{\circ}$  and ulnar deviation is  $0^{\circ}$ – $30^{\circ}$

placed on the ulnar side of the fingers. Normal range of motion of MCP is  $0^{\circ}$ – $90^{\circ}$ , but hyperextension up to  $45^{\circ}$  is possible and considered to be in normal ranges [11].

### Flexion and Extension of Proximal and Distal Interphalangeal (DIP) Joints

Dorsal and lateral placement of the goniometer is possible. Measurement technique of PIP and DIP is quite similar, so they will be discussed together. For lateral placement, the stationary arm is placed along the long axis of proximal phalanx, and the movable arm is placed along the long axis of adjacent distal phalanx. The positioning of the goniometer is the same for both flexion and extension. Dorsal placement of the goniometer is the same as for lateral placement except that it is placed dorsally. Normal range of motion of PIP is  $0^{\circ}$ – $110^{\circ}$  and DIP is  $0^{\circ}$ – $60^{\circ}/70^{\circ}$  [11].

### Abduction and Adduction of MCP Joint

There is not a standardized technique to measure finger abduction and adduction in exact means. Finger abduction is assessed by measuring the distance between two adjacent abducted fingers.

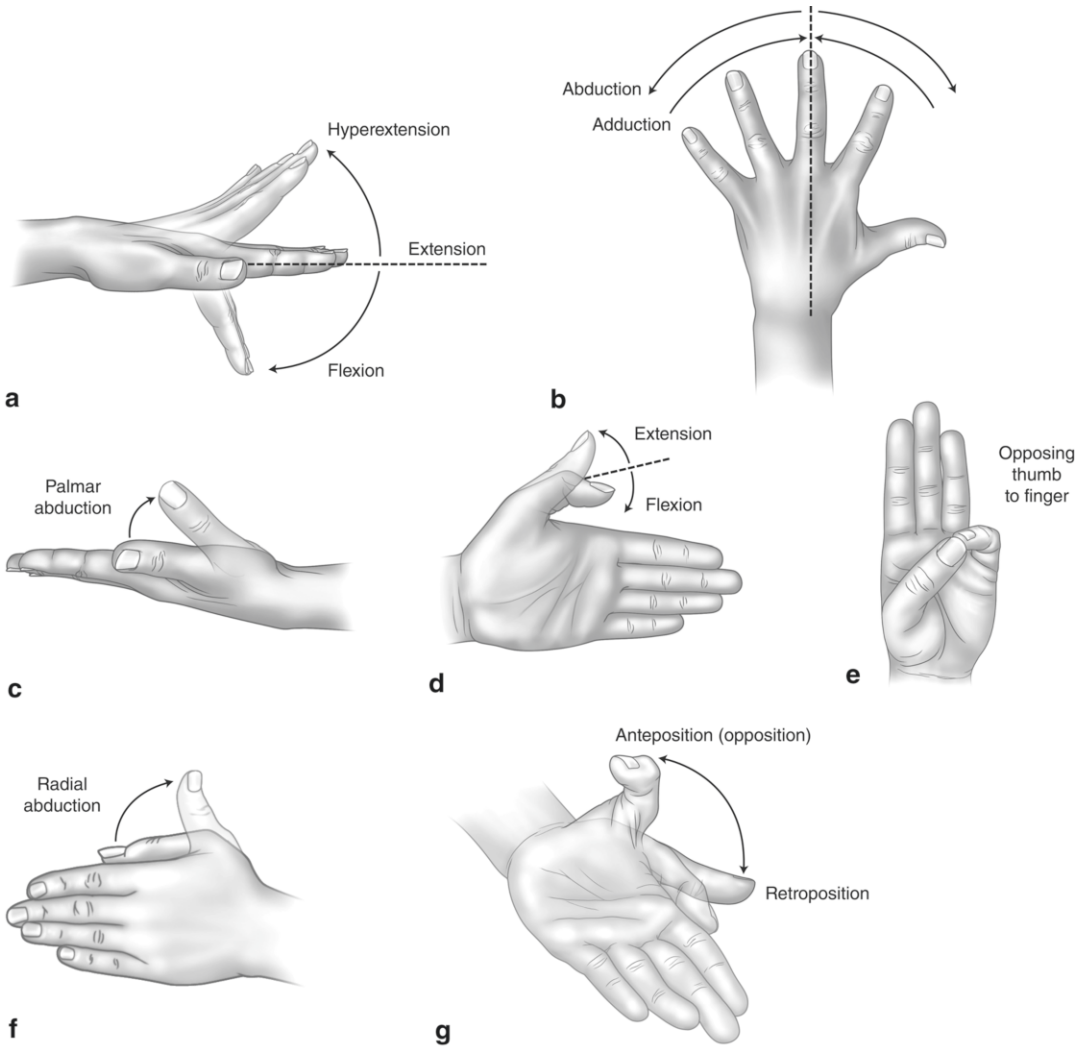
It gives only an estimated and not a standard value, and it is only used to follow up the treatment [11].

### Thumb Motions

The thumb has the most complex movement pattern along all other digits. This is why its movement patterns are described separately.

Flexion of the thumb is the movement of the thumb against the base of the fifth finger across the plane of the palm, and it involves the flexion of carpometacarpal (CMC), metacarpal (MC), and interphalangeal (IP) joints. Extension of the thumb is the movement of the thumb away from the second finger across the plane of the palm. Flexion and extension of the thumb can be measured by placing the stationary arm of goniometer along the long axis of the radius and movable arm along the long axis of the first MC. Flexion of CMC joint is  $15^{\circ}$ . Extension of CMC joint is measured by placing the stationary arm of goniometer on the second MC and the movable arm on the first MC. MCP and IP joint flexion and extension assessment technique is the same as for the other fingers [11].





**Fig. 2.10** In (a) and (b) MCP joint motions are illustrated. Figures from (c)–(g) thumb motions are illustrated

Abduction of the thumb is the movement of the thumb perpendicular to the palm and only involves CMC joint motion and so as adduction. Abduction of the thumb is measured by placing the stationary arm of goniometer on the second MC and the movable arm on the first MC. However, according to de Kraker et al. [12] pollexograph-thumb, pollexograph-metacarpal, and the Inter Metacarpal Distance measurements are the most reliable measurement methods for palmar abduction of the thumb in adults; these measurements are also

found to be reliable in children [13]. In adduction, the thumb lies adjacent to the long axis of radius and beside the second MC.

Opposition of the thumb involves multiple thumb movements which are flexion, rotation, and abduction. In order to elicit exact opposition, the thumb should move to abduction first; otherwise, it would be just flexion. Measurement is done by measuring the distance between the tip of the fifth finger and the tip of thumb in opposed position [11] (Fig. 2.10).

## Neurologic Examination

### Muscle Strength Evaluation

Motor function evaluation of the hand is important and necessary especially in muscle/tendon injury and peripheral or central nerve lesions. In order to make a thorough motor examination of the muscle or muscle group, compensatory movements which can compromise the functions of the muscles being examined should be avoided. For example, failure of dorsal interossei muscle function can be masked by function of finger extensors if the test is done with MCP joints in hyperextension. Muscle strength is evaluated according to muscle strength scale of Medical Research Council [14] (Table 2.1).

### Wrist Extension

Wrist extensors consist of extensor carpi radialis longus (radial nerve, C6–C7), extensor carpi radialis brevis, and extensor carpi ulnaris (radial nerve, C7). These are the primary extensors of the wrist. However, extensor digitorum superficialis, extensor digiti minimi, and extensor indicis proprius also contribute to wrist extension. In order to rule out the contribution of secondary extensors of the wrist, the forearm is stabilized with the other hand, and the patient is instructed to make a fist. Then force is applied and the patient is instructed to extend the wrist against resistance.

### Wrist Flexion

Primary flexors of the wrist are flexor carpi radialis (median nerve, C6–C8) and flexor carpi ulnaris (ulnar nerve, C8–T1). Flexor carpi ulnaris is the strongest wrist flexor. Flexor pollicis longus, palmaris longus, and deep and superficial finger flexors also contribute to wrist flexion as secondary flexors. In order to rule out the effect of secondary flexors, hand is clenched in fist position again. After stabilizing the forearm the patient is instructed to flex the wrist against resistance.

### Ulnar Deviation of the Wrist

Ulnar deviation of the wrist is accomplished by flexor carpi ulnaris (ulnar nerve, C8–T1). In order to evaluate ulnar deviation of the wrist,

**Table 2.1** Medical research council (MRC) scale for muscle strength

The patient's effort is graded on a scale of 0–5:
• Grade 5: Muscle contracts normally against full resistance
• Grade 4: Muscle strength is reduced, but muscle contraction can still move joint against resistance
• Grade 3: Muscle strength is further reduced such that the joint can be moved only against gravity with the examiner's resistance completely removed. As an example, the elbow can be moved from full extension to full flexion starting with the arm hanging down at the side
• Grade 2: Muscle can move only if the resistance of gravity is removed. As an example, the elbow can be fully flexed only if the arm is maintained in a horizontal plane
• Grade 1: Only a trace or flicker of movement is seen or felt in the muscle, or fasciculations are observed in the muscle
• Grade 0: No movement is observed

again the forearm is stabilized, and the patient is instructed to move his/her wrist to ulnar deviation against resistance.

### Radial Deviation of the Wrist

Flexor carpi radialis (median nerve, C6–C8) is the primary muscle for radial deviation. Radial deviation examination technique is similar with that of ulnar deviation except that the wrist is moved towards the radius.

### Finger Extension

Extensors of the fingers are extensor digitorum communis (radial nerve, C7–C8), extensor indicis proprius (radial nerve, C7–C8), and extensor digiti minimi (radial nerve, C7). In order to evaluate the function of primary finger extensors in isolation, the wrist and MCP joint should be in neutral position; proximal and distal interphalangeal joints should be in flexed position. If PIP and DIP joints are kept in extension, intrinsic muscles of the hand also contribute to finger extension. Extension of PIP and DIP joints can be tested by a flicking movement of the fingers.

### Finger Flexion

Finger flexors are flexor digitorum superficialis (median nerve, C7–C8), flexor digitorum pro-

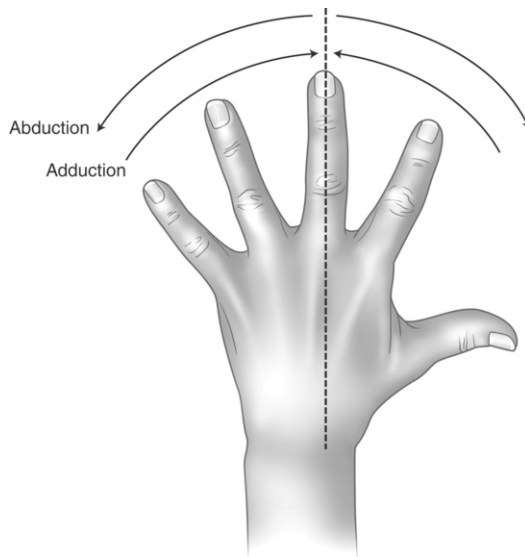
fundus (ulnar part of ulnar nerve, C8–T1; radial part of median nerve, C7–C8), and lumbricalis. Flexor digitorum superficialis muscle primarily flexes the PIP joint; flexor digitorum profundus primarily flexes the DIP joint, and lumbricalis primarily flexes the MCP joint. Total flexor strength of the fingers is tested by interlocking the fingers with the fingers of the patient in flexed position. Strength of each finger flexor should be tested separately in order to make the differential diagnosis. Tendon of the flexor digitorum superficialis inserts to the base of the middle phalanx. This is why in order to test the strength and function of this muscle in isolation, all of the fingers of the patient are held in extension except the finger to be tested. Then the patient is instructed to flex the PIP joint against resistance, while MCP is in neutral position and DIP is in extension. Tendon of the flexor digitorum profundus inserts to the base of the distal phalanx. In order to test its function, the patient is instructed to flex the DIP joint against resistance after stabilizing the PIP joint of the same finger in extension.

### Finger Abduction

Primary abductors of the fingers are dorsal interossei muscles (ulnar nerve, C8–T1) and abductor digiti minimi muscle (ulnar nerve, C8–T1). Extensor digitorum communis also contributes to abduction when the fingers are in extension. Strength of abduction of the fingers can be evaluated in two different ways. First, after the patient is instructed to abduct all the fingers simultaneously, force is applied to the second and fifth finger, and the patient is asked to resist the force applied. Secondly, the third finger can be tested in isolation by applying force against abduction (Fig. 2.11).

### Finger Adduction

Primary finger adductors are palmar interossei muscles (ulnar nerve C8–T1). Finger flexors contribute to adduction when fingers are flexed. In order to evaluate the function of finger adductors, you can try to separate extended and adducted fingers of the patient, testing two adjacent fingers simultaneously or you can apply the “paper test.” The patient is instructed to hold a paper tightly



**Fig. 2.11** Finger abduction strength can be tested by isolating the third finger and applying force against abduction

between the extended and adducted fingers, then try to pull the paper. If there is weakness of interossei muscles, the patient will not be able to resist or even not be able to hold the paper between the fingers. Always check the strength of the other hand for comparison.

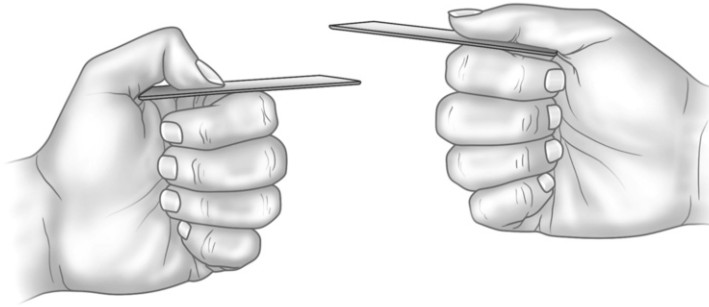
## Motor Functions of the Thumb

### Thumb Extension

Extensors of the thumb are extensor pollicis longus (radial nerve, C7) and extensor pollicis brevis (radial nerve, C7). Extensor pollicis brevis inserts to the base of the proximal phalanx and extends the proximal phalanx; extensor pollicis longus inserts to the base of the distal phalanx, and its contraction extends the distal phalanx. Thumb extension is the movement of the thumb away from second MC across the plane of the palm. Extensor muscle strength of the thumb is evaluated by extending the thumb of the patient against resistance.

### Thumb Flexion

Flexors of the thumb are flexor pollicis longus (median nerve, C8–T1) and flexor pollicis brevis



**Fig. 2.12** Froment's sign. If there is weakness in adductor pollicis, flexors of the thumb will aid holding the paper, and flexion of distal phalanx will be observed

(deep part of ulnar nerve, C8; superficial part of median nerve, C6–C7). Flexor pollicis longus inserts to the base of the distal phalanx and flexes the distal phalanx; flexor pollicis brevis inserts to the base of the proximal phalanx and flexes the proximal phalanx. Flexion of the thumb is the movement of the thumb towards the fifth finger in the plane of the palm. Flexion function is evaluated by applying force to the thumb in flexed position.

### Thumb Abduction

Abduction of the thumb is achieved by abductor pollicis longus (radial nerve, C7) and abductor pollicis brevis (median nerve, C6–C7). Abduction of the thumb is the movement of the thumb perpendicular to the palm and evaluated by abducting the patient's thumb against resistance. If there is a weakness of abductor muscles, especially of abductor pollicis brevis, the patient will not be able to bring the web space between the first and second fingers in contact with when holding a bottle, and there will be a gap between the web space and the bottle. This sign is called as "Lüthy bottle sign" [3].

### Thumb Adduction

There is a single adductor of the thumb which is adductor pollicis (ulnar nerve, C8). Adductor pollicis consists of two heads which are oblique and transverse heads. In order to evaluate adduction of the thumb, the patient is instructed to hold a paper between the ulnar side of the thumb and radial side of the second finger in extended position against resistance. If there is weakness in

adductor pollicis, flexors of the thumb will aid holding the paper, and flexion of distal phalanx will be observed. This sign is called as "Froment's sign" (Fig. 2.12).

### Opposition of the Thumb and Little Finger

Opposition is the function of both the thumb (opponens pollicis: median nerve, C6–C7) and the little finger (opponens digiti minimi: ulnar nerve, C8). Opposition involves abduction, flexion, and rotation of the thumb [15]. Force is applied to each of the opposing fingers using both hands in order to evaluate the function. If there is weakness of opponens pollicis, the thumb will be easily separated from the pulp of the little finger.

### Pinch Function of the Thumb

Pulp to pulp pinch is achieved by the contraction of flexor pollicis longus and second flexor digitorum profundus. If these muscles have normal function, the patient will be able to form an "O" shape with the thumb and second finger. If there is weakness of these muscles (anterior interosseous nerve syndrome), distal phalanx of the thumb and second finger will not be able to flex and remain in extension, and the patient will not be able to form an "O" (Fig. 2.13).

### Pinch and Grip Strength

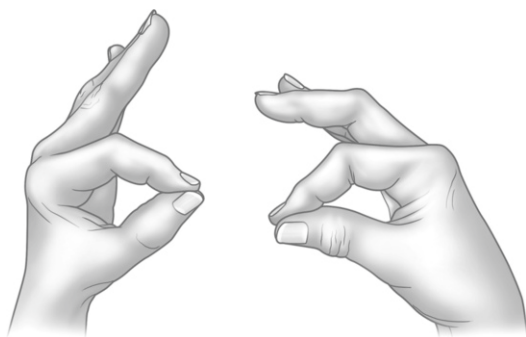
*There are actually three different types of pinch:*

- Lateral or key pinch
- Tip-to-tip pinch
- Three-fingered pinch or three-point chuck

Lateral pinch is the strongest type of pinch followed by three-point pinch. Tip-to-tip pinch is used for more sophisticated processes requiring fine coordination. Pinch function of the hand is tested with a pinchmeter. Average of three trials is recorded (Figs. 2.14 and 2.15).

*There are several devices to measure gross grip strength.*

Jamar dynamometer developed by Bechtol [16] has been shown to be a reliable test providing that the calibration is maintained [17, 18]. The dynamometer has five adjustable spacings which are 1, 1<sup>1/2</sup>, 2, 2<sup>1/2</sup>, and 3 in.. Measurement is taken from all of these spacings after the patient is instructed to grasp the dynamometer with maximum strength. Three measurements are taken, and the mean value of these three trials is recorded. Usual grip strength makes a bell-shaped curve,



**Fig. 2.13** Pinch function of the thumb. If there is weakness of flexor pollicis longus or second flexor digitorum profundus, the patient will not be able to form an “O”

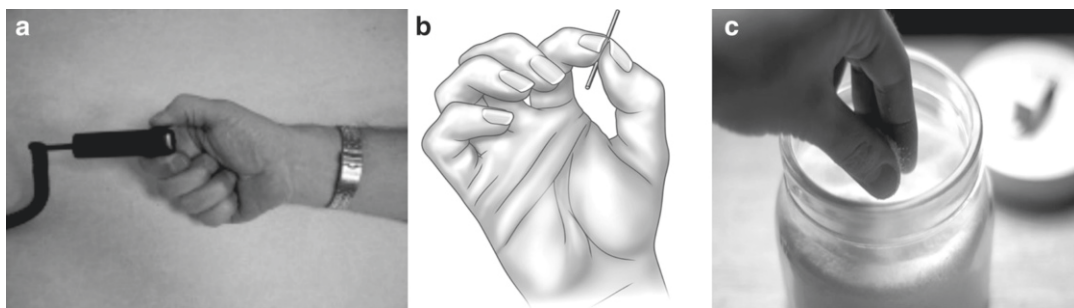
being the middle spacings the stronger and weakest at each ends. Both right and left hands are evaluated. There is usually 5–10 % difference between the dominant and nondominant hand, usually the dominant hand being the stronger (Fig. 2.16).

## Sensory Function Evaluation

Sensory innervation of the upper extremity follows spinal nerve roots, plexus, and peripheral nerves. If the lesion is not central in origin, sensory deficits also follow the innervation pattern of the peripheral nerves. Evaluation of sensory function of the upper extremity is usually limited to light touch and pain sensation. Evaluation of the other sensory functions is usually unnecessary and useless. There are several instruments available to test two-point discrimination, but sensitivity and reliability of these instruments are low when applied in the hand. Light touch sensation is examined with a cotton swab or with the tip of the finger. Variations of sensorial nerve supply on the overlapping dermatomal areas should also be taken into consideration.

Sensory innervation of the hand is mainly supplied by three peripheral nerves which are radial nerve, median nerve, and ulnar nerve (Fig. 2.17).


Radial nerve innervates only the dorsal part of the hand and fingers. Its innervation area involves two and a half finger of the dorsum of the hand (thumb, index, and radial half of the



**Fig. 2.14** (a) Lateral pinch, (b) tip-to-tip pinch, and (c) three-point pinch (Received from the <http://www.sim-work.com/products/sapphire/images/LateralPinch200x150.jpg>, <http://web.student.tuwien.ac.at/~e0227312/>

[images\\_grasps/i\\_24\\_1, http://www.apartmenttherapy.com/uimages/kitchen/2009-07-16-ThreeFingerPinch.jpg](http://www.apartmenttherapy.com/uimages/kitchen/2009-07-16-ThreeFingerPinch.jpg), web sites in 15.10.2010)





**Fig. 2.15** Pinchmeter (Received from the [http://www.griprepair.com/images/baseline\\_pinchmeter.jpg](http://www.griprepair.com/images/baseline_pinchmeter.jpg) web site in 15.10.2010)



**Fig. 2.16** Jamar dynamometer (Received from the [http://www.bpp2.com/Merchant2/graphics/00000001/2006CAT/2006CATP50/JAMAR\\_HAND\\_DYNA\\_L.jpg](http://www.bpp2.com/Merchant2/graphics/00000001/2006CAT/2006CATP50/JAMAR_HAND_DYNA_L.jpg) web site in 15.10.2010)

middle finger) up to distal phalanges and radial side of the dorsum of the hand.

The ulnar nerve innervates the palmar side of one and a half finger (little finger and ulnar half of the ring finger) and dorsal side of two and a half finger (little finger, ring finger, and ulnar half of the middle finger) and adjacent skin area of the hand.

The median nerve innervates the palmar side of three and a half finger (thumb, index finger, middle finger, and radial half of the ring finger)

and adjacent skin area and dorsal side of the distal phalanges of the index and middle finger.

There are several tests available to assess sensibility and dexterity of the hand:

- Semmes-Weinstein filament test
- Moberg's pick-up test [19],
- Seddon's coin test, the moving two-point discrimination test described by Dellon, and Weber's two-point discrimination test.

But reliability of all these tests still remains controversial because volitional participation of the patient is required. As a result these are rather subjective tests than being objective.

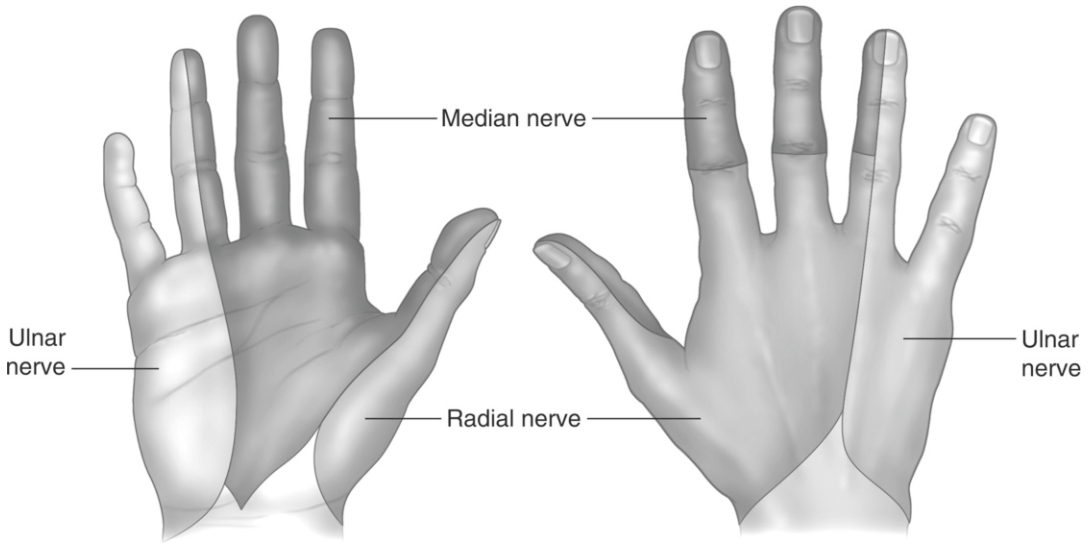
Semmes-Weinstein monofilaments are shown to produce consistently repeatable forces from set to set and from examiner to examiner, and it is possible to control the amount of force applied [15, 20]. Thus, these monofilaments prove the most sensitive and reliable data among all other clinical sensibility assessment instruments [8, 20, 21]. Originally, there are 20 monofilaments, but now there is also a 5-filament mini set available for practical use. Using Semmes-Weinstein monofilaments, the normal touch threshold is approximately  $4.86 \text{ g/mm}^2$ .

---

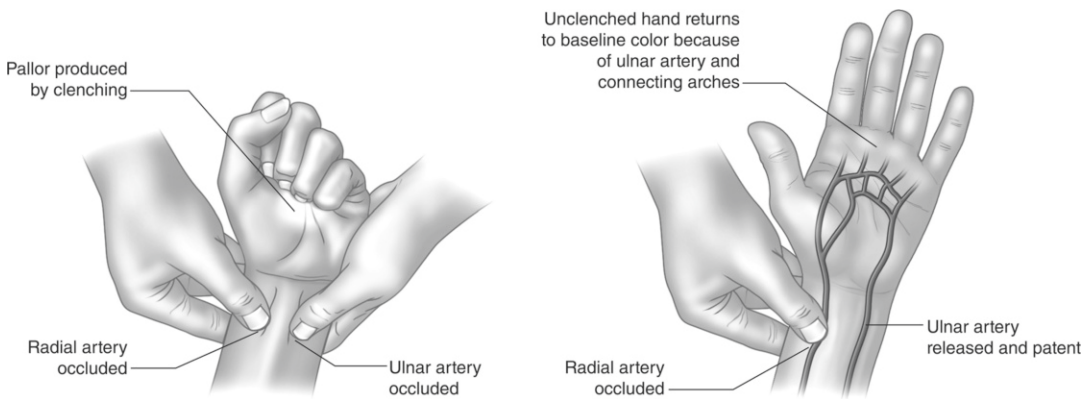
## Evaluation of Vascular Supply of the Hand

Ulnar and radial arteries are vascular supply of the hand. *Allen's test* is a simple test to evaluate vascular supply of the hand and it is easy to apply. Allen first described this test in 1929, but did not mention a time period that the test will be considered





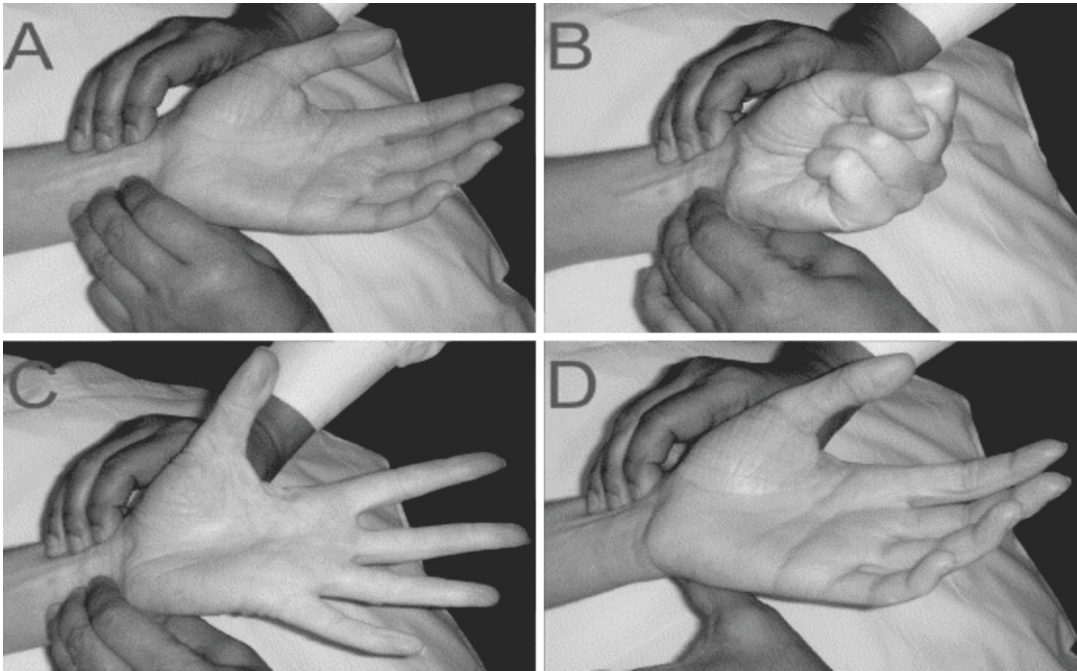
**Fig. 2.17** Sensory innervation of the hand



**Fig. 2.18** Classical Allen's test

as positive. In time, various time periods are mentioned from 5 to 15 s. Classic Allen's test is applied by compressing the patient's ulnar and radial arteries using the thumb, index, and middle finger of each hand. Then the patient is instructed to open and close his fist in order to drain venous blood of the hand. After repeating it several times, the patient is instructed to open his fist, and it will be observed that the hand becomes pale. Then the compression on one of the arteries is removed, and the hand is observed if it becomes pink again. The same process is repeated for the other artery. If one of the arterial supplies is occluded or somehow disrupted partially or totally, the hand will remain

pale or will gain its color slower than expected after removing the compression. Allen's test should be applied to both of the hands in order to make comparison. If the hand does not become pale, the presence of a variant artery should be considered. In 2007 a new version of Allen's test is described [22]. This test is applied by compressing radial and ulnar arteries with three digits using both hands. Then the patient is instructed to clench and unclench the hand ten times and then to open the palm. After that the ulnar or radial artery is released, and flushing is observed. If flushing delays more than 6 s, the test is considered to be positive (Figs. 2.18 and 2.19).



**Fig. 2.19** Modified Allen's test. Reprinted from *The Annals of Thoracic Surgery*, 84, Mohammed Asif, Pradip K. Sarkar, Three-Digit Allen's Test, 686–7, Copyright (2007), with permission from Elsevier

## Specific Tests

### Carpal Tunnel Syndrome: Tinel's Sign

This is one of the tests applied if the patient is suspected to have carpal tunnel syndrome which is characterized by compression of the median nerve in the carpal tunnel. The test is considered to be positive if the patient feels paresthesia with tapping on the median nerve where it is suspected to be compressed. However, this test can be false negative in the presence of chronic nerve compression or severe reduction in nerve conduction.

### Carpal Tunnel Syndrome: Phalen's Test

This is another test used to evaluate carpal tunnel syndrome. Here, the patient is instructed to maximally flex or extend his wrist and wait for a few minutes in that position. The test is considered to be positive if the patient feels paresthesia after several minutes of sustained position. Both

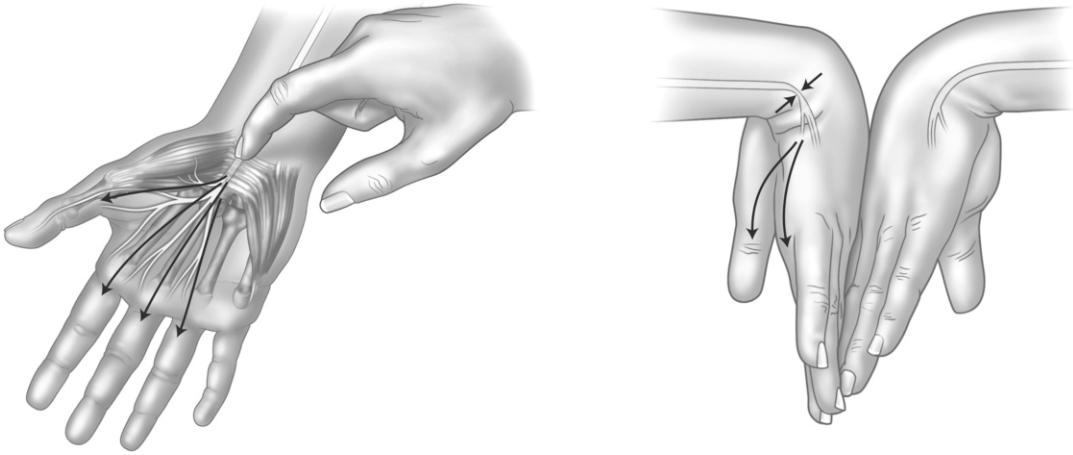
Tinel's sign and Phalen's test with the history are 80 % diagnostic for carpal tunnel syndrome. Electrodiagnostics are ancillary tools for confirming the diagnosis [2] (Fig. 2.20).

### Wartenberg's Syndrome: Tinel's Sign

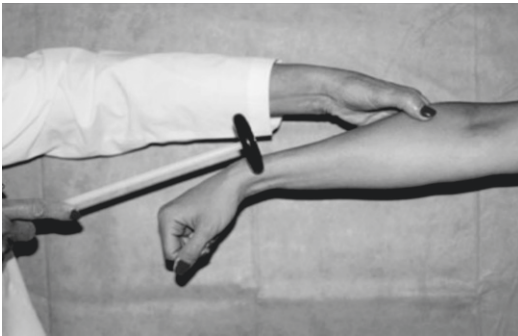
Wartenberg's syndrome is the compression of the superficial branch of the radial nerve in the distal portion of the brachioradialis tendon. Test is considered to be positive if the patient feels paresthesia with tapping the nerve in the distal portion of the brachioradialis muscle (Fig. 2.21).

### Proximal and Distal Ulnar Nerve Compression Syndrome: Tinel's Sign

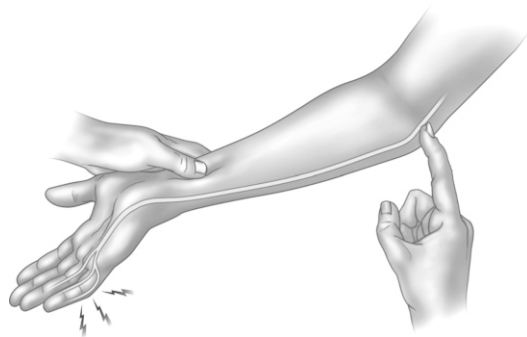
Ulnar nerve can be compressed either proximally at the level of medial epicondyle or distally in the Guyon's canal. Tinel's test can be applied for both of these locations. Also, scratch collapse test is a sensitive test that localizes Osborne's Band in cubital tunnel syndrome [23].



**Fig. 2.20** Tests applied in carpal tunnel syndrome. Tinel's test is illustrated on the *left*, and Phalen's test is illustrated on the *right* (Received from the <http://www.healthtopicsbysusan.com/?p=48> web site in 15.10.2010)



**Fig. 2.21** Tinel's test in the Wartenberg's syndrome (Received from the <http://img.medscape.com/fullsize/migrated/408/540/mos5854.01.fig6.jpg> web site in 15.10.2010)



**Fig. 2.22** Ulnar nerve compression test: Tinel's test

Distal branch of the ulnar nerve can be compressed in the Guyon's canal. Because the ulnar nerve has only motor fibers in this region, clinical outcome will be only motor paresis without loss of sensation (Fig. 2.22).

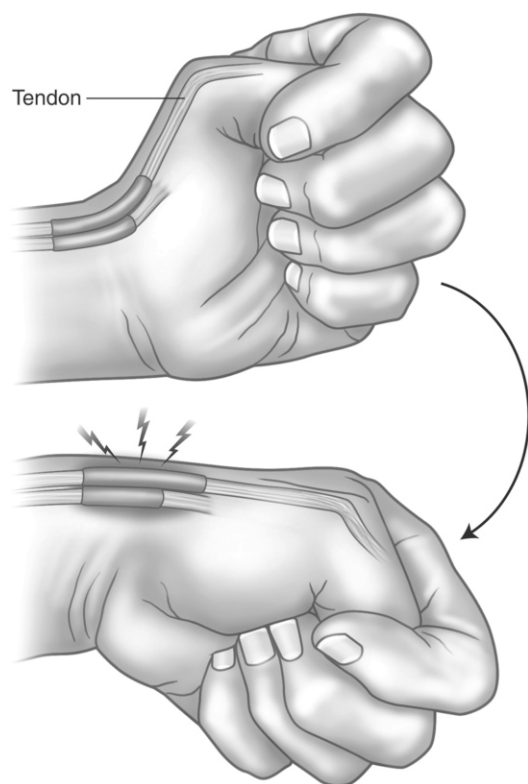
### Finkelstein Test

This test is used to demonstrate De Quervain's tendinitis which is the stenosing tenosynovitis of the first dorsal compartment of the hand. The patient is instructed to adduct his thumb towards the little finger. Then, the other fingers are flexed covering the adducted thumb. Next, the

patient's hand is moved towards ulnar deviation. The test is considered to be positive if the patient feels pain when the wrist is moved to ulnar deviation (Fig. 2.23).

### Summary

Thorough physical examination of the hand is crucial in the assessment of hand functions. In this chapter, physical examination of the hand including general inspection, palpation, range of motion assessment of each joint, neurologic



**Fig. 2.23** Finkelstein's test applied in the stenosing tenosynovitis of the first dorsal compartment of the hand

examination, specific tests for the common hand pathologies, and evaluation of the hand's vascular supply are reviewed in details.

## References

1. Yalinay Dikmen P, Oge AE, Yazici J. Short segment incremental study in ulnar neuropathy at the wrist: report of three cases and review of the literature. *Acta Neurol Belg.* 2010;110(1):78–83.
2. Graham B. The value added by electrodiagnostic testing in the diagnosis of carpal tunnel syndrome. *J Bone Joint Surg.* 2008;90(12):2587–93.
3. Castro WH, Jerosch J, Grossman TW. Examination and diagnosis of musculoskeletal disorders. New York, NY: Thieme; 2001.
4. Finney A, Thwaites C. Rheumatoid arthritis.1: background, symptoms and ensuring prompt diagnosis and treatment. *Nurs Times.* 2010;106(9):22–4.
5. Gautschi OP, Land M, Hoederath P, Fournier JY, Hilderbrandt G, Cadosch D. Carpal tunnel syndrome—modern diagnostic and management. *Praxis (Bern 1994).* 2010;99(3):163–73.
6. Zhang V, Doherty M, Leeb BF. Eular evidence based diagnosis of hand osteoarthritis - report of a task force of the EULAR standing committee for international clinical studies including therapeutics (ESCISIT). *Ann Rheum Dis.* 2009;68(1):8–17.
7. Van Linthoudt D. Clinical presentation imaging and treatment of digital osteoarthritis. *Rev Med Suisse.* 2010;6(240):564–6. 568.
8. van de Pol RJ, van Trijffel E, Lucas C. Inter-rater reliability for measurements of passive physiological range of motion of upper extremity joints is better if instruments are used: a systematic review. *J Physiother.* 2010;56(1):7–17.
9. Ellis B, Bruton A. A study to compare the reliability of composite finger flexion with goniometry for measurements of range of motion in the hand. *Clin Rehabil.* 2002;16(5):562–70.
10. Carter TI, Pansy B. Accuracy reliability of three different techniques for manual goniometry for wrist motion, a cadaveric study. *J Hand Surg Am.* 2009;34(8):1422–8.
11. Hunter JM, Schneider LH, Mackin EJ, Callahan AD. Rehabilitation of the hand surgery and therapy. St. Louis, MO: C.V. Mosby Company; 1990.
12. de Kraker M, Selles RW. Palmar abduction measurements: reliability and introduction of normative data in healthy children. *J Hand Surg Am.* 2009;34(9):1704–8.
13. Goldberg AE, et al. Correlation of manual dexterity with USMLE scores and medical student class rank. *J Surg Res.* 2008;147(2):212–5.
14. [http://www.medicalcriteria.com/site/index.php?option=com\\_content&view=article&id=238:neuromrc&catid=64:neurology&Itemid=80\(=en](http://www.medicalcriteria.com/site/index.php?option=com_content&view=article&id=238:neuromrc&catid=64:neurology&Itemid=80(=en)
15. Collins S, Visscher P, Ce Vet HC. Reliability of the Semmes Weinstein monofilaments to measure coetaneous sensibility in the feet of healthy subjects. *Disabil Rehabil.* 2010;32:2019–27.
16. Lehman JB, Abreu BC. Evaluating the hand: issues in reliability and validity. *Phys Ther.* 1989;6(12):1025–33.
17. Moberg E. Objective methods for determining the functional value of sensibility in the hand. *J Bone Joint Surg.* 1958;40B:454.
18. Haward BM, Griffin MJ. Repeatability of grip strength and dexterity tests and effects of age and gender. *Int Arch Occup Environ Health.* 2002;75(1–2):111–9.
19. Stamm TA, Ploner A, Machold KP, Smolen J, Moberg picking-up test in patients with inflammatory joint diseases: a survey of suitability in comparison with Button test and measures of disease activity. *Arthritis Rheum.* 2003;49(5):626–32.
20. Feng Y, Schlösser FJ. The Semmes Weinstein monofilament examination as a screening tool for diabetic peripheral neuropathy. *Vasc Surg.* 2009;50(3):675–82.
21. Jerosch-Herold C. Assessment of sensibility after nerve injury and repair: a systematic review of evidence for validity, reliability and responsiveness of tests. *J Hand Surg Br.* 2005;30(3):252–64.
22. Asif M, Sarkar PK. Three-digit Allen's test. *Ann Thorac Surg.* 2007;84:686–7.
23. Brown JM, Mokhtee D, Evangelista MS, Mackinson SE. Scratch collapse test localizes Osborne's band as the point of maximal nerve compression in cubital tunnel syndrome. *Hand (NY).* 2009;5:141–7.

Hand Function

A Practical Guide to Assessment

Duruöz, M.T. (Ed.)

2014, XII, 251 p. 97 illus., 43 illus. in color., Hardcover

ISBN: 978-1-4614-9448-5