

Michael Aynardi and Steven M. Raikin

Introduction

Originally published in the early 1970s by Lauterbur and Mansfield, the technique for magnetic resonance imaging (MRI) has evolved substantially over the past four decades [1]. MRI utilizes the physical properties of nuclear magnetic resonance (NMR) where magnetic fields and radio waves excite atoms which then produce signals. These signals are then processed and used to create detailed images of anatomical structures. The major advantage of MRI is that it does not use ionizing radiation [2].

Technological advances in computer systems and stronger magnetic designs have continued to improve the accuracy of MRI. Today some health centers employ new 3 Tesla (T) scanners. These 3 T scanners have superior definition of structures, higher resolution, and decreased artifact compared to older models and offer the possibility of improved diagnostic capability especially

when evaluating articular surfaces, ligaments, nerves, and tendons of the foot. However, the increasing magnet strength also increases metal artifact from implanted devices [3].

Although MRI can be a valuable diagnostic tool in the diagnosis of athletic injury, it is often over utilized. In a retrospective review, Tocci et al. demonstrated that the majority of MRI scans are ordered as screening tools by primary care providers and are often unnecessary with almost half yielding radiographic interpretations which were viewed as immaterial or inconsistent with the patient's history and exam [4].

It is imperative that foot and ankle surgeons are comfortable reviewing MRI images and understand the reasoning behind ordering the examination. The objective of the following chapter is to review several common sports injuries to the foot and to highlight key findings on MRI.

Sports Injuries of the Foot

Lisfranc Injury

Injury to the tarsal–metatarsal articulation is an athletic injury which can occur when a plantar-flexed foot is axially loaded. It is critical to realize that up to 20 % of these injuries are missed or overlooked at presentation [5, 6]. The Lisfranc joint is the articulation between the recessed second tarsal–metatarsal joint and is stabilized by dorsal and plantar ligamentous structures. The primary stabilizers are plantar ligaments which

M. Aynardi, MD

Department of Orthopaedics, Rothman Institute at Thomas Jefferson University Hospital,
1015 Walnut Street, Curtis Building Suite 801,
Philadelphia, PA 19107, USA
e-mail: michael.aynardi@gmail.com

S.M. Raikin, MD (✉)

Professor of Orthopaedic Surgery, Foot and Ankle Service, Rothman Institute at Thomas Jefferson University, 925 Chestnut Street, 5th Floor,
Philadelphia, PA 19107, USA
e-mail: steven.raikin@rothmaninstitute.com

run from the medial cuneiform to the bases of the second and third metatarsals [4, 6]. Disruption of this ligament will result in midfoot instability. Failure typically occurs through the dorsal ligaments initially, continues through interosseous ligaments, and down through the strong plantar ligament where it becomes completely unstable. Additional longitudinal stabilization is provided by the plantar middle to medial cuneiform ligament and when disrupted can also destabilize the midfoot [7]. Failure to recognize this injury can have serious consequences and may lead to early arthritis of the midfoot [8].

MRI of the tarsal–metatarsal articulation has been able to identify each of the ligamentous structures which comprise the Lisfranc complex [9, 10]. The entire ligament complex can often be visualized in the coronal plane using three millimeter thick cuts in two to three consecutive sequences. Additionally, long axis images can be reviewed to evaluate its integrity. In the acute phase, ligament disruption is best visualized on fat-suppressed or fluid-sensitive sequences on the MRI scan, such as short tau inversion recovery (STIR) images sequence, and will show signal hyperintensity with a defect in the ligament complex (Fig. 2.1). Edema and hyperintense signal along the course of the ligament is indicative of the disruption as well. Bony structures should be thoroughly evaluated for marrow edema or subtle avulsions of the ligamentous origins and insertions which may also represent injury to the Lisfranc complex. T2-weighted sequence images should be reviewed for evidence of edema in surrounding soft tissues as this may accompany injury to the complex [11].

The sensitivity of MRI at accurately diagnosing injury of the Lisfranc ligamentous complex is high. In some series, MRI studies correctly classified the severity of the injury in 90 % of cases and were confirmed at the time surgery. Furthermore, disruption of the plantar ligaments diagnosed on MRI has demonstrated a strong positive predictive value, 94 %, in detecting instability [12]. As a result, MRI can be a valuable tool in predicting patients who may require a surgical intervention in the setting of a Lisfranc injury.

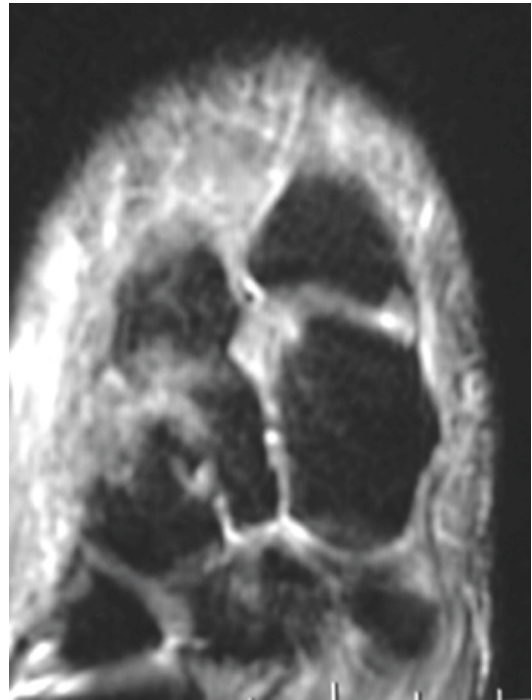


Fig. 2.1 Coronal images fluid-sensitive MRI sequencing demonstrating disruption of the Lisfranc ligament complex

Stress Fractures of the Foot

Stress fractures are micro-fractures that result from physical loading and may eventually become complete if that loading continues. In athletes, stress fractures may occur when bone is subjected to a repetitive force over time, a normal force along an abnormal axis of the bone, or when osteoporotic bone leads to insufficiency fracture under normal stress [13, 14]. Stress fractures can occur in any athlete but are more common in distance runners, jumping athletes, and military recruits. The history is typically one of pain with a repetitive activity, typically insidious at onset, and improves with rest and cessation of weight bearing. Clinicians should inquire about abnormal eating habits and menstruation as these appear in a condition known as the female athlete triad or anorexia athletica, which includes amenorrhea, disordered eating, and osteoporosis [15]. History is crucial as these patients are at an increased risk of stress fracture.

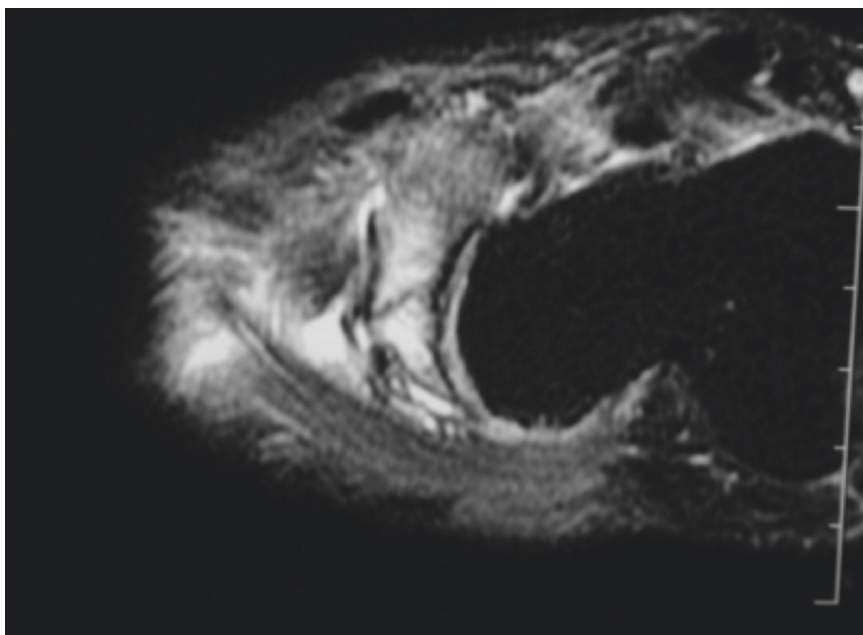


Fig. 2.2 T2-weighted MRI images of a stress fracture of the navicular demonstrating increased signal within the marrow and in the surrounding soft tissue

Although plain radiographs rarely aid in the diagnosis of early stress fracture (less than 2 weeks), MRI is quite sensitive at confirming the diagnosis [16]. The stress fracture is seen on MRI as a loss of fat and signal within the marrow accompanied by a hypo-intense fracture line with periosteal reaction on either T1-weighted sequences or non-fat-suppressed T2-weighted images. Additional indicators of injury and edema to the bone are demonstrated well on STIR and fat-suppressed T2-weighted sequences which show increased signal circumferentially at the site of the stress fracture [13, 14, 17]. Bones of the foot most commonly involved in stress fractures in athletes are the navicular (runners) (Fig. 2.2), the fifth metatarsal (cutting sports: football, soccer, lacrosse), and the second metatarsal (jumping sports: dancers, basketball). The MRI, however, is not useful in assessing foot alignment (particularly varus alignment with lateral foot overload leading to fifth metatarsal fractures) and morphological anomalies which may lead to stress fractures and are best seen on weight-bearing radiographs.

Plantar Plate Injuries

The plantar plate is a fibro-cartilaginous structure which is centered over the metatarsophalangeal (MPT) joint on the plantar aspect of the foot. It originates on the plantar aspect of the metatarsal shaft near the meta-diaphyseal junction and inserts distal to the articular surface of the MTP joint directly onto the lip of the proximal phalanx. The dimensions of this anatomic structure have been reported and average 1.8 mm in thickness, 9 mm in width, and 16 mm in length [18, 19]. The plantar plate is responsible for stabilizing the MTP joint and resisting excessive dorsiflexion. Athletic injury to the first MTP joint plantar plate complex is common and can occur with a forced hyperextension mechanism and typically occurs where a fixed plantigrade forefoot and elevated heel are forced into an even greater degree of hyperextension from the impact of another competitor. The injury can occur in any of the MPT joints, and when it involved the hallux MTP joint it is termed a “turf toe” injury. The turf toe injury is casually related to the flexible soled shoes often worn during playing

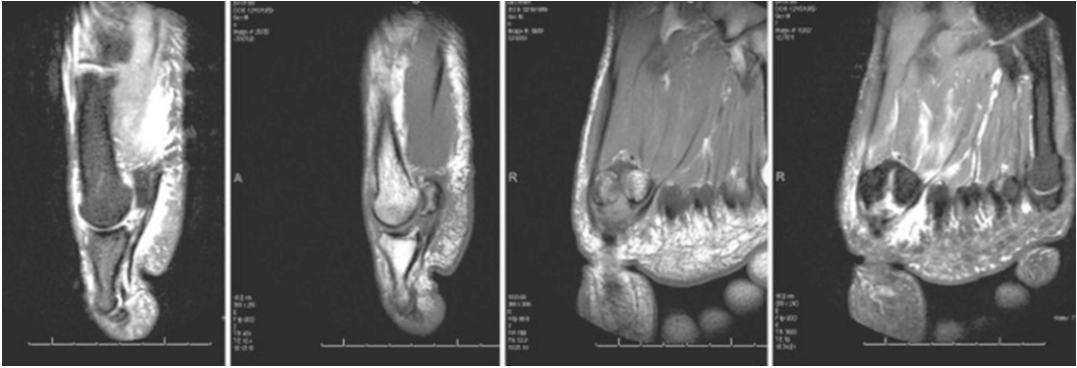


Fig. 2.3 Series of MRI sequences demonstrating disruption of the plantar plate

on synthetic turf surfaces, and not due to the playing surface itself. With all locations of plantar plate injuries, patients complain of pain over the plantar surface of the first MTP joint, acute swelling, and limited range of motion secondary to guarding. Clinically, however, passive range of motion demonstrates laxity in dorsiflexion secondary to disruption and insufficiency of the plantar plate. Occasionally patients may even present with a dorsally dislocated hallux [20].

Normal imaging of the plantar plate on MRI has been described as a low-intensity structure, smooth, and curvilinear traveling from its origin on the metatarsal shaft to its insertion distal to the articular surface at the proximal phalangeal base [21]. Disruption of the plantar plate on MRI is demonstrated through increased signal intensity in both sagittal and coronal planes on proton density-weighted and T2-weighted fat-suppressed images. Tears of the plantar plate usually occur at the distal insertion into the base of the proximal phalanx. This is best seen on the coronal plane MR image, as sagittal images may not be well aligned with the longitudinal axis of the metatarsal axis, while the sagittal sequences are valuable in demonstrating retraction of a tear to the plantar plate [22] (Fig. 2.3).

The diagnostic accuracy of MRI of the plantar plate is varied. Gregg et al. [23] reported a sensitivity of 87 % and an accuracy of 71 % at diagnosing full-thickness tears of the plantar plate insertion; however, accuracy for diagnosing partial-thickness tears was 25 % in this series. Employing an anatomic grading system, Coughlin et al. [24] demonstrated

a 96 % sensitivity and accuracy of 89 % with MRI and confirmed with arthroscopy. In this system, a grade 0 lesion corresponds to attenuation of the plantar plate. Grade 1 lesions are transverse distal tears of the plate with less than 50 % involvement. Grade 2 lesions are transverse distal tears greater than 50 % of the plate. Grade 3 lesions are extensive transverse or longitudinal tears which may involve collateral ligaments. Grade 4 is a tear with dislocation. When employing an anatomic grading system, the diagnostic accuracy of MRI of the plantar plate improves.

Osteochondral Injuries of the First MT Head

While osteochondral injuries to the talus are far more common, osteochondral injuries do occur in the foot [25]. Athletes sustaining forced hyperextension injures to the first MTP joint such as in disruption of the plantar plate can also dislocate and cause a traumatic chondral lesion to the first MT head. This may be suggested by a shadowing within the subchondral region of the MT head on plane radiographs, but is best diagnosed on MRI similar to elsewhere in the body. T2-weighted images are evaluated for the presence of a rim of increased signal surrounding the lesion, which may indicate the lesion is unstable. The presence of a cyst beneath an osteochondral lesion usually represents an unstable lesion as well. T2-weighted images in unstable lesions may demonstrate bony edema surrounding the lesion (Fig. 2.4a–d) [26].

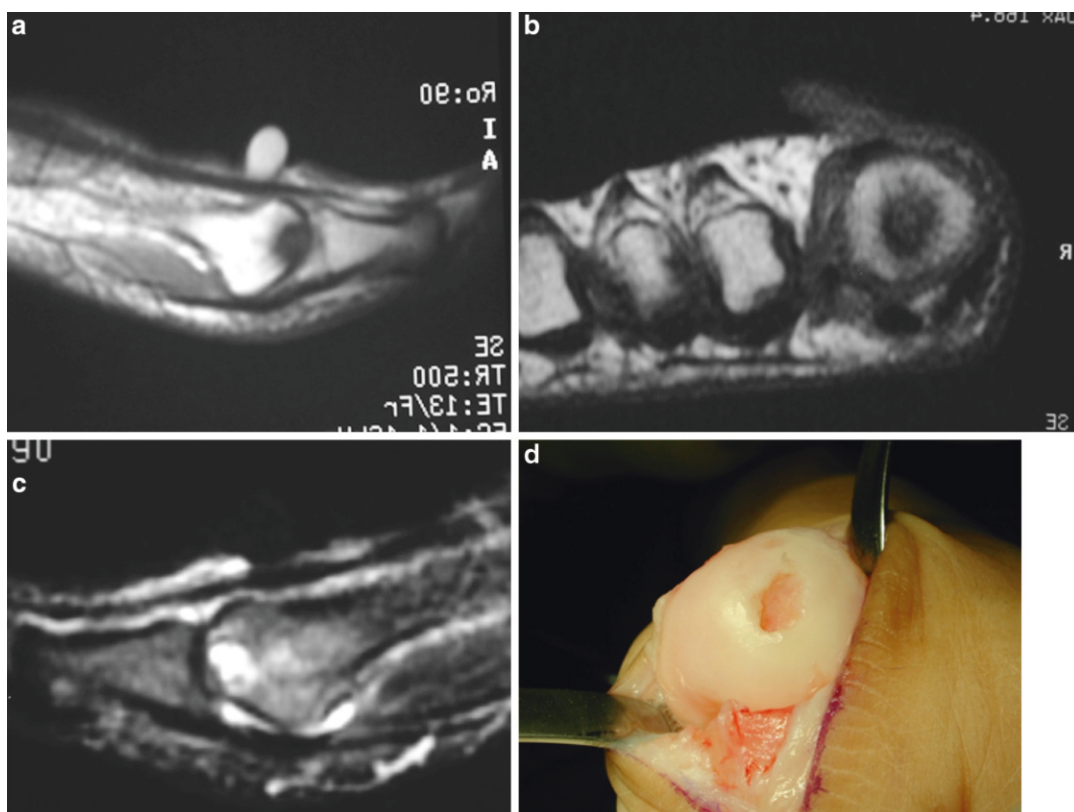


Fig. 2.4 (a–c) T1- and T2-weighted MRI sequences of an osteochondral defect of the first metatarsal head showing increased signal on T2-weighted images surrounding the

lesion suggesting that it may be unstable. (d) Intraoperative photograph demonstrating an unstable OCD lesion of the first metatarsal head

Sesamoid Injuries

The sesamoid bones of the hallux function to absorb contact and weight-bearing forces as well as protect the flexor hallucis longus tendon, and increase the mechanical force of flexor hallucis brevis. Injuries to the sesamoids are more common in athletic events (gymnastics, basketball) which overload the plantar aspect of the first MPT joint and can be an acute event or resulting from repetitive trauma. Injury to the sesamoids is responsible for nearly 4 % of all overuse injuries to the foot and includes stress fractures, sesamoiditis, avascular necrosis, and inflammation of the synchondrosis of a bipartite sesamoid [27]. The tibial sesamoid is more commonly involved as it is larger and more affected by weight-bearing. MRI is valuable in evaluating both the plantar plate and the structures which intimately surround the sesamoid bones [14].

Stress response and stress fractures of the sesamoids on MRI most commonly show low T1-weighted signal intensity with increased signal intensity on T2 and STIR images (Fig. 2.5). On the other hand, sesamoiditis usually has a normal T1-weighted signal with an increased STIR signal intensity. It is important to realize that there is some overlap in these conditions. It is also important to note that almost 10 % of the population has a bipartite tibial sesamoid and 25 % of these are bilateral. Bipartite sesamoids can be distinguished from fracture by the smooth break in the cortices on imaging [14, 17].

Distal Peroneal Injuries

The peroneus longus muscle arises from the posterior and lateral aspects of the fibula and passes posteriorly to the lateral malleolus, below the peroneal

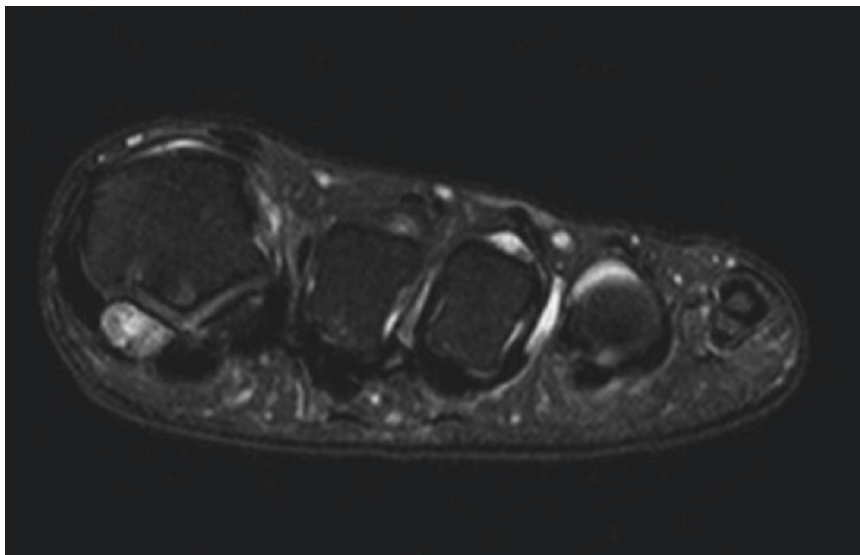


Fig. 2.5 MRI demonstrating increased signal intensity on T2-weighted imaging within the tibial sesamoid in a patient with tibial sesamoiditis

tubercle of the calcaneus, through a fibro-osseous sheath beneath the cuboid, crossing the midfoot to insert at the base of the medial cuneiform and first metatarsal [28]. There is a watershed area for the vascular supply of the tendon which is also the most common area of injury and is located within the fibro-osseous tunnel as the tendon passes beneath the cuboid [29]. In athletes, there exists a wide variety of peroneus longus tendon pathology including acute inflammation of the tendon, tendon tears or ruptures, and dislocation or subluxation which may all present as lateral ankle pain. Additionally an os peroneum (accessory sesamoid bone which is found within the peroneus longus tendon at the level of the calcaneo-cuboid joint) can be a stress point within the lateral foot in the athlete. Like the metatarsal sesamoid this can be prone to overuse sesamoiditis (called painful os peroneum syndrome or POPS) (Fig. 2.6), or fracture which subsequently results in rupture of the peroneus longus tendon. This is seen in athletes who require recurrent push off utilizing their first ray (the peroneus longus is the primary plantar flexor of the first ray) such as baseball pitches. Moreover, several anatomic variants such as an os peroneum also may attribute to foot pain and can confuse the clinical scenario.

Distal injuries to the peroneus longus tendon are less common in athletes than injuries in other locations of the tendon (retrofibular region) but do occur [30]. Rademaker et al. suggest several possible causes for midfoot tears of the peroneus longus tendon. First, they propose attritional tears may occur as the result of stress from the tendon sliding under the cuboid bone. Alternatively, patients with a hypertrophied peroneal tubercle have been implicated in predisposing patients to injury of the tendon [31].

MRI evaluation of distal peroneus longus injuries includes T1 and fat-suppressed T2-weighted images in all planes. Distal complete tears generally occur at the fibro-osseous tunnel of the cuboid. MRI images will demonstrate discontinuity of the tendon with an empty sheath sign at this level with retraction of the tendon [31]. Further, distal tears are best visualized on the oblique coronal plane. Associated findings on MRI of a complete distal tear include edema of the lateral wall of the calcaneus, fluid within the tendon sheath, and a disrupted anterior talofibular ligament. It is still unclear whether the presence of an os peroneum predisposes patients to risk of rupture of the peroneus longus [31].

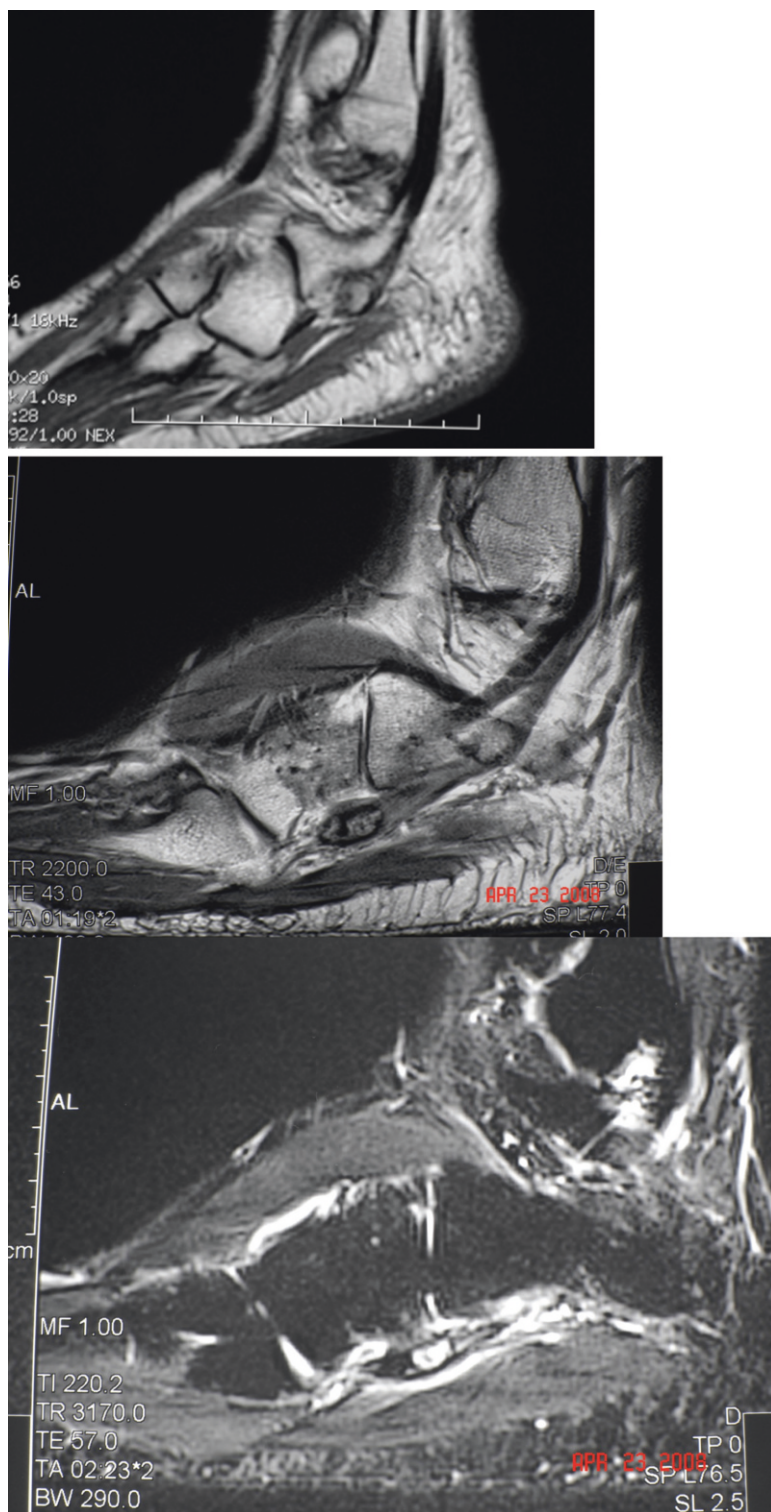


Fig. 2.6 MRI sequences of a young athlete with lateral foot pain with activity. Imaging revealed the presence of an os peroneum on both T1- and T2-weighted sequences with corresponding increased signal intensity on T2 imaging

Interstitial tears are defined as intermediate signal density seen within the tendon both on T1- and T2-weighted images. Inflammation and swelling within the sheath are best appreciated by increased signal intensity circumferentially on T2-weighted images demonstrating fluid collection (Fig. 2.6). Injuries to the superficial peroneal retinaculum have been defined by Oden [32] and include elevation of the SPR at the fibular groove (type 1), complete tear of the SPR attachment to the distal fibula (type 2), avulsion of the SPR at its attachment (type 3), or lastly tears of the posterior attachment of the SPR (type 4). In addition, MRI may reveal the presence of a peroneus quartus muscle.

While MRI is highly sensitive and specific at detecting swelling and complete tears of the peroneus longus, its diagnostic value at diagnosing interstitial tears is less predictable. Park et al. reported 50 % sensitivity and 96 % specificity with MRI in diagnosing interstitial tears and a 100 % sensitivity and 96 % specificity at detecting swelling [33]. As a result, MRI is sensitive but not very specific for reporting negative findings when evaluating peroneus longus tendon injuries. The major difficulty is related to the inability to image along the true longitudinal axis of the tendon and signal artifact which can occur from volume averaging [29].

Originating from the lateral compartment and traveling within the peroneal groove anterior and medial to peroneus longus, the peroneus brevis tendon runs distally to the peroneal tubercle where it separates into its own sheath and finally inserts on the proximal base of the fifth metatarsal. Injury to the peroneus brevis occurs commonly in athletes and usually occurs near the level of the ankle. Occasionally, athletes can sustain injuries to peroneus brevis at its insertion. The mechanism is typically one of an inversion injury [34]. MRI findings of a torn peroneus brevis tendon result in a classic “C-shaped” appearance, which encircles the longus tendon if the tear is retromalleolar. Insertional ruptures will reveal distal disruption of the normal hypointense signal on T1-weighted images and increased intra-substance signal on T2-weighted sequences at the insertion near the base of the

fifth metatarsal [29]. Lamm et al. [35] have reported fair diagnostic accuracy with respect to MRI of proximal, distal, and retromalleolar peroneus brevis injury. For all tears, they reported 83 % sensitivity and 75 % specificity compared to intraoperative findings; however, Park et al. [33] reported a 44 % sensitivity and 99 % specificity at diagnosing interstitial tears of peroneus brevis when compared to operative findings. Furthermore, Lamm et al. demonstrated that peroneus brevis pathology rarely occurs in isolation with MRI revealing a high number of coexisting conditions including low-lying muscle belly or peroneus quartus in 44 % of cases, rupture of the anterior talofibular ligament in 50 %, a flat or convex fibular groove in 78 %, and increased signal within peroneus longus tendon in 53 % of cases [35]. It is important to realize that peroneus brevis pathology rarely occurs in isolation.

Flexor Hallucis Longus Injuries

The flexor hallucis longus tendon originates posteriorly from the distal two-thirds of the fibula and runs posterior to the hindfoot as it courses through a fibro-osseous tunnel between the posterolateral and posteromedial tubercles of the talus. It then runs underneath the sustentaculum tali and dorsal to the neurovascular bundle and flexor digitorum longus at the knot of Henry, courses between the sesamoids of the great toe until inserting on the plantar aspect of the distal phalanx. Impingement can occur along any of these sites and results in inflammation of the tendon [36]. Injuries to the FHL tendon are more common in athletes who perform activities in maximally plantar-flexed position such as gymnasts and ballet dancers [37]. Physical examination may reveal pain along the course of the tendon, pain with flexion of the interphalangeal joint, or pain with forceful plantar flexion. Triggering may occur if patients have formed a nodule secondary to chronic inflammation.

MRI of the FHL tendon with inflammatory changes can show thickening of the tendon and increased signal intensity on T2 and STIR; STIR

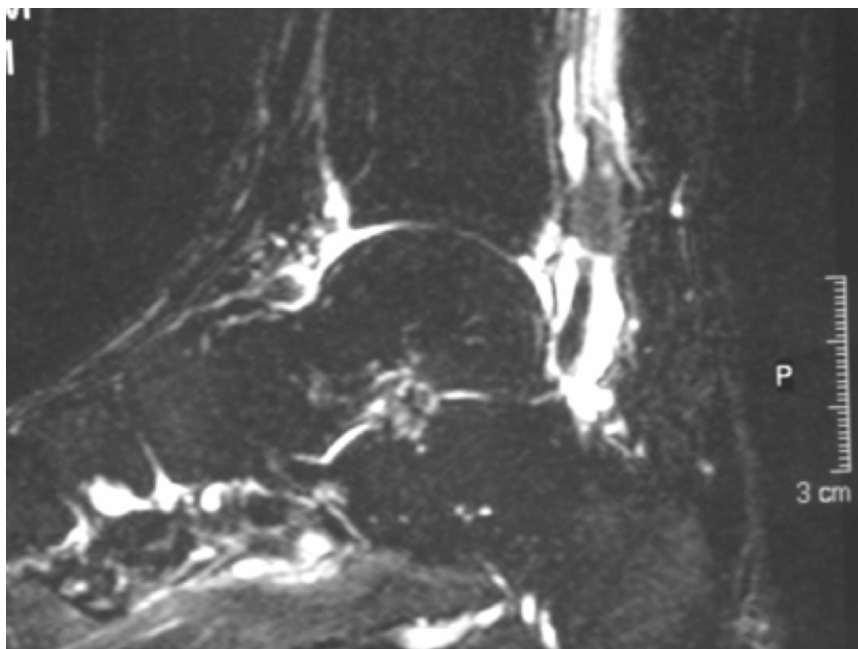


Fig. 2.7 T2-weighted sagittal MRI sequence of a female athlete with flexor hallucis tenosynovitis. Notice the presence of fluid within the sheath

and T2-weighted images may also show a homogenous collection of fluid around the tendon within the sheath indicating tenosynovitis (Fig. 2.7). Interestingly, the FHL sheath communicates with the ankle joint in almost 20 % of patients; therefore a joint effusion can mimic synovitis of the FHL tendon. In differentiating the two conditions, fluid will be located more proximal to the talar fibro-osseous tunnel if the increased signal is secondary to tenosynovitis. Additionally, absence of intra-articular fluid within the ankle when the FHL sheath has fluid signal is consistent with a synovitis.

If clinical history and examination suggest disruption of the tendon either secondary to penetrating trauma or forceful eccentric loading, MRI can be useful in evaluating the tendon's integrity. Disruption of the normal tendon structure is best seen as a change from the typical homogenous low-signal intensity to increased signal and disruption of the tendon on T2-weighted or STIR images along the tendon's course. Additionally an enlarged sheath filled with fluid and the absence of a tendon can be seen if the tendon is torn and retracted [37, 38].

Extensor Hallucis Longus and Extensor Digitorum Longus Injuries

Originating along the fibula and interosseous membrane anteriorly and innervated by the deep peroneal nerve, both the extensor hallucis longus and extensor digitorum longus travel deep to the superior and inferior extensor retinacula before inserting along the dorsal base of their respective toes. Injury to these tendons will result in a loss of toe extension and some loss in ankle dorsiflexion. As these tendons run superficially they are susceptible to laceration with penetrating trauma [39]. Closed ruptures of the extensor tendons are rare. When these do occur they typically are a result of a highenergy eccentric contraction but may be the result of attritional rupture in patients with repetitive microtrauma or prior steroid use. MRI of these conditions is straightforward and will show fluid signal within the tendon sheath on T2-weighted and STIR images with discontinuity of the tendon itself along its course [40].

Overuse injury can occur to the EHL tendon resulting in tenosynovitis. As with other tendon

injuries, MRI can demonstrate thickening of the tendon and increase signal intensity on T2-weighted and STIR images with a homogenous collection of fluid around the tendon within the sheath. Tenosynovitis of the EHL tendon has been implicated as a causative factor in anterior ankle impingement in athletes such as, skiers, soccer players, or runners where the inflammation from tenosynovitis of the tendon or an anterior osteophyte from the tibia can irritate or compress the deep peroneal nerve as it passes within the extensor retinaculum. If this diagnosis is suspected, MRI is the modality of choice as it will reveal tenosynovitis of extensor hallucis longus while radiographs may only demonstrate an anterior osteophyte on the tibia [40, 41].

Tibialis Anterior Injuries

Originating along the tibial shaft and interosseous membrane, passing under the extensor retinacula and inserting on the medial cuneiform and base of the first metatarsal, the tibialis anterior is the primary dorsiflexor of the foot and inverts the subtalar and transverse tarsal joints. The superficial location of this tendon makes susceptible to laceration. Acute, closed ruptures are painful with the patient reporting a popping sensation. They typically occur through a forceful eccentric contraction to a position of dorsiflexion from a plantar-flexed foot. Attritional ruptures are more common than acute ruptures and tend to occur in older individuals, and additionally have been reported in patients with diabetes, steroid usage, or inflammatory arthritis. Patients with a tibialis anterior rupture can present with a steppage gait, pain along the tendon, weakness in dorsiflexion, or an absence of a palpable tendon during resisted dorsiflexion.

MRI of a ruptured tibialis anterior tendon will demonstrate increased fluid signal within the tendon sheath on T2-weighted and STIR imaging (Fig. 2.8). Additionally, sagittal imaging should be carefully reviewed and may show an empty sheath revealing discontinuity of the tendon [42]. The tendon usually retracts and may be seen as a balled up mass at the discontinued end of the tendon on

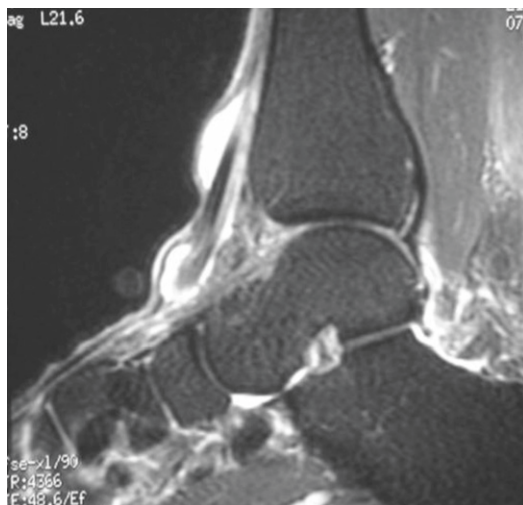


Fig. 2.8 Sagittal T2-weighted MRI sequences of a ruptured tibialis anterior tendon demonstrating increased fluid signal within the tendon sheath and retraction of the tendon

the sagittal imaging. The retracted end is usually seen more proximally at the ankle level where it is get trapped at the superior extensor retinaculum.

Infections

Both osteomyelitis and soft-tissue infections can occur in the athlete, and MRI can be useful at aiding in the correct diagnosis. This is most frequently seen following a penetrating injury through the sole of an athletic shoe, such as stepping on an old nail left on the sports field. Soft-tissue abscess have central areas of low-signal intensity on T1-weighted images with increased surrounding signal on T2-weight sequences as well as evidence of inflammation in adjacent soft tissue and skin. Additionally, the thick irregular wall of an abscess will enhance with the administration of gadolinium contrast [43]. A tract or foreign body may be seen on the MR image. Additionally septic tenosynovitis may be seen as high intensity fluid signal on T2 sequencing, traversing the flexor tendon sheath originating from the site of the infection.

MRI is extremely sensitive and is the imaging modality of choice for diagnosis of osteomyelitis.

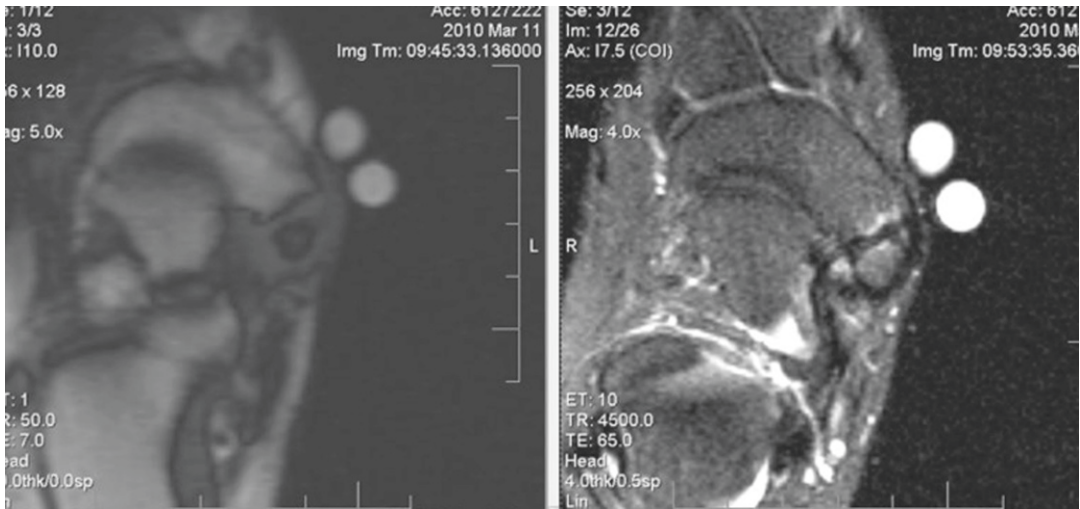


Fig. 2.9 T2- and T1-weighted MRI sequences in a male soccer player complaining of medial foot pain. Imaging demonstrated the presence of an accessory os navicular

and T2-weighted images demonstrated bone marrow edema within the accessory os and navicular

In adults, MRI of osteomyelitis demonstrates loss in the fatty signal of bone marrow on T1-weighted sequence and T2-weighted and STIR images which show focal increased signal intensity at the site of infection of the marrow space [44]. Additional indicators of osteomyelitis compared to other diagnosis such as neuroarthropathy may be the presence of a sinus tract, overlying ulcer, location of the signal in weight-bearing regions, involvement of only one bone, and absence of deformity [45]. While contrast may demonstrate enhancement in osteomyelitis, it does not appear to improve the diagnostic accuracy in MRI [44].

Accessory Navicular

Accessory ossicles are common in the foot with an accessory navicular present in over 10 % of patients. Most patients are asymptomatic; however, an accessory navicular can be a source of medial foot pain in athletes [46]. Hypothesized by Kidner in 1929, certain types of accessory navicular bones may alter the biomechanics of the posterior tibialis tendon and thus unbalance the foot resulting in injury or deformity [47].

There are three types of accessory navicular with Type 2 being the most commonly symptomatic. Type 1 is a sesamoid bone within the posterior tibialis tendon. Type 2 is an ossification center which is connected to the navicular via a thin synchondrosis. Type 3 is a complete fusion of the accessory os with the navicular resulting in a prominent navicular tuberosity.

Clinical history is medial foot pain exacerbated with activity and cleat wear. There may be a flat-foot examination with tenderness over the navicular tuberosity. Radiographic examination will reveal the presence of an os. In some instances it is difficult to discern whether the accessory navicular is the exact source of pain. In these patients with suspected symptomatic accessory navicular, MRI can be utilized to help differentiate. T2-weighted and STIR sequences may demonstrate bone marrow edema within the accessory os and may show edema within the navicular as well (Fig. 2.9). Further, the synchondrosis may show increased signal intensity representing injury to the area. MRI is useful in demonstrating the effect of the accessory os on the insertion of the posterior tibialis tendon as well as its integrity [48–51].

Summary

MRI can be a very valuable diagnostic tool when evaluating athletic injuries of the foot. It should not be utilized as a screening tool; rather, as a modality ordered to answer a specific question based of a thorough history and clinical examination. It is vital that the evaluator of the MRI has an extensive understanding of the normal anatomy (and its variants) of the foot and their appearance on MR imaging [52, 53]. We also recommend that the treating physician personally reviews the MRI films in all cases and ensures that their interpretation is supported by the clinical findings and correspond to those of the radiologist official report. As technology continues to improve so will the quality of the images produced; yet it is unclear how the current climate of healthcare will affect the utilization of MRI in the future.

References

1. Geva T. Magnetic resonance imaging: historical perspective. *J Cardiovasc Magn Reson*. 2006;8:573–80.
2. Lauterbur PC. Image formation by induced local interactions: examples of employing nuclear magnetic resonance. *Nature*. 1973;242:190–1.
3. Chhabra A. 3T magnetic resonance imaging of the ankle and foot. *Foot Ankle Int*. 2012;33:164–71.
4. Tocci SL, Madom IA, et al. The diagnostic value of MRI in foot and ankle surgery. *Foot Ankle Int*. 2007;28:166–8.
5. Curtis MJ, Myerson M, Szura B. Tarsometatarsal joint injuries in the athlete. *Am J Sports Med*. 1993;21:497–502.
6. Sherief TI, Mucci B, Greiss M. Lisfranc injury: how frequently does it get missed? And how can we improve? *Injury*. 2007;38:856–60.
7. Peicha G, Labovitz J, Seibert FJ, Grechenig W, Weiglein A, Preidler KW, Quehenberger F. The anatomy of the joint as a risk factor for Lisfranc dislocation and fracture-dislocation. An anatomical and radiological case-control study. *J Bone Joint Surg Br*. 2002;84:981–5.
8. Myerson MS, Fisher RT, Burgess AR, Kenzora JE. Fracture dislocations of the tarsometatarsal joints: end results correlated with pathology and treatment. *Foot Ankle*. 1986;6:225–42.
9. Preidler KW, Wang YC, Brossman J, et al. Tarsometatarsal joint: anatomic details on MR images. *Radiology*. 1996;199:733–6.
10. de Palma L, Santucci A, Sabetta SP, et al. Anatomy of the Lisfranc joint complex. *Foot Ankle Int*. 1997;18:356–64.
11. Crim J. MR imaging evaluation of subtle Lisfranc injuries: the midfoot sprain. *Magn Reson Imaging Clin N Am*. 2008;16:19–27.
12. Raikin SM, Elias I, et al. Prediction of midfoot instability in the subtle Lisfranc injury. *J Bone Joint Surg Am*. 2009;91A:892–9.
13. Ting A, Morrison W, Kavanagh E. MR imaging of midfoot injury. *Magn Reson Imaging Clin N Am*. 2008;16(1):105–15.
14. Zoga A, Schweitzer M. Imaging sports injuries of the foot and ankle. *Magn Reson Imaging Clin N Am*. 2003;11:295–310.
15. Sudi K, et al. Anorexia athletica. *Nutrition*. 2004;20:657–61.
16. Brukner P, Bennell K. Stress fractures in female athletes. Diagnosis, management and rehabilitation. *Sports Med*. 1997;24(6):419–29.
17. Wall J, Feller J. Imaging of stress fractures in runners. *Clin Sports Med*. 2006;25:781–802.
18. Deland JT, Lee KT, Sobel M, DiCarlo EF. Anatomy of the plantar plate and its attachments in the lesser metatarsal phalangeal joint. *Foot Ankle Int*. 1995;16:480–6.
19. Johnston 3rd RB, Smith J, Daniels T. The plantar plate of the lesser toes: an anatomical study in human cadavers. *Foot Ankle Int*. 1994;15:276–82.
20. Rodeo SA, O'Brien S, Warren RF, et al. Turf-toe: an analysis of metatarsophalangeal joint sprains in professional football players. *Am J Sports Med*. 1990;18(3):280–5.
21. Yao L, Cracchiolo A, Farahani K, Seeger LL. Magnetic resonance imaging of plantar plate rupture. *Foot Ankle Int*. 1996;17:33–6.
22. Umans HR, Elsinger E. The plantar plate of the lesser metatarsophalangeal joints: potential for injury and role of MR imaging. *Magn Reson Imaging Clin N Am*. 2001;9:659–69.
23. Gregg J, Silberstein M, Schneider T, Marks P. Sonographic and MRI evaluation of the plantar plate: a prospective study. *Eur Radiol*. 2006;16:2661–9.
24. Nery C, Coughlin M, et al. MRI evaluation of the MTP plantar plates compared with arthroscopic findings: a prospective study. *Foot Ankle Int*. 2013;34:315–22.
25. Davies MS, Saxby TS. Arthroscopy of the first metatarsophalangeal joint. *J Bone Joint Surg Br*. 1999;81-B:203–6.
26. Weishaupt D, Schweitzer ME. MR imaging of the foot and ankle: patterns of bone signal abnormalities. *Eur Radiol*. 2002;12:416–26.
27. McBryde AM, Anderson RB. Sesamoid foot problems in the athlete. *Clin Sports Med*. 1988;7:41–60.
28. Edwards ME. The relations of the peroneal tendons to the fibula, calcaneus, and cuboideum. *Am J Anat*. 1928;42:213–53.
29. Khoury NJ, el-Khoury GY, Saltzman CL, Kathol MH. Peroneus longus and brevis tendon tears: MR imaging evaluation. *Radiology*. 1996;200:833–41.
30. Thompson FM, Patterson AH. Rupture of the peroneus longus tendon: a report of three cases. *J Bone Joint Surg Am*. 1989;71:293–5.

31. Rademaker J, Rosenberg Z, et al. Tear of the peroneus longus tendon: MR imaging features in nine patients. *Radiology*. 2000;214:700–4.
32. Oden RR. Tendon injuries about the ankle resulting from skiing. *Clin Orthop Relat Res*. 1987;216:63–9.
33. Park HJ, Lee SY, et al. Accuracy of MR findings in characterizing peroneal tendons disorders in comparison with surgery. *Acta Radiol*. 2012;53:795–801.
34. Larsen E. Longitudinal rupture of the peroneus brevis tendon. *J Bone Joint Surg Br*. 1987;69:340–1.
35. Lamm BM, Myers DT, et al. Magnetic resonance imaging and surgical correlation of peroneus brevis tears. *J Foot Ankle Surg*. 2004;43(1):30–6.
36. Quirk R. Common foot and ankle injuries in dance. *Orthop Clin North Am*. 1994;25:123–33.
37. Hillier JC, Peace K, Hulme A, Healy JC. MRI features of foot and ankle injuries in ballet dancers. *Br J Radiol*. 2004;77:532–7.
38. Lo LD, Schweitzer ME, Fan JF, Wapner KL, Hecht PJ. MR imaging findings of entrapment of the flexor hallucis longus tendon. *AJR Am J Roentgenol*. 2001;176:1145–8.
39. Murphy GA. Disorders of tendons and fascia. In: Canale ST, editor. *Campbell's operative orthopaedics*. 10th ed. St. Louis: Mosby; 2003. p. 4204.
40. Masciocchi C, Catalucci A, Barile A. Ankle impingement syndromes. *Eur J Radiol*. 1998;27 Suppl 1:S70–3.
41. Dunfee WR, Murray MK, Kneeland JB. Imaging of athletic injuries to the ankle and foot. *Radiol Clin N Am*. 2002;40:289–312.
42. Patten A, Wai-Ki P. Spontaneous rupture of the tibialis anterior tendon: a case report and literature review. *Foot Ankle Int*. 2000;21:697–700.
43. Boutin RD, Brossmann J, Sartoris DJ, et al. Update on imaging of orthopedic infections. *Orthop Clin North Am*. 1998;29:41–66.
44. Miller TT, Randolph Jr DA, et al. Fat-suppressed MRI of musculoskeletal infection: fast T2-weighted techniques versus gadolinium-enhanced T1-weighted images. *Skeletal Radiol*. 1997;26:654–8.
45. Tan PL, Teh J. MRI of the diabetic foot: differentiation of infection from neuropathic change. *Br J Radiol*. 2007;80:939–48.
46. Kaar S, Femino J, Morag Y. Lisfranc joint displacement following sequential ligament sectioning. *J Bone Joint Surg*. 2007;89(10):2225–32.
47. Kidner FC. The prehallux (accessory scaphoid) in its relation to flat-foot. *J Bone Joint Surg*. 1929;11:831–7.
48. Lawson JP, Ogden JA, Sella E, Barwick KW. The painful accessory navicular. *Skeletal Radiol*. 1984;12:250–62.
49. Mosel LD, Kat E, Voyvodic F. Imaging of the symptomatic type II accessory navicular bone. *Australas Radiol*. 2004;48(2):267–71.
50. Bernaerts A, Vanhoenacker FM, Van de Perre S, De Schepper AM, Parizel PM. Accessory navicular bone: not such a normal variant. *JBR-BTR*. 2004;87(5):250–1.
51. Miller TT, Staron RB, Feldman F, Parisien M, Glucksman WJ, Gandolfo LH. The symptomatic accessory tarsal navicular bone: assessment with MR imaging. *Radiology*. 1995;195(3):849–53.
52. Shortt CP. Magnetic resonance imaging of the mid-foot and forefoot: normal variants and pitfalls. *Magn Reson Imaging Clin N Am*. 2010;18(4):707.
53. Lohman M, Kivisaari A, Vehmas T, Kallio P, Malmivaara A, Kivisaari L. MRI abnormalities of foot and ankle in asymptomatic, physically active individuals. *Skeletal Radiol*. 2001;30(2):61–6.

Sports Injuries of the Foot

Evolving Diagnosis and Treatment

Philbin, T.M. (Ed.)

2014, X, 224 p. 139 illus., 94 illus. in color., Hardcover

ISBN: 978-1-4899-7426-6