

Marcin Zlotorowicz and Jaroslaw Czubak

## 2.1 Introduction

The vascular anatomy of the femoral head has been already described in many textbooks and studies.

First descriptions of vascular anatomy came from the seventeenth century, when Hunter described *circulus articuli vasculosus*—the vascular ring at the base of the femoral neck [1]. Many other studies from the twentieth century have assessed the vascular anatomy of the femoral head in classical anatomical studies [2–5] and in angiographic studies [6–8].

Several studies during the last 15 years have demonstrated new concepts in the vascularization of the femoral head. Recent studies have used different methods of visualization of the arteries: classical anatomical dissections preserved in formaldehyde [9], classical anatomical dissections of fresh cadavers after intra-arterial injections of colored silicone [10–12], and visualization using contrast-enhanced magnetic resonance imaging [13] or contrast-enhanced computed tomography (CT) [14].

## 2.2 Nomenclature

While all authors use the same nomenclature to describe the medial femoral circumflex artery (MFCA), lateral femoral circumflex artery (LFCA), and superficial femoral and deep femoral arteries, the nomenclature of nutrient arteries is controversial. Some authors name the vessels retinacular arteries because of the neighboring retinacular fibers [6, 10–12, 15]. Other authors name the vessels according to the growth period, when the epiphysis and metaphysis are supported by different arteries and the epiphyseal plate constitutes a

barrier to the circulation within the epiphysis and metaphysis [8]. Crock and Chung described the arteries of the proximal end of the femur as an extracapsular and intracapsular arterial ring of the femoral neck with ascending cervical branches (anterior, posterior, lateral, and medial) and arteries of the round ligament [3, 4]. Howe described the terminal branches as the posterior superior and posterior inferior capital arteries arising from the MFCA and the foveal artery [2]. Judet named these vessels as superior and inferior groups of arteries supplying the femoral head [5].

The anastomosis of the MFCA with the inferior gluteal artery (IGA) was described in the early edition of Gray's Anatomy [16] as the anastomotic and articular branches, Jedral described it as a terminal branch of the IGA [17], while Gautier and Grose characterized it as the piriformis branch of the IGA [10, 18].

In our opinion, the most descriptive nomenclature names the vessels as nutrient arteries of the femoral head, which are delineated as posterior superior, posterior inferior, anterior, and the artery of ligamentum teres [9, 14]. For the anastomosis with the IGA we used the nomenclature by Gautier and Grose—the piriformis branch of the IGA [10, 18].

## 2.3 Blood Supply to the Femoral Head During Growth Phase

The vascular anatomy of the femoral head is very specific because the vascular patterns established during the growth phases do not change at maturity and persist throughout life [3, 4, 8]. The epiphysis and metaphysis have their own blood supply, and the arteries supporting them during the growth phase are called the epiphyseal arteries and metaphyseal arteries, respectively. Based on their sites of entry into the bone, the epiphyseal arteries are referred to as lateral and medial, and the metaphyseal arteries are indicated as superior and inferior. Lateral epiphyseal and superior metaphyseal arteries enter the bone at the superior and posterior-superior aspect of the femoral neck, near the

M. Zlotorowicz (✉) • J. Czubak  
Department of Orthopaedic, Pediatric Orthopaedic  
and Traumatology, The Medical Centre of Postgraduate  
Education in Warsaw, Grucha Teaching Hospital,  
Konarskiego 13, Otwock 05-400, Poland  
e-mail: [m.zlotorowicz@wp.pl](mailto:m.zlotorowicz@wp.pl); [jarek@czubak.neostrada.pl](mailto:jarek@czubak.neostrada.pl)

margin of the articular cartilage. The inferior metaphyseal arteries enter the bone close to the inferior margin of the articular cartilage. The lateral epiphyseal and both groups of the metaphyseal arteries arise from the MFCA. The medial epiphyseal artery is a continuation of the artery within the ligamentum teres, arising from the acetabular branch of the obturator artery. Injections to the femoral head proved that the lateral epiphyseal arteries predominate in the epiphysis and the inferior metaphyseal arteries in the metaphysis, and any contribution to vascularization by the artery of the ligamentum teres may be negligible or absent in some cases [8].

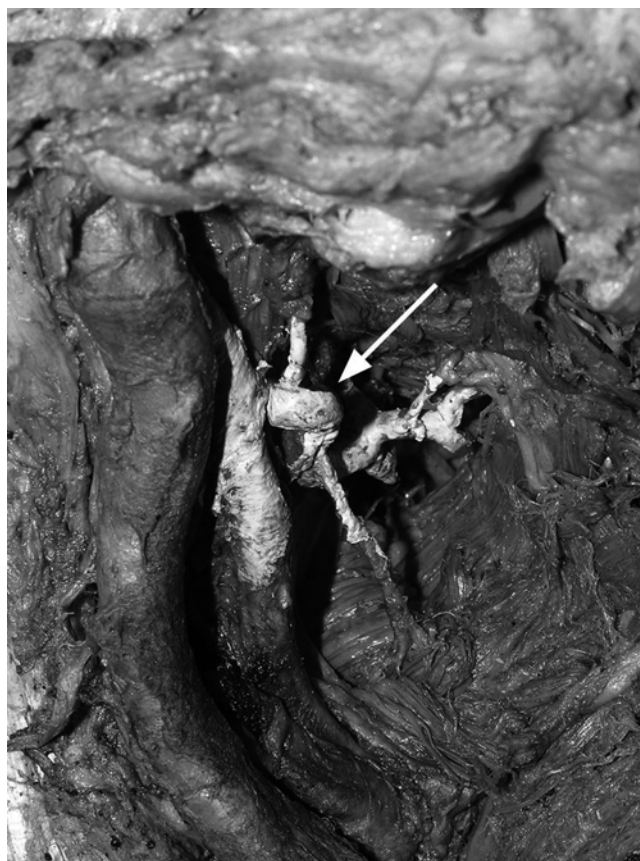## 2.4 Blood Supply to the Femoral Head

The femoral head is supplied by vessels arising mainly from the MFCA and IGA. Other vessels with lesser contribution arise from the LFCA, obturator artery, superior gluteal artery, and the first perforating branch of the deep femoral artery.

Most authors agree that there are three main groups of arteries supplying the femoral head: the group of posterior superior nutrient arteries of the femoral head arising from the deep branch of the MFCA, a posterior inferior nutrient artery also arising from the main trunk of the MFCA, and the piriformis branch of the IGA [2–6, 9, 10, 14].

### 2.4.1 MFCA with Terminal Branches

The MFCA arises either from the deep femoral artery (65–81 %) (Fig. 2.1) or, less commonly, from the femoral artery (6.4–34 %) [12, 19–22]. It can also arise as two branches, as noted in a single case example in one study [20], or there may be no main trunk of the MFCA present, as noted in a single case example in another study [14]. From this point, the MFCA travels through the space between the pectineus and iliopsoas muscles, changing course in direction to the lesser trochanter. During its course, it branches off superficially and these branches anastomose with the obturator artery in the space between the adductor longus and adductor brevis muscles [2, 9, 10]. A superficial branch, usually single, is observed in 98 % of cases and its diameter is 1.4 mm (0.7–3.5 mm) [19]. When the main trunk of the MFCA is kinked or otherwise occluded, the superficial branch may play a crucial role in supplying blood to the deep branch of the MFCA [19]. Anterior to the lesser trochanter and distal to the distal margin of the obturator externus muscle, the main trunk of the MFCA gives rise to the posterior inferior nutrient artery of the femoral head (Fig. 2.2). At approximately 53 mm (31–87 mm) from the origin of its course, the main trunk of the MFCA bifurcates into a deep branch and a



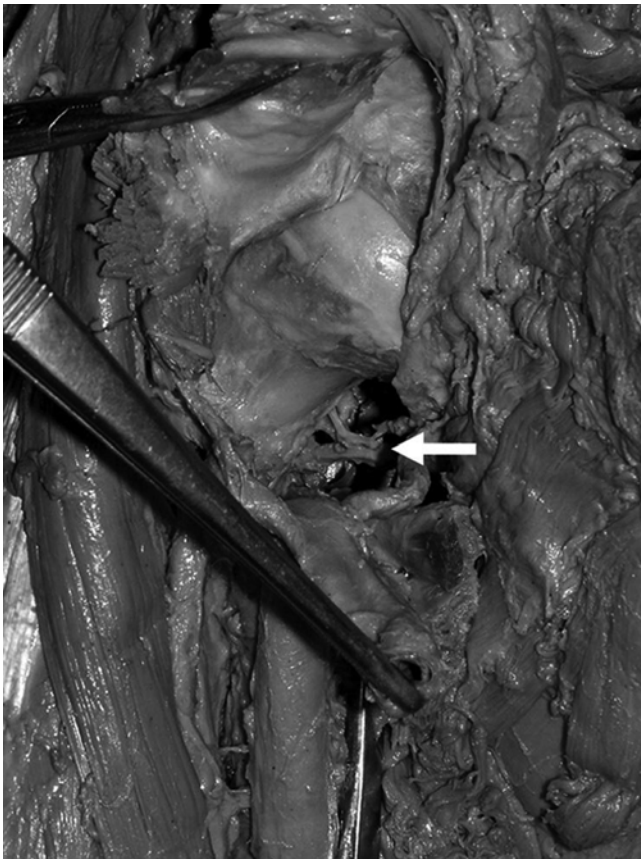
**Fig. 2.1** Photograph during cadaver dissection showing the anterior view of the right inguinal region, with the main trunk of the medial femoral circumflex artery (arrow) originating from the deep femoral artery. (Reproduced with permission and copyright © of the *British Editorial Society of Bone and Joint Surgery* [9])

descending branch. This typical bifurcation of the main trunk of the MFCA is characteristic of 96 % of the cases [9, 14, 19] (Figs. 2.3, 2.4, and 2.5).

The main trunk bifurcates into the descending branch, usually single with a diameter of 1.7 mm (0.8–3.6 mm) that divided into two branches, which supply the muscles of the posterior compartment of the thigh. The deep branch, with a diameter of 1.6 mm (1.1–2.7 mm), follows a course directed to the femoral head [7, 9, 14, 19] (Figs. 2.3, 2.4, and 2.5).

#### 2.4.1.1 Posterior Inferior Nutrient Artery

The posterior inferior nutrient artery of the femoral head is not present in all cases. Incidence of appearance depends on the method of visualization used by different authors; it is observed in 11 % of cases by angiographic CT examination [14] compared to 100 % of cases in a classical anatomical study with colored silicone injection [6, 11–13, 15]. Its diameter has been estimated in a microangiographic study to be approximately 0.4 mm (0.1–0.6 mm) [6]. In its intra-articular

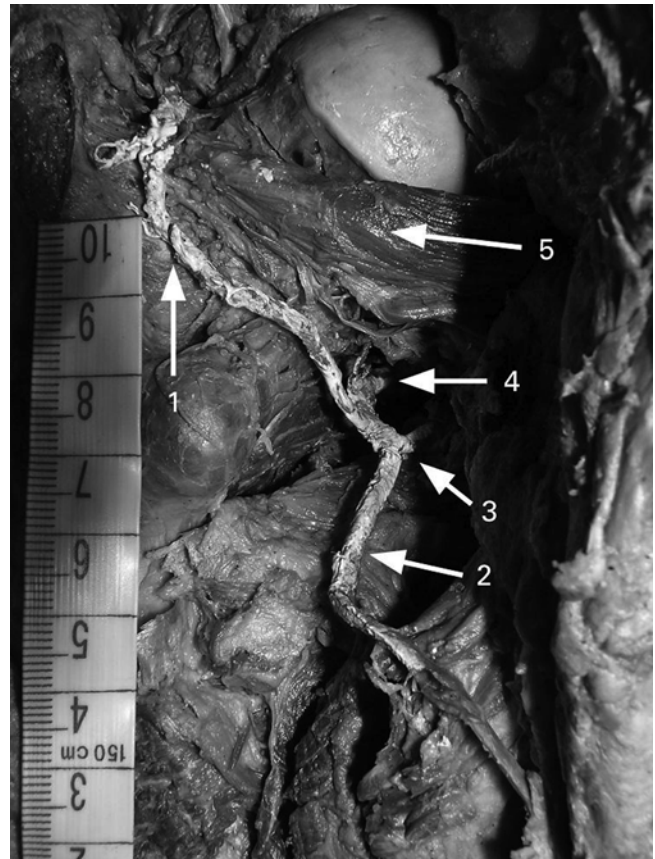


**Fig. 2.2** Photograph during cadaver dissection of the anterior view with the right femoral head partly exposed and the femoral neck showing the posterior inferior femoral head nutrient artery (white arrow) (Reproduced with permission and copyright © of the *British Editorial Society of Bone and Joint Surgery* [9])

course, it runs proximally on the medial aspect of the neck toward the femoral head on top of the mobile fold of tissue commonly referred to as the Weitbrecht ligament [12] (Figs. 2.2, 2.3, and 2.5). During the growth phase, the posterior inferior nutrient artery—under the name “inferior metaphyseal artery”—was found to supply approximately two-thirds of the metaphyseal tissue of the femoral head [8]. Almost 18 % of the vascular foramina around the head are located in the posterior inferior aspect of the femoral head in comparison to approximately 80 % located in the posterior superior and anterior superior quadrants of the femoral head [23].

#### 2.4.1.2 The Deep Branch with Posterior Superior Nutrient Arteries

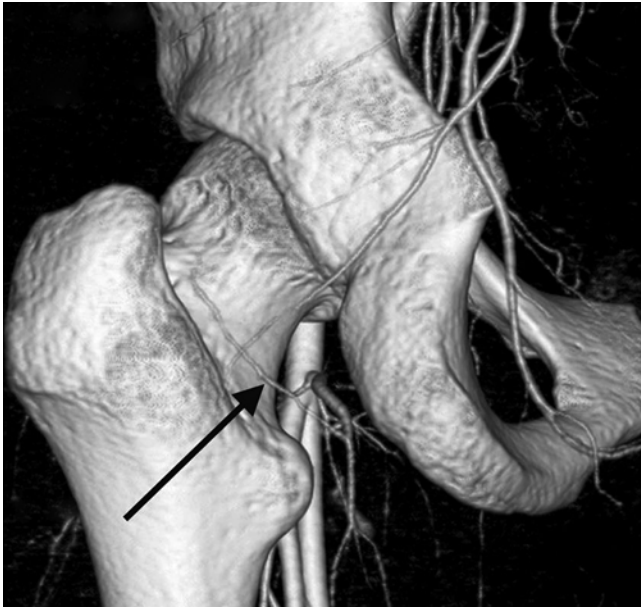
After bifurcation, the deep branch arises proximally, posterior to the obturator externus muscle and anterior to the quadratus femoris muscle. It is easily identifiable in the adipose tissue between these two muscles and is usually closely associated with two veins [9]. In this area, the deep



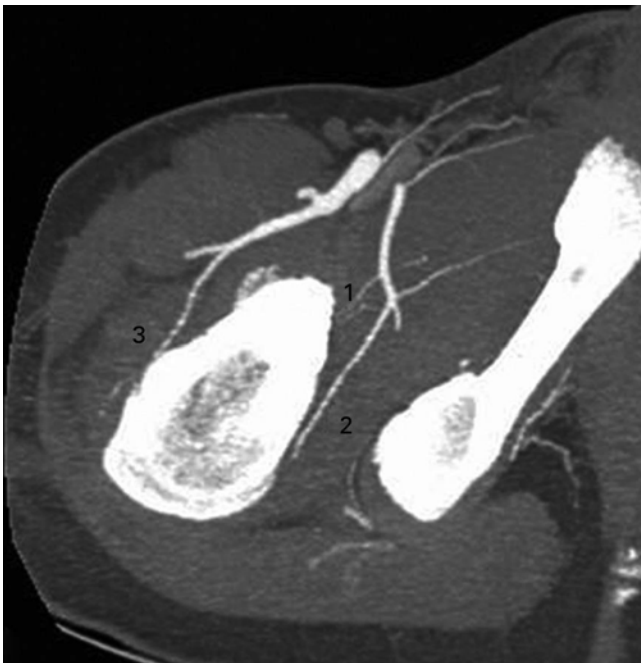
**Fig. 2.3** Photograph during cadaver dissection of the posterior view of the left hip joint with the femoral head partly exposed, showing the main branches of the medial femoral circumflex artery (MFCA): 1 deep branch, 2 descending branch, 3 bifurcation of the MFCA, 4 posterior inferior femoral head nutrient artery, and 5 obturator externus muscle (Reproduced with permission and copyright © of the *British Editorial Society of Bone and Joint Surgery* [9])

branch of the MFCA can rupture during traumatic hip dislocation when the obturator externus tendon ruptures. The obturator externus muscle and its tendon protects the vessel [10, 24] (Fig. 2.6). In that area, the deep branch is also at risk of iatrogenic damage during posterior exposure of the hip. During the Kocher-Langenbeck approach, division of the tendon of the obturator externus should be avoided. It is also unsafe to divide the distal part of the conjoint tendon comprised of the gemellus inferior and fibers of the obturator internus muscle [10]. After bypassing the obturator externus, the deep branch goes into the trochanteric fossa where it gives off trochanteric branches toward the greater trochanter [2, 10]. In this region, the deep branch of the MFCA anastomoses with the piriformis branch of the IGA. Moving in a cranial direction toward the femoral head, it lies anterior to the conjoint tendon of gemelli and obturator internus and enters the hip joint



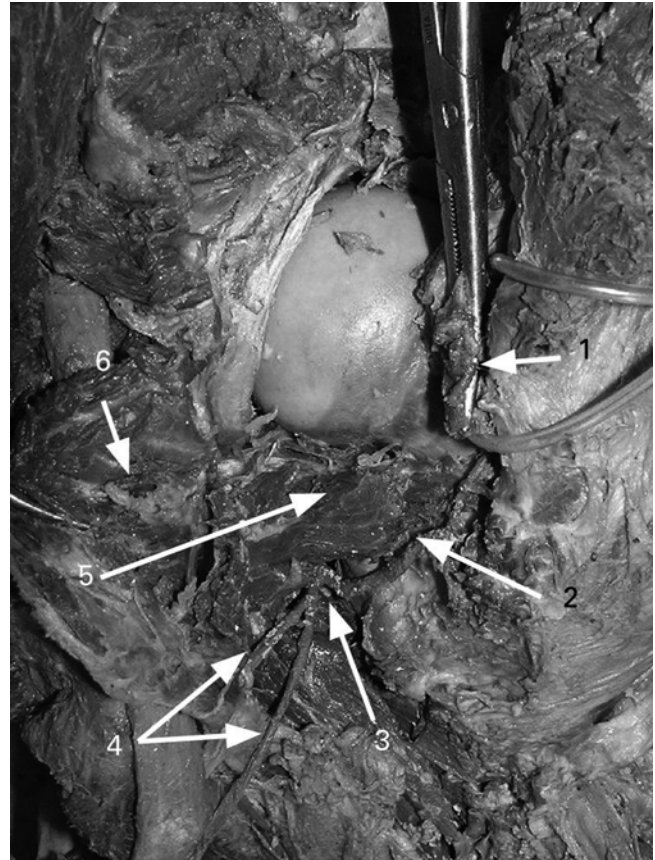


**Fig. 2.4** Volume rendering image of the angio-CT scans showing the deep branch of the medial femoral circumflex artery (arrow) from its bifurcation to its division into the posterior superior nutrient arteries (Reproduced with permission and copyright © of the *British Editorial Society of Bone and Joint Surgery* [14])



**Fig. 2.5** Maximum intensity projection image of the angio-CT scans showing the posterior inferior nutrient artery (1), the deep branch of the medial femoral circumflex artery (2), and the anterior nutrient artery of the femoral neck (3) (Reproduced with permission and copyright © of the *British Editorial Society of Bone and Joint Surgery* [14])

through a femoral attachment of the posterior capsule, superior to the insertion of gemellus superior and distal to the insertion of the piriformis [2, 9–11, 23]. On this course,

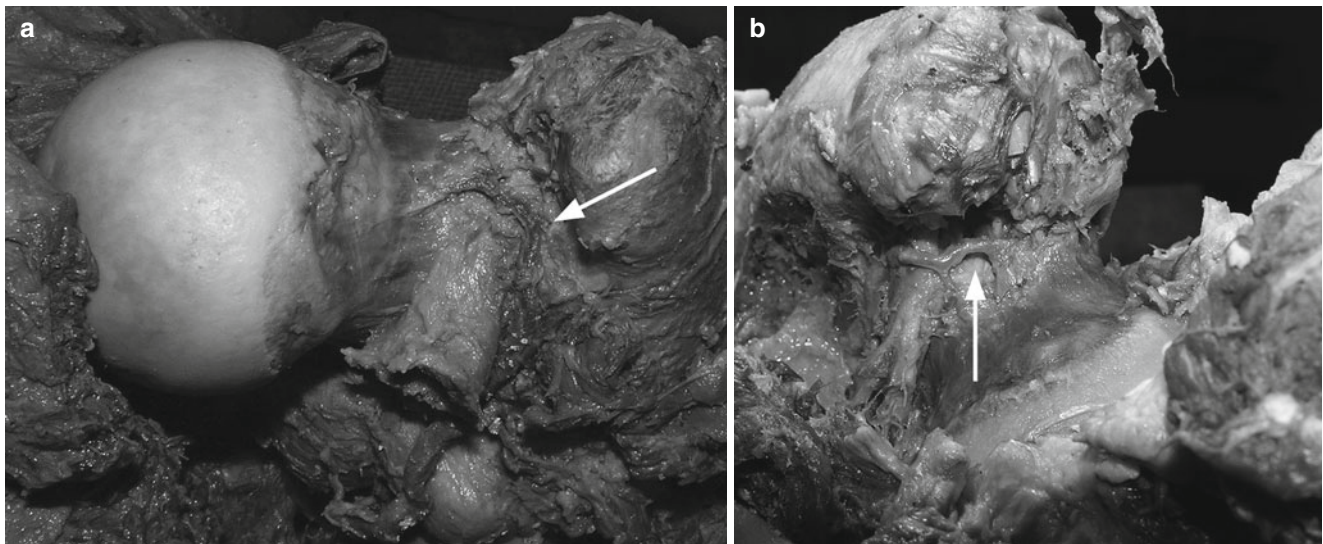


**Fig. 2.6** Photograph during cadaver dissection of the posterior view of the right hip joint, showing the topography of the deep branch of the medial femoral circumflex artery (MFCA): 1 conjoined tendon of the gemellus superior, gemellus inferior, and obturator internus muscles (after tenotomy near its femoral attachment), 2 deep branch of the MFCA, 3 bifurcation of the MFCA, 4 descending branches of the MFCA, 5 obturator externus muscle, and 6 quadratus femoris muscle (turned medially) (Reproduced with permission and copyright © of the *British Editorial Society of Bone and Joint Surgery* [9])

it becomes intracapsular, obliquely through the capsule. To protect the deep branch of the vessel, approximately 1.5 cm of the conjoined tendon and capsule should be left undivided from the trochanteric crest during posterior exposure of the hip [10]. During its intracapsular and intra-articular courses, the deep branch is at risk of stretching and increased vessel resistance because of intra-articular pressure [25].

Intra-articularly, it travels subsynovially along the femoral neck within the retinacular fibers.

In its intra-articular course, it divides into 1–5 posterior superior nutrient arteries of the femoral head, continuing within the retinaculum toward the femoral head [9, 10, 12] (Fig. 2.7a, b). Many authors agree that the deep branch divides into the terminal nutrient arteries in all cases [2–15]. Posterior superior nutrient arteries are the most important source of blood supply; they can completely perfuse the femoral head without any other vascular input [15]. The



**Fig. 2.7** Photographs during cadaver dissection of (a) a posterior view of the right hip joint with the femoral head exposed, showing the terminal branch of the medial femoral circumflex artery (*arrow*), which we consider to be the posterior superior femoral head nutrient artery, and (b) a posterior view of the left hip joint showing the terminal branches

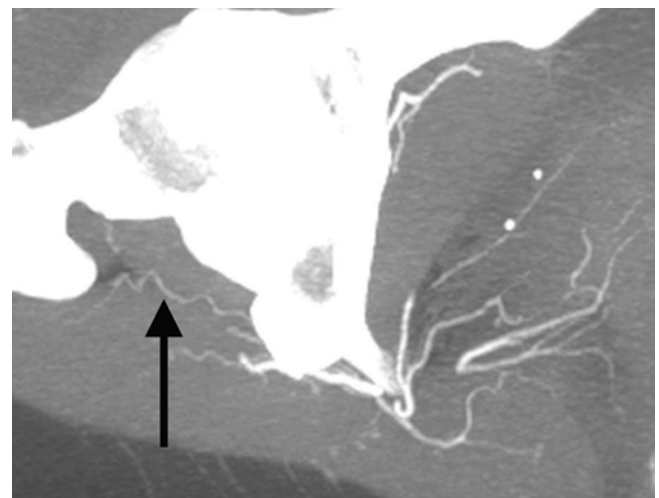
of the medial femoral circumflex artery (*arrow*), which we consider to be the three posterior superior femoral head nutrient arteries (Reproduced with permission and copyright © of the *British Editorial Society of Bone and Joint Surgery* [9])

estimated size, via microangiographic studies, of a nutrient artery from the group of posterior superior nutrient arteries of the femoral head in adults is 0.8 mm (0.3–1.6 mm) [6]. Zlotorowicz found that the deep branch was absent in 1/55 cases—the femoral head then being supplied by a well-defined piriformis branch of the IGA—using angiographic CT [14].

Based on the examination of 150 dried cadaveric specimens, Lavigne stated that 80 % of the vascular foramina on the bone were located in the posterior superior and anterior superior quadrants of the femoral head, where the posterior superior nutrient arteries enter the femoral head [23].

#### 2.4.2 Inferior Gluteal Artery

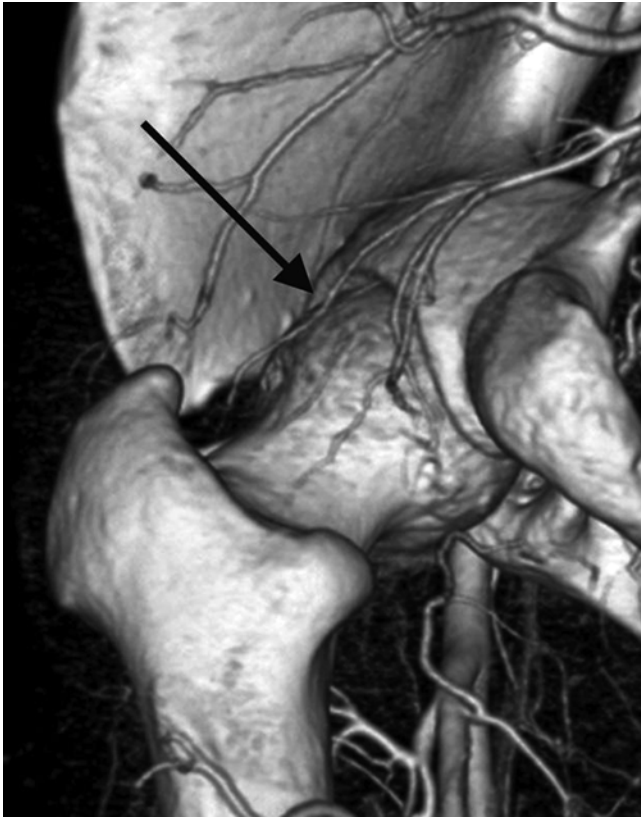The IGA also plays a crucial role in blood supply to the femoral head. Although all agree that the deep branch of the MFCA is a dominant vessel supplying the femoral head, the IGA was found to be a dominant vessel supplying the femoral head in >50 % of human fetuses aged 16–29 weeks of intrauterine life [17]. Kalhor found the piriformis branch of the IGA to be the main vessel supplying the femoral head in 6/35 specimens [12]. In another study, the piriformis branch of the IGA was also found to be the main vessel supplying the femoral head in the absence of the deep branch of the MFCA [14]. The most precise description of the anastomosis is given by Grose. In 7/8 specimens examined, constant anastomosis between the deep branch of the MFCA and the terminal branches of



**Fig. 2.8** Maximum intensity projection image of the angio-CT scans showing the piriformis branch (*arrow*) of the inferior gluteal artery (Reproduced with permission and copyright © of the *British Editorial Society of Bone and Joint Surgery* [14])

the IGA, called the piriformis branch, was observed. In this study, in all seven specimens observed, it was possible to inject the posterior superior nutrient arteries and posterior inferior nutrient artery via the IGA [18]. The piriformis branch of the IGA travels posteriorly across the piriformis and conjoint tendons, meeting the MFCA in the interval space between the inferior gemellus and the tendon of obturator externus (Figs. 2.8 and 2.9). The incidence of the piriformis branch varies depending on which method was used to visualize the vessel. Incidence varies from 49 % in





**Fig. 2.9** Volume rendering image of the angio-CT scans showing the piriformis branch (arrow) of the inferior gluteal artery with the terminal nutrient arteries supplying the femoral head in the absence of the deep branch of the medial femoral circumflex artery. The main trunk takes the direction of the descending branch (Reproduced with permission and copyright © of the *British Editorial Society of Bone and Joint Surgery* [14])

CT angiography, with the size 1.0 mm (0.5–1.8 mm), to 100 % in an anatomical study involving injection of the arteries with colored silicone [14, 18].

#### 2.4.3 Lateral Femoral Circumflex Artery

The LFCA arises from the deep femoral artery or, less commonly, from the femoral artery. It contributes to the femoral head and neck blood supply by a single artery with mean diameter 0.25–1.1 mm [6, 19]. This artery was found in 25–88 % of specimens [4, 6, 11, 12].

The anterior nutrient artery of the femoral neck is the vessel supplying the femoral neck rather than the femoral head. The vessel enters the bone at the anterior aspect of the femoral neck and is located at many different levels. In 39 % of specimens, it enters the bone immediately after piercing the capsule, in the middle of the neck in another 42 %, and near the articular rim in only 18 % [2]. In another study, the anterior nutrient artery enters the bone at a 22 mm distal to a 24 mm proximal point from the top of the lesser trochanter (mean distance, 4.5 mm proximal) (Fig. 2.5) [19].

The extracapsular and intracapsular arterial ring described by Chung, which is formed by the LFCA and MFCA, was not found by other authors [4, 7, 8, 10–12, 14].

Microangiographic studies showed that the anterior nutrient artery of the femoral neck does not supply the cancellous portion of the bone, but ends into the cortex forming a thicker peripheral meshwork [5, 15]. Some authors, in assessing the blood supply to the femoral head, do not describe the anterior nutrient artery as the vessel supplying the femoral head [2, 8].

#### 2.4.4 Obturator Artery with Terminal Artery of the Ligamentum Teres

The artery of the ligamentum teres arises either from the obturator or MFCA, or from both [6]. Although it functions during the growth phase as a medial epiphyseal artery, most authors agree that its contribution to the femoral head blood supply is minimal [2, 8, 10–12, 15]. On the other hand, studies show that the artery of the ligamentum teres anastomoses with the intraosseous arteries of the femoral head. The size of the anastomosis is estimated to be 0.33 mm (0.07–0.62 mm) and the incidence is approximately 70 % [6].

The passage of one or, less frequently, two small arteries through the ligamentum teres toward the femoral head is usually too small in diameter to permit demonstration of their passage to the femoral head in anatomical studies [2]. Experimental divisions of the ligamentum teres showed that cutting this ligament has no effect on the capital arterial pattern including the subfoveal part of the head.

When the artery of the ligamentum teres was considered the only vessel supplying the femoral head, contrast medium was not taken up by the capital vessels in 35 % of specimens; another 35 % showed uptake in a small subfoveal area, and 29 % in other capital arteries (one or two arteries from the posterior superior nutrient arteries). In one preparation, only 6 % of normal area of the head was observed [15].

Experimental studies, therefore, showed that the ligamentum teres artery is unimportant as a supply vessel in most femoral heads, but can occasionally provide supporting blood supply to the femoral head in some individuals.

#### 2.4.5 Superior Gluteal Artery

A branch of the superior gluteal artery descending toward the top of the greater trochanter, alongside the gluteus medius and minimus muscles, could potentially be a vessel anastomosing with the deep branch of the MFCA or with the piriformis branch of IGA. In 16 % of injected specimens, contrast penetrated to the top of the greater trochanter; however, the anastomosis was not visualized [11, 14]. Most authors do not consider the superior gluteal artery a main source of blood supply.

### 2.4.6 Transcervical Arteries from the First Perforator Artery

Most authors agree that vessels inside the marrow cavity of the femoral shaft and more proximally in the femoral neck are of no importance in blood supply to the femoral head [2, 8, 15]. On the other hand, it was possible for some authors to inject the nutrient arteries of the femoral head via the nutrient artery of the femoral shaft and vice versa [6, 26]. It is estimated that the anastomosis between a nutrient artery of the femoral shaft and nutrient arteries of the femoral head is 0.1–0.25 mm in diameter [6]. It is not possible to quantify the frequency at which the anastomosis occurs because of the presence of red marrow and a dense cloud of capillaries, making visibility poor in some specimens [6].

## 2.5 Summary

The femoral head receives blood supply mostly from the MFCA, with the deep branch of this artery being the most important. The deep branch of the MFCA terminates in the group of posterior superior nutrient arteries of the femoral head. The posterior superior nutrient arteries enter the femoral head via the vascular foramina in the posterior superior and anterior superior quadrants of the femoral head and neck. In these quadrants, 80 % of all femoral head vascular foramina are localized. The deep branch of the MFCA along with the terminal posterior superior nutrient arteries of the femoral head can support all, or nearly all, of the blood supply to the femoral head. Another source of blood supply, also originating from the MFCA, is the posterior inferior nutrient artery. From the anastomoses that contribute to the blood supply of the femoral head, the most important is the anastomosis with the IGA via the piriformis branch, which can also be a dominant vessel supplying the femoral head. The anterior nutrient artery of the femoral neck—originating from the lateral circumflex artery—and the obturator artery, via the artery of the ligamentum teres, constitute a minor component of the blood supply to the femoral head.

## References

- Hunter W. Of the structure and diseases of articulating cartilages. *Philos Trans R Soc.* 1743;43:514–21.
- Howe W, Lacey T, Schwartz R. A study of the gross anatomy of the arteries supplying the proximal portion of the femur and the acetabulum. *J Bone Joint Surg Am.* 1950;32-A:856–66.
- Crock H. A revision of the anatomy of the arteries supplying the upper end of the human femur. *J Anat.* 1965;99:77–88.
- Chung S. The arterial supply of the developing proximal end of the human femur. *J Bone Joint Surg Am.* 1976;58-A:961–70.
- Judet J, Judet R, Lagrange J, Dunoyer J. A study of the arterial vascularization of the femoral neck in adult. *J Bone Joint Surg Am.* 1955;37-A:663–80.
- Tucker F. Arterial supply of the femoral head and its clinical importance. *J Bone Joint Surg Br.* 1949;31-B:82–93.
- Müssbichler H. Arteriographic investigations of the normal hip in adults. Evaluation of methods and vascular finding. *Acta Radiol.* 1971;11:195–215.
- Trueta J. The normal vascular anatomy of the femoral head in adult man. 1953. *Clin Orthop Relat Res.* 1997;334:6–14.
- Zlotorowicz M, Szczodry M, Czubak J, Cizek B. Anatomy of the medial femoral circumflex artery with respect to the vascularity of the femoral head. *J Bone Joint Surg Br.* 2011;93-B:1471–4.
- Gautier E, Ganz K, Krugel N, Gill TJ, Ganz R. Anatomy of the medial femoral circumflex artery and surgical implications. *J Bone Joint Surg Br.* 2000;82-B:679–83.
- Kalhor M, Beck M, Huff T, Ganz R. Capsular and pericapsular contributions to acetabular and femoral head perfusion. *J Bone Joint Surg Am.* 2009;91-A:409–18.
- Kalhor M, Horowitz K, Gharehdaghi J, Beck M, Ganz R. Anatomic variations in femoral head circulation. *Hip Int.* 2012;22(3):307–12.
- Boraiah S, Dyke J, Hertrich C, Parker R, Miller A, Helfet D, Lorch D. Assessment of vascularity of the femoral head using gadolinium (Gd-DTPA) – enhanced magnetic resonance imaging. A cadaver study. *J Bone Joint Surg Br.* 2009;91-B:131–7.
- Zlotorowicz M, Czubak J, Kozinski P, Boguslawska-Walecka R. Imaging the vascularisation of the femoral head by CT angiography. *J Bone Joint Surg Br.* 2012;94-B:1176–9.
- Sewitt S, Thompson RG. The distribution and anastomoses of arteries supplying the head and neck of the femur. *J Bone Joint Surg Br.* 1965;47-B:560–73.
- Gray H. *Anatomy of the human body.* 20th ed. Philadelphia: Lea and Febiger; 1918.
- Jedral T, Anyzewski P, Cizek B, Benke G. Vascularization of the hip joint in the human fetuses. *Folia Morphol (Warsz).* 1996;4:293–4.
- Grose A, Gardner M, Sussmann P, Helfet D, Lorch D. The surgical anatomy of the blood supply to the femoral head. Description of the anastomosis between the medial femoral circumflex artery and inferior gluteal arteries at the hip. *J Bone Joint Surg Br.* 2008;90-B:1298–303.
- Zlotorowicz M, Czubak J. The anatomy of the medial femoral circumflex artery – chances for microsurgical reconstruction. Thesis. Medical Centre of Postgraduate Education, Warsaw, 2010.
- Tanieli E, Üzel M, Yildirim M, Çelik H. An anatomical study of the origins of the medial circumflex femoral artery in the Turkish population. *Folia Morphol.* 2006;65:209–12.
- Siddharth P, Smith NL, Mason RA, Giron F. Variational anatomy of the deep femoral artery. *Anat Rec.* 1985;212:206–9.
- Massoud T, Fletcher E. Anatomical variants of the profunda femoris artery: an angiographic study. *Surg Radiol Anat.* 1997;19:99–103.
- Lavigne M, Kalhor M, Beck M, Ganz R, Leunig M. Distribution of vascular foramina around the femoral head and neck junction: relevance for conservative intracapsular procedures of the hip. *Orthop Clin North Am.* 2005;36:171–6.
- Zlotorowicz M, Czubak J, Caban A, Kozinski P, Boguslawska-Walecka R. The blood supply to the femoral head after posterior fracture/dislocation of the hip, assessed by CT angiography. *Bone Joint J.* 2013;95-B:1453–7.
- Beck M, Siebenrock K, Affolter B, Nötzli H, Parvizi J, Ganz R. Increased intracapsular pressure reduces blood flow to the femoral head. *Clin Orthop Relat Res.* 2004;424:149–52.
- Wolcott WE. The evolution of the circulation in the developing femoral head and neck. An anatomic study. *Surg Gynecol Obstet.* 1943;77:61–8.

Osteonecrosis

Koo, K.-H.; Mont, M.A.; Gordon, M. (Eds.)

2014, XVIII, 514 p. 183 illus., 63 illus. in color.,

Hardcover

ISBN: 978-3-642-35766-4