
Introduction

Sculpting the human body in order to improve definition is impossible without a thorough knowledge of muscular anatomy. The surgeon must also develop an artist's eye so that the form ideally created by the superficial musculature can be “visualized” and then revealed through selective lipoplasty techniques [1, 2]. In most individuals with a normal body mass index, an athletic and toned appearance can be created through high-definition body sculpting by removing fat and highlighting major muscle groups [2]. The anatomy and form of the most important muscles and muscle groups for high-definition lipoplasty are detailed in this chapter. These include muscles of the trunk, shoulder, upper arm, hip, thigh, and leg. The salient features of the muscular anatomy relevant to body contouring are outlined, such as the origin, insertion, orientation, form created, and relationship to adjacent muscle groups.

Trunk Muscles

The trunk muscles consist of large and small groups arranged anteriorly and posteriorly over the abdomen and back, respectively. They also include the chest wall muscles. They form the muscular body wall, where they connect the rib cage to the bony pelvis. The trunk muscles have various actions on the torso, including flexion,

extension, lateral bending, and rotation. The definition of the trunk muscles provides an appearance of athleticism, strength, and health. In men, the posterior trunk muscles create a V-shaped form, or triangular wedge; the broad latissimus dorsi tapers inferiorly to a narrow waist (Fig. 2.1). Anteriorly, the fleshy bellies of the rectus abdominis bulge between tendinous intersections, and the pectoralis major provides a convex muscular mass over the chest (Fig. 2.2). In women, the anterior and posterior trunk muscles between the rib cage and pelvis narrow the waist. Posteriorly, the broad V shape is lacking, but the smaller erector spinae provide attractive definition on either side of the midline (Fig. 2.3). Anteriorly, a subtle shadow over linea alba and at the lateral borders of the rectus abdominis creates beautiful definition of the female abdomen (Fig. 2.4) [2].

Rectus Abdominis

This vertically oriented paired strap muscle occupies most of the central part of the anterior abdominal wall (Fig. 2.5). It is narrow and thick inferiorly and broader and flatter in the upper abdomen. The rectus abdominis arises from the symphysis, crest, and pecten of the pubis and runs upward to insert into the xiphoid process and costal cartilages of the fifth to seventh ribs. Its main action is to flex the trunk. The inferior part of the rectus abdominis is covered only on its anterior surface by the rectus sheath, and above the costal margin, the muscle lies directly



Fig. 2.1 The posterior male trunk. A “V” shape is produced by the back muscles tapering inferiorly to a narrow waist



Fig. 2.3 Definition and form of the female back. Note the midline groove between the spinous muscles and the dimples in the lower back marking the location of the posterior superior iliac spines



Fig. 2.2 Anterior male abdomen. The major muscle groups and their tendinous intersections create a highly defined appearance



Fig. 2.4 Anterior female abdomen. The most defining features in the athletic female abdomen are the linea alba and linea semilunaris

on the costal cartilages. The paired rectus abdominis is separated in the midline by the linea alba and by three horizontal tendinous intersections. These fibrous bands are usually located at the level of the xiphoid process, at or just above the umbilicus, and halfway between these two. A fourth tendinous intersection may

be visible below the umbilicus and marks the location of the arcuate line. The tendinous intersections on one side may be in line with the contralateral side or may be at different levels, giving an asymmetrical appearance to the anterior abdominal musculature. The intersections closest to the umbilicus tend to run horizontally,

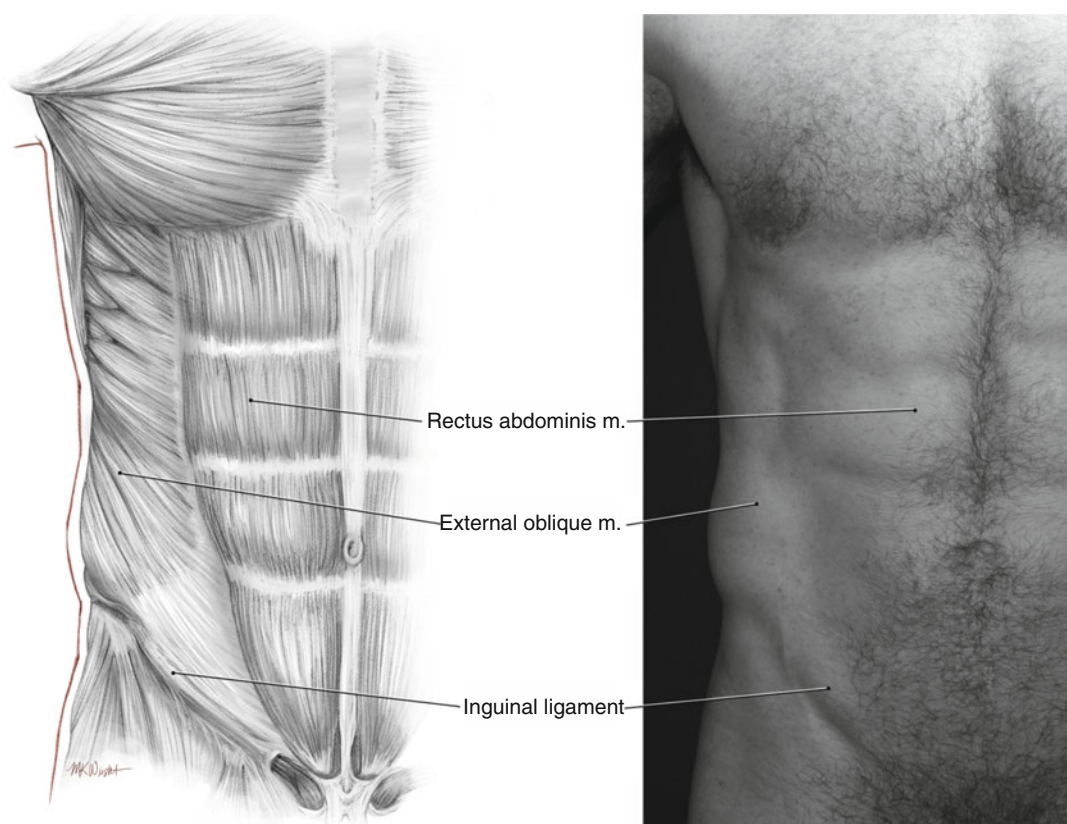


Fig. 2.5 Rectus abdominis. This represents the most important muscle in high-definition body sculpting of the anterior abdominal wall

whereas the uppermost tendinous intersections often run more diagonally. The orientation of tendinous intersections is highly variable, and all may be horizontal. Careful palpation of the anterior abdominal wall in slim individuals confirms the surface anatomy. The intersections divide the muscle into segments of fleshy protruding bellies that create the quintessential muscular male abdomen commonly referred to as the six-pack [2]. The superior borders of the upper segments usually coincide with the inferior margin of the pectoralis major, but variations exist. The muscle may continue superiorly under the pectoralis major or may end lower down, exposing the costal cartilages and creating a depression between the lower border of the pectoralis major and the superior border of the rectus abdominis. The borders of the segments created by the intersections are rounded. The

lateral border of the rectus abdominis is often visible as a vertical groove in the anterior abdominal wall between the ninth costal cartilage and the pubic tubercle. This semilunar line typically runs along a line drawn from the mid-point of the clavicle to the middle of the thigh. It starts superiorly as a depression just below and medial to the nipple in men, runs inferiorly between the anterior limits of the muscular part of the external oblique and the lateral border of the rectus abdominis, and expands into a triangular area over the aponeurosis of the external oblique above the inguinal ligament. In the midline, diastasis or separation of the recti muscles with widening of the linea alba occurs following pregnancy or as a congenital deformity and may result in an abnormally convex abdominal contour. Plication of the anterior or posterior rectus sheath, sometimes combined with plication of

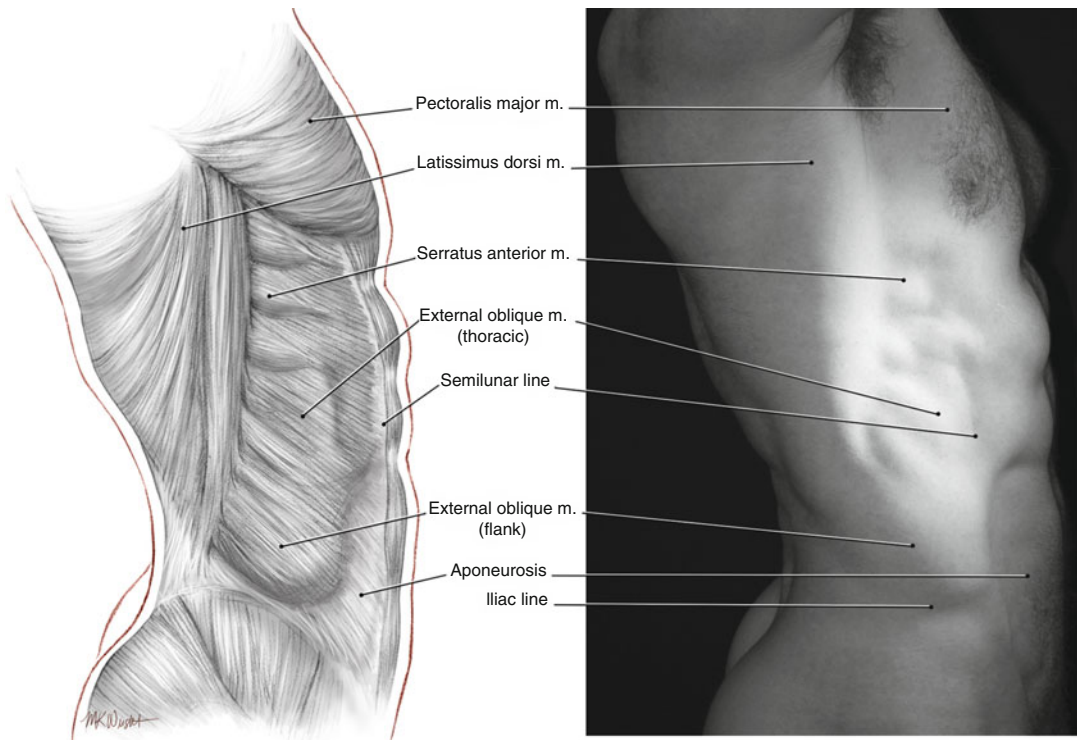


Fig. 2.6 The lateral abdominal wall. The external oblique muscle predominates, superiorly as the thoracic portion and inferiorly as the less well-defined flank portion

the external oblique aponeurosis, improves this myoaponeurotic deformity [3]. When the body is hyperextended, stretching the skin and muscle over the rib cage, a thoracic arch is easily seen where the costal cartilages meet the sternum in the midline. Even at rest, this may be seen in females and in thin individuals. The arch forms an angle of approximately 90° in males and 60° in females. In males, a more rounded arch is created by the costal margin laterally and the highest tendinous intersection of the rectus abdominis medially. The umbilicus or navel lies within a defect in the linea alba, opposite the fourth lumbar vertebra, and about midway between the xiphoid process and symphysis pubis. In athletic males, a sharp rim is usually present at the upper border of the umbilicus, whereas the lower border is less well defined. In females, a periumbilical fat pad deepens the navel and obscures its borders.

External Oblique

This muscle forms the fleshy part of the lateral abdominal wall as its fibers pass inferiorly and inferomedially superficial to the other flat muscles (Fig. 2.6). It originates from the external and inferior surfaces of the lower 7–8 ribs. The external oblique has two parts: an upper thoracic portion and a lower flank portion. The thoracic portion consists of separate elongated bundles of muscle that run parallel to one another and in a straight line from the external surfaces of the ribs to their aponeurosis at the semilunar line. The lower fibers of the thoracic portion form a transitional zone above the flank portion that coincides with the waist. The anterior edge of the thoracic portion of the external oblique is jagged or irregular where it inserts into its own aponeurosis as separate bundles. The flank portion of the muscle runs from the external surfaces of the inferior

ribs to the anterior half of the lip of the iliac crest posteriorly and the external oblique aponeurosis and linea alba anteriorly. The flank pad represents a fleshy trapezoid between the ribs and pelvis that wraps around the waist. This comprises the flank portion of the external oblique anteriorly and a flank fat pad posteriorly. Even with good muscular development, external oblique muscle fibers are not visible in the smooth, convex flank pad. The inferior margin of the flank pad is the iliac line. Since the muscle fibers of the external oblique insert into the iliac crest, an iliac line lower than this is created by ptotic fat, and not muscle. The most posterior fibers of the flank portion of the external oblique pass vertically from the lower two ribs to insert into the iliac crest, creating a posterior free border. These fibers do not insert into the thoracolumbar fascia and constitute the anterior border of the inferior lumbar triangle of Petit, with posterior and inferior borders formed by the latissimus dorsi and iliac crest, respectively. Unusual cases of herniation through Petit's triangle have been reported [4]. This triangle is usually covered with the fat pad. The external oblique becomes aponeurotic medially at the midclavicular line and inferiorly at the spinoumbilical line (between anterior superior iliac spine and umbilicus). The aponeurosis passes anterior to the rectus abdominis as part of the rectus sheath and decussates with aponeurotic fibers of the contralateral external oblique, internal oblique, and transversus abdominis at the midline. The external oblique aponeurosis passes the midline to be continuous with the aponeurosis of the contralateral internal oblique. Functionally, the external oblique and the contralateral internal oblique can be considered as a digastric muscle, since their simultaneous action flexes and rotates the abdomen, as occurs when the shoulder is turned toward the contralateral hip. The inferolateral fibers of the external oblique, below the spinoumbilical line, turn backward and upward between the anterior superior iliac spine and the pubic tubercle to form the inguinal ligament. A triangular tendinous expansion occurs just below the spinoumbilical line and lateral to the rectus abdominis. There may be a slight groove above and parallel

to the inguinal ligament in this area created by the internal oblique muscle lying beneath. The tip of the tenth rib marks the base of the rib cage and the superior limit of the abdominal portion of the external oblique [5]. A small triangular depression along the semilunar line occurs here in athletic people. Subdermal lipoplasty is used to create a controlled depression in this area to enhance definition of the anterolateral abdominal wall.

Serratus Anterior

This quadrilateral muscle originates anteriorly as fingerlike bundles from the external surfaces of the upper 8–9 ribs and wraps around the rib cage to insert into the vertical, medial edge of the scapula. It acts to draw the scapula laterally and around the rib cage, as in punching. The inferior part of the muscle rotates the tip of the scapula laterally, raising the arm. In muscular individuals, the anterior parts of the lowest 3–4 digitations of the serratus anterior can be seen on the lateral chest wall as they mingle with fibers of the external oblique (Fig. 2.7). The superior bundle is usually seen immediately below or at the inferior margin of the pectoralis major. The digitations of the serratus anterior are easily distinguished from the external oblique as thicker, more pronounced bundles of muscle that are oriented more horizontally relative to the fibers of the external oblique. A line drawn from the male nipple to the posterior superior iliac spine approximates the anterior extent of the visible portion of the serratus anterior over the torso as seen in profile view [5]. The rest of the serratus anterior is hidden from view by the pectoralis major superiorly and the latissimus dorsi posteriorly or is present between the two where it forms the medial wall of the axilla. Posteriorly, the mass of the serratus anterior can be appreciated where it bulges underneath the flat latissimus dorsi muscle that covers it. Its posterior limit sometimes extends more medial to the scapula where its fibers insert into part of the rhomboid major. Defining the serratus anterior plays an important role in high-definition body sculpting in male patients.

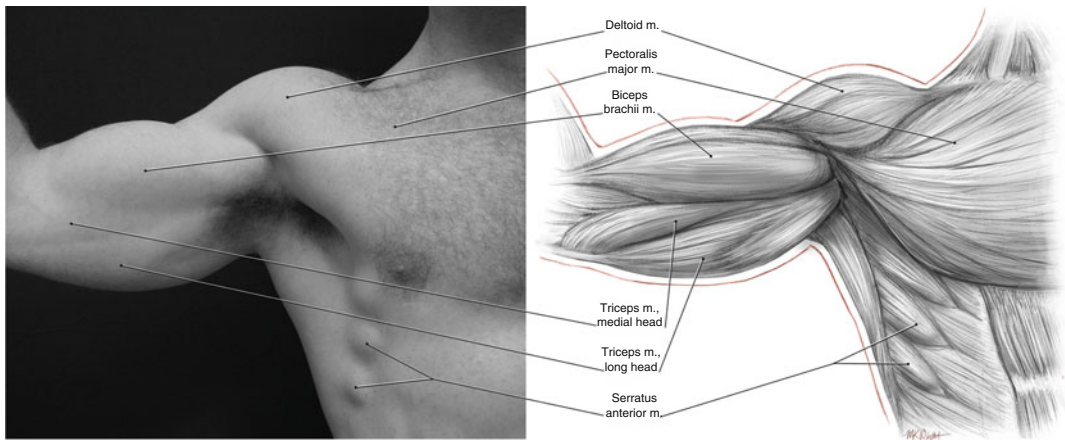


Fig. 2.7 The superolateral abdominal wall. The serratus anterior is clearly visible as three bulging slips of muscle below the lateral aspect of pectoralis major

Pectoralis Major

The pectoralis major forms most of the muscle bulk of the chest and gives the chest a smooth, convex form, particularly when the muscle is well developed (Fig. 2.8). It originates from the medial half of the clavicle, anterior surface of the sternum, costal cartilages of the first 6–7 ribs, and inferiorly the superior part of the external oblique aponeurosis of the abdomen. Based on its origin, the pectoralis major can be divided into clavicular, sternocostal, and abdominal portions. All portions of the pectoralis major insert into the lateral lip of the intertubercular groove on the anterior surface of the humerus. The clavicular portion arises from the clavicle and its fibers pass laterally and downward until they are adjacent to and parallel with fibers of the deltoid. Here the muscle bundle of the clavicular portion passes over other portions of the pectoralis major. The sternocostal portion passes almost horizontally, and the abdominal portion passes upward and laterally, deep to the other portions. Depending on the position of the arm, the pectoralis major adducts, rotates forward, flexes, and extends the humerus. Superiorly, the muscle tends to be flatter against the rib cage, whereas the inferior part of the muscle has more mass and provides a smooth convexity. The inferior margin of the

pectoralis major is straight and horizontal or slightly downward sloping from medial to lateral. There is a rounded sweeping form laterally as the muscle passes upward toward the axilla. This may be interrupted by a separate curvature created by the abdominal portion of the muscle as it arises from the abdominal aponeurosis and passes toward and then beneath the sternocostal portion of the pectoralis major. A pectoral fat pad near the nipple contributes to the volume and anterior convexity of the chest. Laterally, the muscle forms the anterior wall of the axilla. Between the clavicular portion and deltoid, there is a triangular fossa, the deltopectoral fossa. A groove continues from this inferolaterally between the two muscles as the deltopectoral groove, in which lies the cephalic vein. In the midline, there is a medial depression or groove over the sternum between the insertions of both pectoralis major muscles. This is more pronounced in muscular individuals. As the origin of the muscle moves away from the midline inferiorly, the space between the left and right pectoralis muscles forms a triangular depression above the xiphoid process. Techniques used to contour the chest in males include adding volume to the clavicular portion with fat grafting and defining the borders of the sternocostal portion by removing fat in the upper abdomen and toward the axilla.

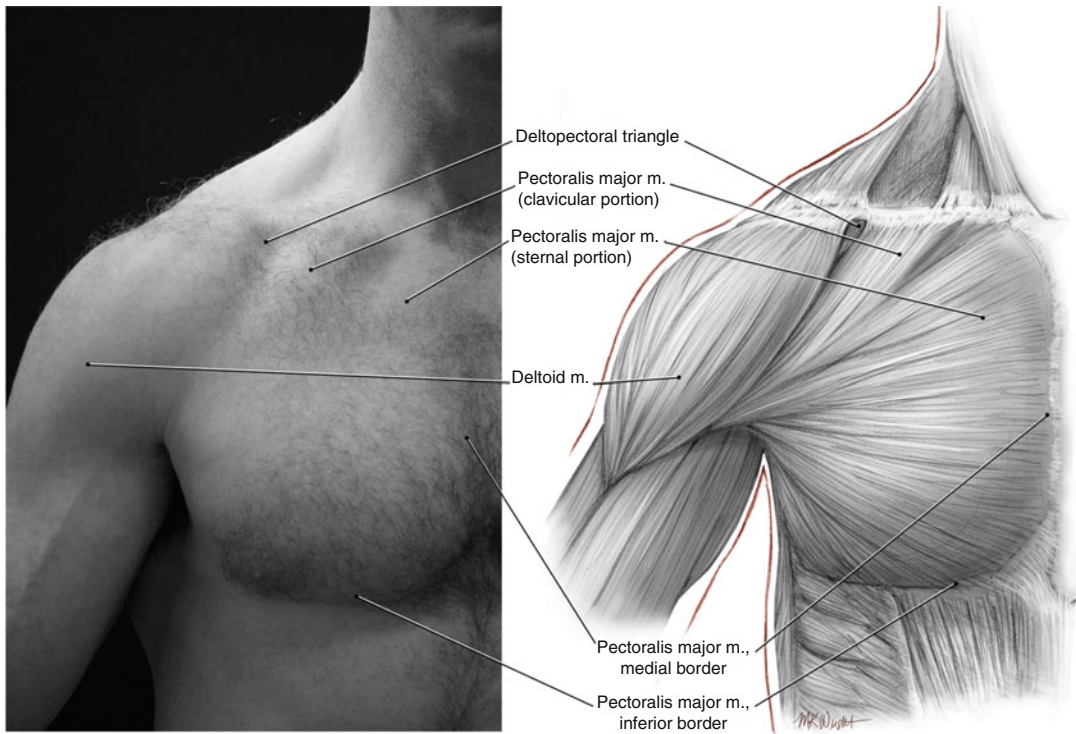


Fig. 2.8 Pectoralis major. This muscle forms the mass of the male chest

Latissimus Dorsi

The latissimus dorsi is a triangular sheetlike muscle that passes from the midline to the arm like a cape, covering the deeper muscles of the mid and lower back (Fig. 2.9). It originates from the spinous processes of the seventh to twelfth thoracic vertebrae, those of all of the lumbar and sacral vertebrae, the posterior one-third of the iliac crest, and the external surfaces of the lower three ribs. The muscle bundles converge toward the axilla and insert via a tough, square tendon into the proximal humerus proximal to the insertion of the pectoralis major. As they converge, they wrap around the teres major, forming a sling that forms the posterior wall of the axilla. The teres major forms part of that wall but appears superior and lateral to the latissimus dorsi on frontal view. The form created by both latissimus dorsi muscles is that of an inverted triangle or “V.” The upper fibers of the latissimus dorsi pass horizontally from the midline and form the superior free edge of the muscle as they pass laterally at about

the same level as the inferior margin of the pectoralis major anteriorly. They cover the tip of the scapula, teres major, and serratus anterior. The tendon of origin of the latissimus dorsi creates a line or curve from the midline over the thoracic vertebrae to the crest of the ilium. The latissimus dorsi and its tendon are draped over the deeper muscles, including the erector spinae, teres major, and serratus anterior. When these muscles contract or when the latissimus dorsi is stretched over them, their form is seen as bulges and shadows beneath. The lateral border of the latissimus dorsi extends upward and laterally from the waist. Although the form of the muscle is normally evident in its middle and superior portion, inferiorly, the dorsal fat pad obscures both it and the inferior flank portion of the external oblique.

Erector Spinae

The erector spinae comprises a group of muscles that fill the gutter on either side of the vertebral

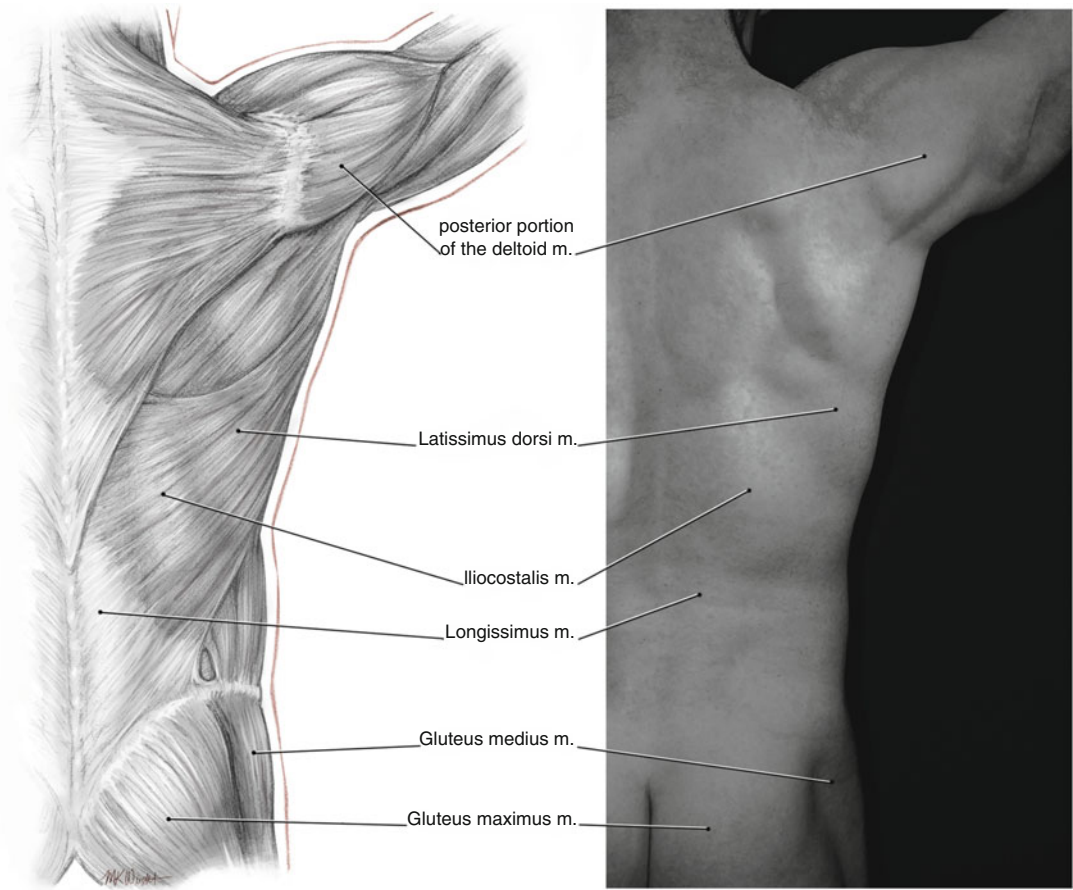


Fig. 2.9 Muscles of the back. In men, the latissimus dorsi contributes to the “V”-shaped form

column. The erector spinae group is mostly tendinous at its origin, becomes thick and fleshy in the lower back, and then tapers to form several thin slips of muscle before they end at their insertion points along the ribs and vertebrae. From lateral to medial, the erector spinae consists of the iliocostalis, longissimus, and spinalis (Fig. 2.9).

The iliocostalis forms a lateral muscle mass in the lower back. It originates from the posterior third of the iliac crest, from the lateral and median crests of the sacrum, and—through the erector spinae aponeurosis—from the spinous processes of the lumbar vertebrae. The iliocostalis has three portions, according to insertions. The iliocostalis lumborum inserts into the posterior aspects of the inferior six ribs. The iliocostalis thoracis contains muscle slips that run from the inferior six ribs to

the first six ribs, and the iliocostalis cervicis runs from the first six ribs to the transverse processes of C6–C4 [6]. The form of the iliocostalis lumborum can often be appreciated through the thin anterior layer of thoracolumbar fascia that covers it.

The longissimus lies medial to the iliocostalis and also contains three portions: thoracis, cervicis, and capitis. The longissimus thoracis runs from the medial part of the posterior iliac crest and from the spinous processes of L3 to the sacrum and inserts into the base of transverse processes L1 to L5 and to the tips of transverse processes T1 to T12 as well as to the adjacent ribs. Slips from the longissimus cervicis and longissimus capitis pass to the cervical processes and mastoid process, respectively. Like the

iliocostalis and longissimus, the spinalis comprises three parts, although this muscle is thinner and less consistent. The spinalis runs close to the midline with its lowest extent reaching L3. As such, it does not contribute significantly to the surface anatomy and form of the lower back.

Multifidus

The multifidus is a fleshy muscle that fills the space on either side of the midline between the spinous and transverse processes. It stabilizes the vertebral column and assists in extension, lateral flexion, and rotation of the back. The multifidus contributes to the elongated mass in the lower back on either side of the midline where it lies deep to the longissimus and spinalis.

Shoulder and Arm

The main prominence of the shoulder is attributed to the muscular mass of the deltoid that cups the shoulder joint. There is a seamless progression from the definition of the chest to the shoulder as the clavicular portion of the pectoralis major lies alongside and almost blends with the anterior portion of the deltoid. In turn, the middle portion of the deltoid points downward toward the upper arm muscles that lie on either side of its insertion. The major muscles of the shoulder and

arm should not be ignored when sculpting the chest and torso.

Deltoid

This triangular muscle has three parts: anterior, middle, and posterior. The anterior portion originates from the lateral third of the clavicle, the middle portion from the acromion, and the posterior part from the inferior surface of the spine of the scapula. All portions insert into the deltoid tuberosity on the midportion of the humerus. The deltoid raises the arm anteriorly, laterally, and posteriorly. The anterior portion is usually well defined as a distinct teardrop-shaped muscle, separated from the pectoralis major by the deltopectoral triangle and groove (Fig. 2.8). There is a less well distinct groove between the anterior and middle portions of the deltoid. The middle portion gives the shoulder a rounded appearance on front view and inserts lower than the anterior and posterior parts. The posterior portion is visible as a mass that separates the deltoid from the long and lateral heads of the triceps (Fig. 2.10). The tendon of the clavicular portion of the pectoralis major passes under the tendon of the anterior portion of the deltoid. The latter inserts into the deltoid tubercle on the anterior surface of the humerus. The other two parts of the deltoid insert into the lateral aspect of the humerus. When the arm is rotated medially or laterally, the shape and

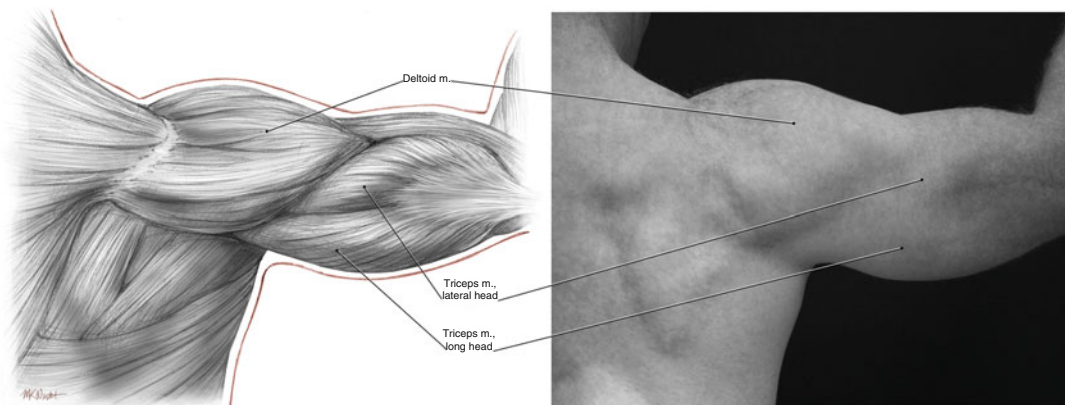


Fig. 2.10 Posterior view of the shoulder muscles. The deltoid is a prominent mass and separated from the arm extensors by a distinct groove

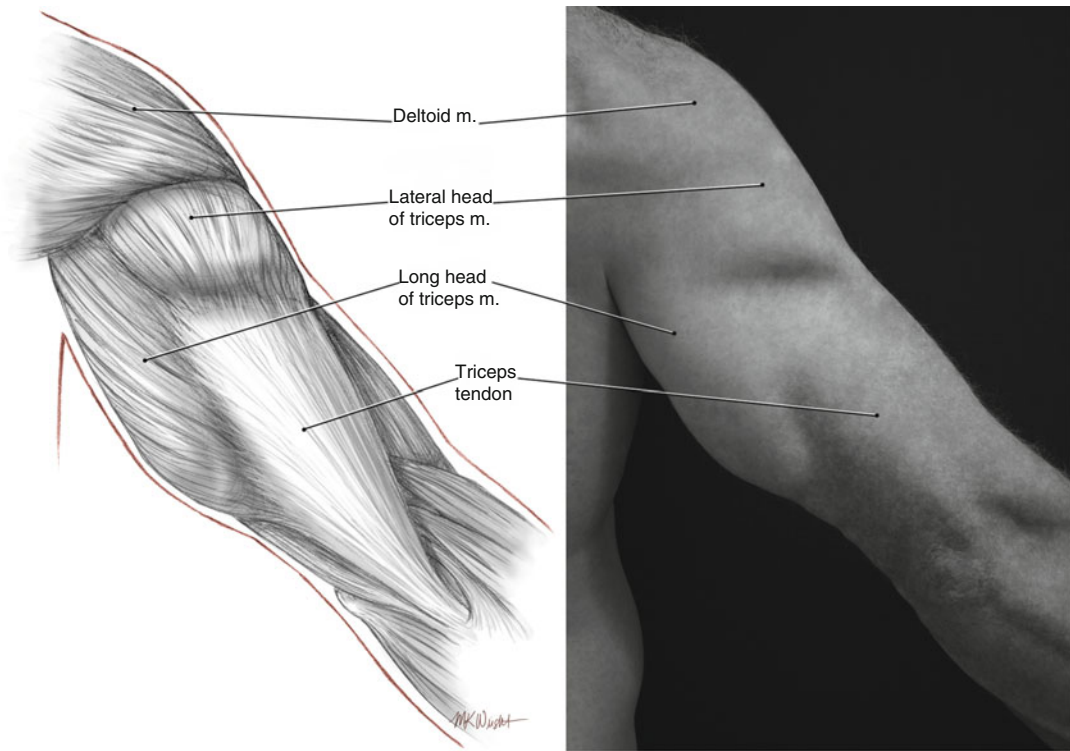


Fig. 2.11 Muscles of the posterior aspect of the upper arm. Note the grooves between the deltoid and the triceps and between the long and lateral heads of the triceps and their tendon

form of the deltoid changes slightly as the insertion points twist and the muscle moves accordingly. Unlike the anterior and posterior portions, the middle portion of the deltoid is multipennate. Tendon branches within the muscle and muscle fascicles attach obliquely to the tendons. In slim, muscular individuals, the muscle bundles can be seen to interdigitate diagonally, producing a segmented appearance over the lateral aspect of the shoulder. The definition and rounded form of the deltoid is enhanced during high-definition lipoplasty from incision access sites at the anterior and posterior axillary folds.

Triceps

The large triceps muscle consists of three heads: long, lateral, and medial. The long and lateral heads provide most of the surface form of the posterior upper arm and form a prominent bulge just distal to the rounded contour of the deltoid

(Fig. 2.11). The medial head lies deeply and contributes to the volume and thickness of the arm. The long head of the triceps arises from its tendon between the teres major and teres minor, below the glenoid fossa of the scapula. It crosses the shoulder joint and forms the main mass of the posterior upper arm. Proximally, tendinous fibers from the scapula compress the long head when it is contracted, visibly dividing the belly of the muscle into anterior and posterior parts on the inner surface of the arm (Fig. 2.7). The long head inserts into the upper medial edge of the large flattened tendon of insertion of the triceps. The lateral head originates from the proximal posterior surface of the humerus and is easily visible as a mass on the lateral aspect of the arm near the deltoid. It inserts high up into the flat, rectangular triceps tendon. A thin part continues to run down along adjacent to the lateral part of the triceps tendon, creating a taillike form when the arm is tensed. All of the triceps heads insert via their tendons into the posterior aspect of the proximal

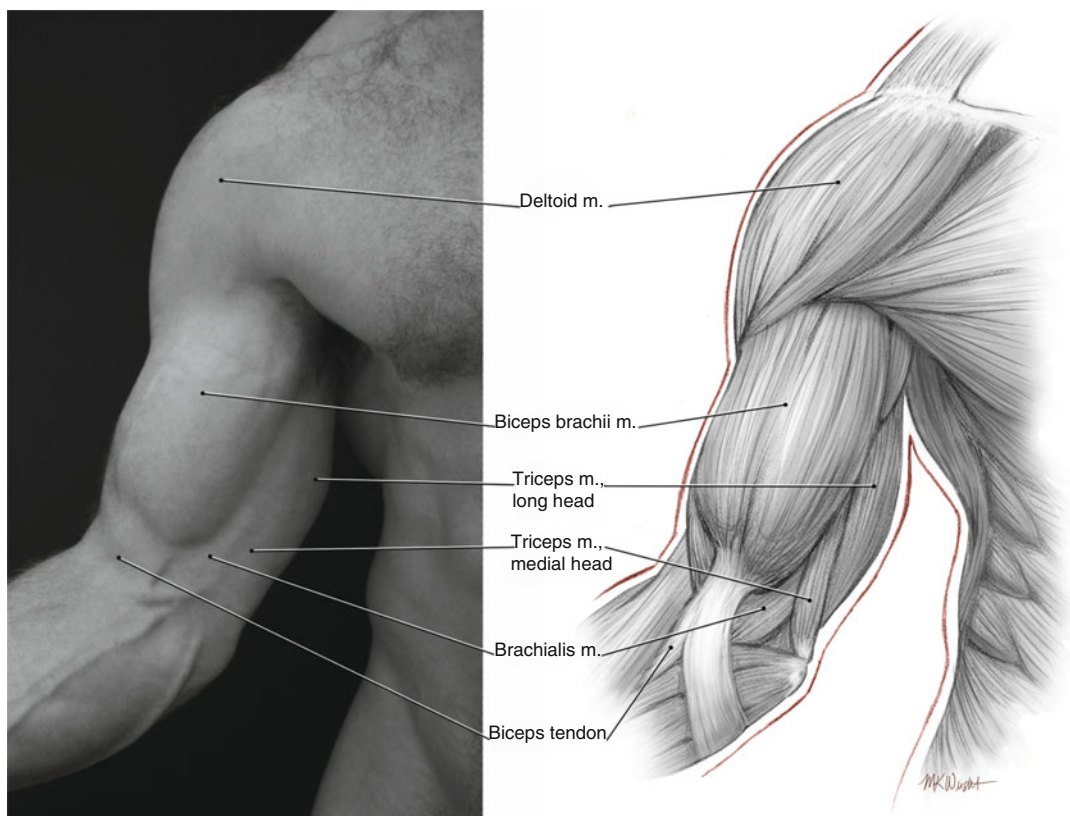


Fig. 2.12 Arm flexors. The biceps brachii forms the most defined mass on the anterior arm. The brachialis provides mass from beneath

olecranon. A cylindrical form that comprises part of the medial head of the triceps can be appreciated on the inner surface of the arm where it emerges from between the biceps brachii and the long head of the triceps about halfway down the arm (Fig. 2.7). It is possible to enhance the groove between the medial head and the biceps anteriorly and the medial head and the long head of the triceps posteriorly using very superficial and delicate ultrasound-assisted lipoplasty in this area.

Biceps

The prominent convex form over the anterior aspect of the upper arm is provided mostly by the mass of the biceps brachii (Fig. 2.12). When well developed, the biceps brachii typifies strength, athleticism, and aesthetically ideal upper arm form. The long head of the biceps originates from

the supraglenoid tubercle of the scapula. The short head originates from the coracoid process of the scapula. The biceps brachii emerges from beneath the pectoralis major and creates a groove between the two muscles, particularly when the arm is abducted and externally rotated. This groove is often accentuated by high-definition sculpting to highlight the separation between the muscles. The long and short heads of the muscle travel over the humerus but do not attach to it. Instead, they insert into the tuberosity of the radius via the biceps tendon deep between the flexors and extensors of the forearm. The two heads of the biceps brachii usually appear as one bulging form over the upper arm, although sometimes the separation between the two heads can be seen running longitudinally over the muscle just medial to the cephalic vein. In the inner part of the arm, the belly of the short head of the biceps creates a convex prominence that is

directed toward the axilla. As the short head emerges from underneath the pectoralis major, it is joined by the coracobrachialis on its medial side. The coracobrachialis is a cylindrical muscle that runs from the coracoid process to the medial aspect of the midportion of the humerus. In the middle third of the arm, the biceps brachii is separated by a groove from the long head of the triceps and the medial head of the triceps more distally. The neurovascular bundle lies within the brachial fascia deep to the groove. When the arm is flexed to 90° and supinated, the rounded inferior margin on the biceps brachii is prominent. With flexion against resistance, the bicipital aponeurosis becomes prominent as a thin sharp tendinous sheet that crosses from the biceps brachii over the medial aspect of the elbow. This aponeurosis passes medially and wraps around the forearm flexors.

Brachialis

The brachialis provides width to the flexor half of the upper arm. It is a broad flat muscle that lies on the humerus behind the biceps brachii. The brachialis originates from the anterior lower part of the humerus and crosses the elbow joint to insert into the coronoid process of the ulna. On anterior view, the brachialis is seen to protrude laterally from behind the biceps brachii (Fig. 2.12). A depression or groove at the superolateral origin of the brachialis on the humerus marks the junction of the brachialis and the deltoid. Closer to the elbow, its medial fibers form the floor of a concave space bordered anteriorly by the bicipital aponeurosis and posteriorly by the medial head of the triceps. The brachial vessels occupy this space.

Thighs and Hips

In properly selected patients, superficial lipoplasty to create controlled depressions between major muscle groups enhances definition and improves the aesthetics of the lower limb. Autologous fat grafting into and around the hip

muscles plays an important role in gluteal sculpting and in improving the silhouette and waist-hip ratio in female patients. The major muscles that should be considered in contouring and sculpting the hip region and lower limb are described in this section.

Gluteus Maximus

The gluteus maximus contributes to the convexity of the posterior buttocks and forms most of the buttock volume in slim individuals (Fig. 2.13). It originates from the posterior gluteal line of the inner upper ilium (from the iliac crest), the posterior lateral surface of the sacrum, the coccyx, and the sacrotuberous and sacrospinous ligaments. Most of the muscle fibers run inferolaterally, curving around the hip to insert into the iliotibial tract. Deep fibers from the lower portion of the muscle insert into the gluteal tuberosity on the posterior proximal surface of the shaft of the femur. The muscle bulk creates a convex form posteriorly that contributes to the desirable “S” curve formed by the gluteus maximus and the lumbar lordotic curve superiorly (Fig. 2.14). A depression is formed over the posterior superior iliac spine since the medial fibers of the gluteus maximus originate from, but do not cover, the spine. A triangle is formed between the two depressions or dimples on either side of the midline and the gluteal cleft. Thorough lipoplasty in this sacral triangle helps define the superior borders of the buttocks. A gluteal fat pad covers the inferior medial border of the gluteus maximus and forms the medial part of the infragluteal fold. Laterally, the gluteus maximus tapers between the long head of the biceps femoris and vastus lateralis. The inferiorly pointing form of the muscle here may be visible in male patients, but in female patients the overlying gluteal fat usually obscures the form of the muscle. Additionally, a band of fascia across the inferior part of the gluteus maximus creates a deep infragluteal crease when the hip is extended. This crease extends from the gluteal cleft in the midline for a variable distance laterally depending on the volume of the buttock and tone of the skin. Gluteal augmentation using autolo-

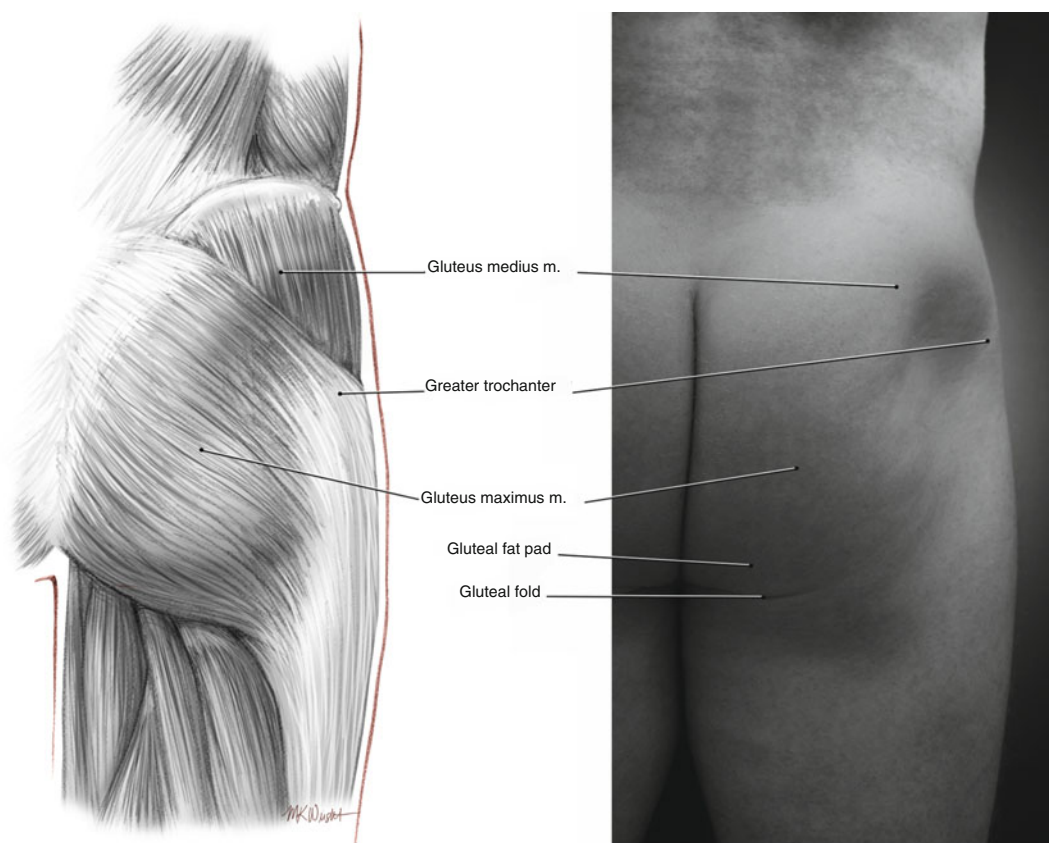


Fig. 2.13 Gluteus maximus. This muscle provides mass, shape, and projection to the buttocks

gous fat can be performed from an access site in the infragluteal crease with the patient in the prone position. On profile view, a concavity occurs between the greater trochanter and muscle fibers of the gluteus maximus where the muscle inserts into the iliotibial tract. The iliotibial tract covers the vastus lateralis and passes inferiorly to insert into the lateral condyle of the tibia. The muscle bulk of the gluteus maximus posteriorly and the gluteus medius superiorly creates a “C”-shaped form with the greater trochanter lying centrally (Fig. 2.14).

Gluteus Medius

Anterior to the gluteus maximus lies the gluteus medius, a strong fan-shaped muscle that runs from the anterior part of the lateral aspect of the

ilium to the lateral surface of the greater trochanter (Fig. 2.14). The posterior part of the gluteus medius is hidden deep into the anterior fibers of the gluteus maximus. Anteriorly, the gluteus medius is bounded by the thin teardrop-shaped tensor fascia lata that passes from the iliac crest just posterior to the anterior superior iliac spine and inserts on the iliotibial tract just above the level of the infragluteal fold.

Iliopsoas

Although the form of the iliopsoas cannot usually be appreciated on the surface, it forms the floor of a triangular space bounded superiorly by the inguinal ligament and laterally by the sartorius. The iliopsoas comprises two muscles: iliacus and psoas major. The iliacus originates from the iliac

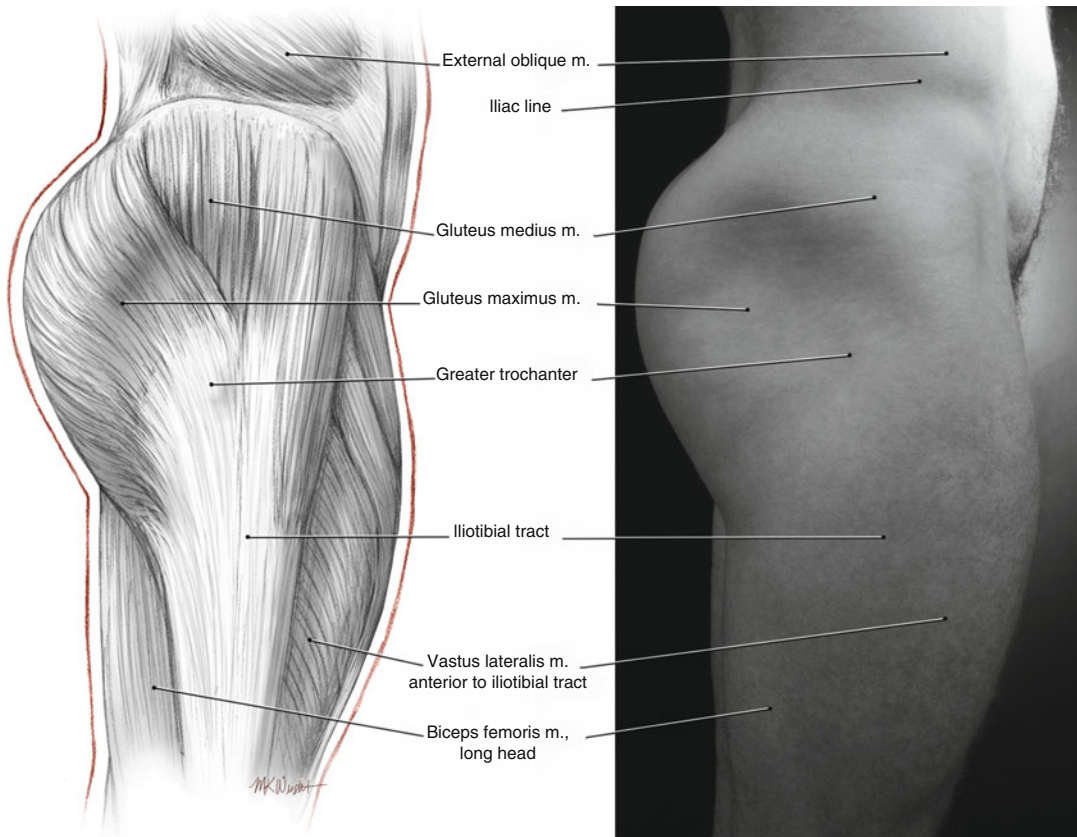


Fig. 2.14 Lateral aspect of the thigh and hip. The gluteus maximus projects posteriorly and continues anteriorly with the gluteus medius. Note the shadow between the biceps femoris and the iliotibial tract of the lateral thigh

fossa and sacrum and inserts into the shaft of the femur just below the lesser trochanter. The psoas major originates from the transverse processes and bodies of the lumbar vertebrae and inserts into the lesser trochanter of the femur. Lipoplasty over the iliopsoas just inferior to the inguinal ligament makes the ligament appear more prominent and defines the inferior extent of the abdomen.

Quadriceps

This large muscle group forms a large bulky mass over the anterior thigh. The quadriceps femoris consists of four muscles: vastus lateralis, vastus intermedius, vastus medialis, and rectus femoris. The form of the muscles, except the vastus intermedius, can be appreciated on the surface,

particularly when the knee is forcefully extended (Fig. 2.15). The muscle bellies taper inferiorly toward their strong quadriceps tendon. The vastus lateralis originates from the anterior surface of the greater trochanter and along the linea aspera on the posterior surface of the shaft of the femur. The muscle sweeps over the anterolateral aspect of the thigh creating a convex form. The more bulky inferior portion ends abruptly at the quadriceps tendon below the insertion of the adjacent rectus femoris into the tendon. Laterally, the iliotibial tract passes from the greater trochanter, along the lateral thigh over the vastus lateralis, and inserts into the lateral condyle of the tibia. A concave space is formed above the knee laterally that is bordered by the iliotibial tract posteriorly, the distal limit of the vastus lateralis belly superiorly, and the patella

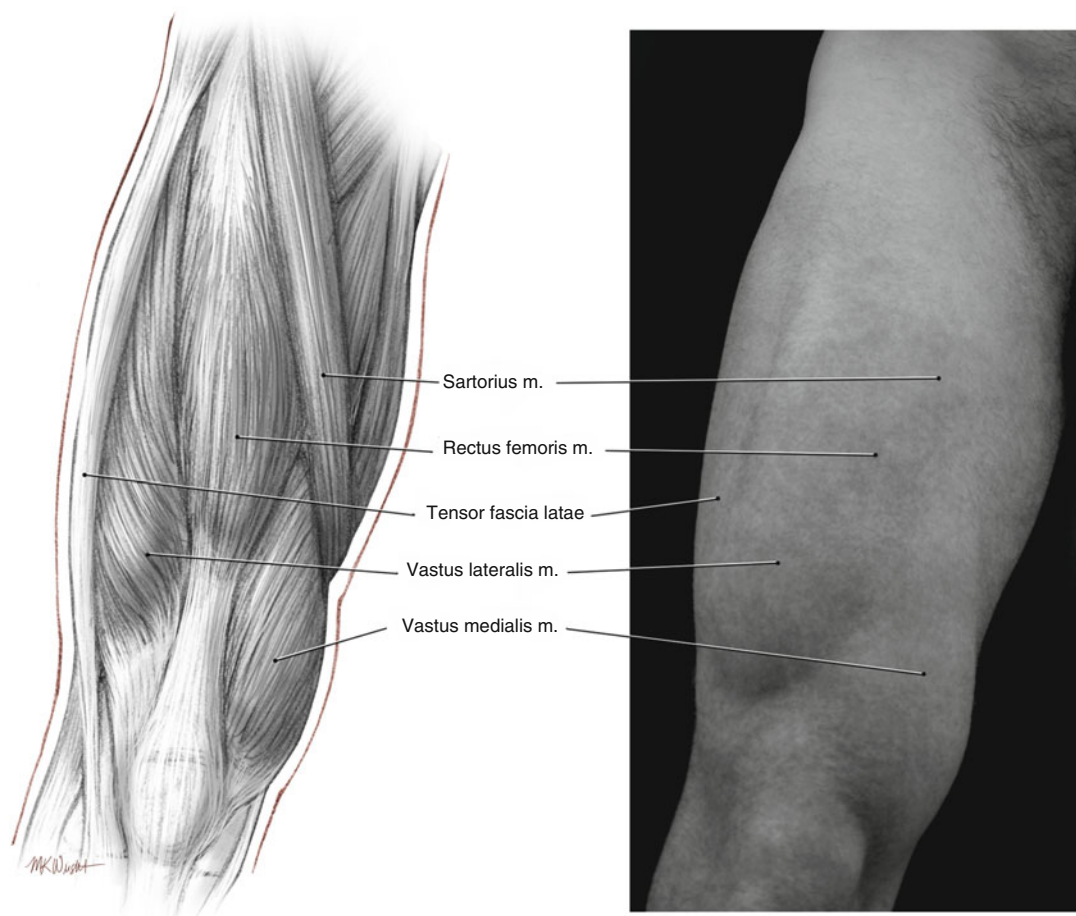


Fig. 2.15 Muscles of the anterior thigh. Except for the vastus medialis, there is little muscle mass immediately adjacent to the patella. The fat pads around the knee are contoured to define the knee and taper the thigh

anteriorly. An obvious groove is usually present along the lateral thigh that separates the quadriceps anteriorly from the hamstrings posteriorly (Fig. 2.16). This extends from the gluteus maximus to the posterior aspect of the iliotibial tract before the latter inserts into the tibia and represents an area of focused sculpting to enhance the definition of the thigh muscles.

Unlike the vastus, the rectus femoris crosses both the hip joint and the knee joint. It acts to flex the hip and extend the knee. Rectus femoris arises from the anterior inferior iliac spine and inserts into the patella first and then the tibial tuberosity via the patellar tendon. Near its origin superiorly, the form of the muscle belly is not easily appreciated as it is hidden between the tensor fascia lata

laterally and the sartorius medially. The fusiform muscle belly occupies the upper two-thirds of the anterior thigh and tapers inferiorly before joining its tendon between the muscle bellies of the vastus lateralis and vastus medialis. The vastus medialis gives rise to the medial teardrop-shaped form on the lower medial thigh. It originates from the linea aspera and medial supracondylar line of the femur and inserts into the quadriceps tendon and upper outer part of the patella. The form of the vastus medialis is lower than the convexities of the rectus femoris and vastus lateralis, extending down medially to the level of the patella or below this level. The fat below the inferior margin of the vastus medialis can be removed to define the knee and improve the tapered appearance of the thigh.

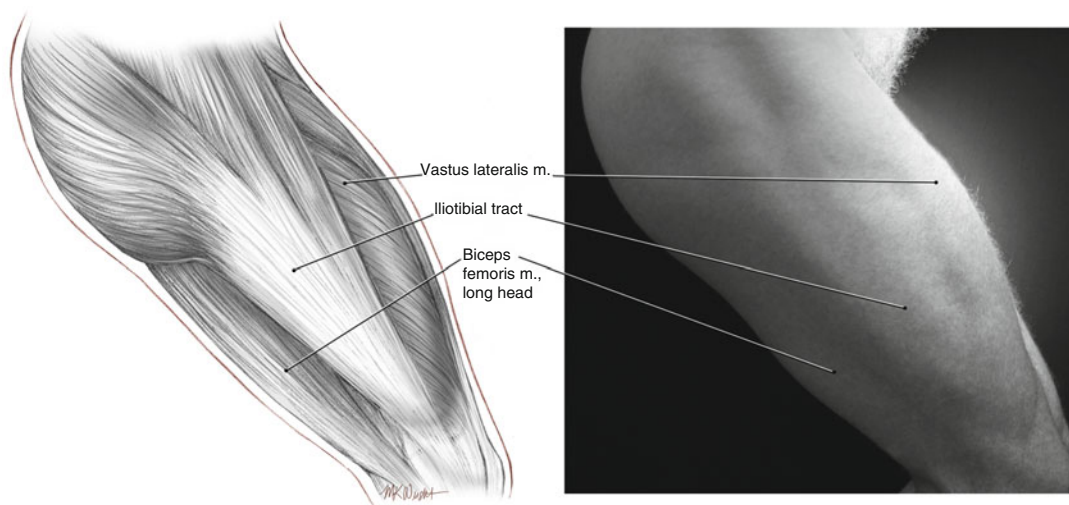


Fig. 2.16 The lateral thigh. The groove between the flexors and extensors becomes more visible upon hip and knee flexion, as in squatting

Hamstrings

This muscle group forms the posterior thigh compartment and consists of the long and short heads of the biceps femoris laterally and the semimembranosus and semitendinosus medially. The individual muscle forms are not very pronounced on the surface, except for the tendons that border the popliteal fossa when the leg is flexed. Hip and knee flexion usually produces a groove or ridge between the long and short heads of the biceps femoris and vastus lateralis.

The short head of the biceps femoris originates from the linea aspera of the femur. The long head, semimembranosus, and semitendinosus originate from the ischial tuberosity of the pelvis. Both heads of the biceps femoris insert into the head of the fibula. The semimembranosus inserts into the posterior part of the medial condyle of the tibia, whereas the semitendinosus inserts lower down on the medial aspect of the proximal shaft of the tibia. It is difficult to distinguish the long head from the short head of the biceps femoris when the knee is extended. However, with

knee flexion, the two forms separate. The short head joins the common biceps tendon from posteriorly, forming a tough flat sheetlike structure that becomes very prominent with knee flexion. This thin ridge forms the lateral margin of the popliteal fossa. When the knee is flexed, a triangular fossa forms between the biceps tendon and vastus lateralis.

Sartorius

The sartorius is a long thick ropelike muscle that creates a cylindrical form on the anterior and inner thigh between the forms of rectus femoris and the adductor muscles (Fig. 2.17). It originates from a point just below the tip of the anterior superior iliac spine and spirals down the inner thigh and around the vastus medialis, to cross the knee joint and insert into the upper medial shaft of tibia below the medial condyle. Removing fat over the adductor compartment in the medial thigh can improve definition of the medial border of the sartorius. Medial to the

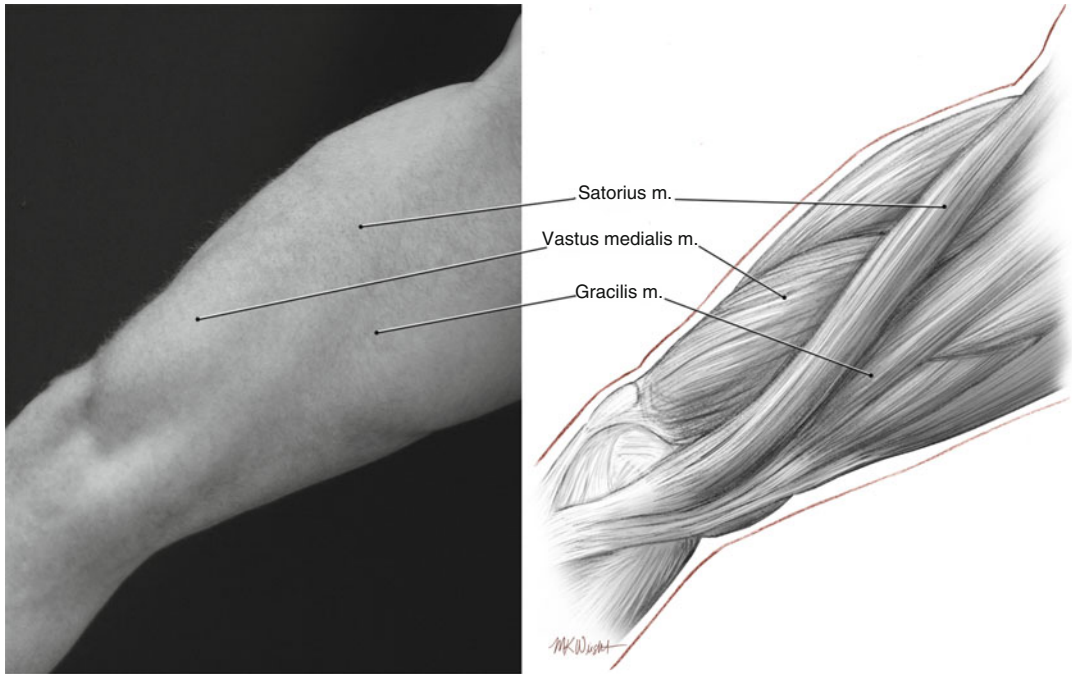


Fig. 2.17 The medial thigh muscles. The sartorius is a landmark between the quadriceps and adductors. Fat is

removed medial to the sartorius along its length and over the adductors to improve the contours of the inner thigh

knee, the sartorius forms a thick band that is sometimes obscured by overlying medial knee fat pads.

Adductor Group

The adductor longus, adductor magnus, and gracilis lie in the upper inner thigh and contribute to the mass in this part of the upper leg. The adductor magnus is the largest of the three muscles and forms the mass of the medial part of the posterior thigh, blending with the semimembranosus and semitendinosus that lie laterally. The adductor longus arises just below the pubic tubercle and expands into a flat belly toward the femur. It inserts into the middle third of the posterior surface of the femur. It lies in front of the other

adductors, but its form is hardly visible on the surface. The gracilis arises from the pubic arch, passes down along the inner thigh, and inserts into the superior medial aspect of the tibial shaft below the medial condyle. The tendon of origin of the gracilis may be visible when the legs are abducted; both the muscle bellies themselves are rarely seen as a distinct entity. During high-definition sculpting, thorough fat removal over the adductor compartment medial to the sartorius defines this area, but the forms of the individual muscles are not usually separated.

Increased muscular definition of the thigh is achieved by accentuating the groove between the vastus lateralis and biceps femoris. A shadow is created by thorough superficial fat removal along the vertical ridge between the extensor and flexor compartments. The muscle masses around the

knee are defined by removing the knee fat pads superiorly and medially to define the vastus medialis and vastus lateralis above and the sartorius medially.

Lower Leg

The attractive curves of the lower leg are attributable to the main muscles in the posterior compartment of the leg: the lateral and medial heads of the gastrocnemius and soleus [1, 2]. These provide smooth convex prominences in the superior part of the lower leg that taper and narrow inferiorly toward the ankle. They insert through the tough Achilles tendon into the calcaneus. The delicacy of the ankle relies on a prominent Achilles tendon with very little fat medial and lateral to it. Sculpting the lower leg is performed with fine instruments to remove superficial subcutaneous fat around the forms of the gastrocnemius and soleus and on either side of the Achilles tendon.

Gastrocnemius

The medial and lateral heads of the gastrocnemius form the main muscle bulk of the calf. The medial head arises from the medial condyle of the femur and the lateral head from the lateral condyle. The medial head is larger than the lateral head and forms a convex bulge that is slightly lower than the lateral head (Fig. 2.18). The medial head occupies the superior medial quadrant of the posterior aspect of the lower leg and wraps around to cover part of the medial aspect of the leg. The lateral head wraps around to the lateral aspect of the leg to a lesser degree. Both heads are teardrop-shaped forms that end inferiorly where the muscle inserts into the broad flat gastrocnemius tendon. This tendon covers the posterior lower aspect of the leg and fuses with the tendon of the soleus beneath it to form the Achilles tendon. The key to successful contouring of the leg is to reveal the convex forms of the

gastrocnemius and taper the leg inferiorly toward the sharply defined Achilles tendon.

Soleus

The soleus originates from the posterior surface of the head and superior shaft of the fibula and the soleus line on the posterior surface of the tibia. The belly of the soleus lies deep to the heads of the gastrocnemius and gives the calf thickness. Its lateral and medial edges may be seen to bulge from beneath the gastrocnemius tendon when the foot is plantar flexed. The soleus inserts into the posterior surface of the calcaneus via the Achilles tendon.

Fat Distribution

Subcutaneous fat is present in nearly every region of the body in varying quantities. The fat lies predominantly in the superficial fascia between the skin and muscles and is more plentiful on the trunk compared to the limbs. In general, females have a greater percentage of body fat compared to males, particularly over the pelvic region: hips (iliac crest), gluteal muscles, and upper thigh [7]. Regional fat anatomy and volume play an important part in the aesthetics of human form, particularly in females where breast fat and hip fat improve curvaceousness. Although fat is present throughout the body, certain areas have a propensity to accumulate relatively more fat in men and women. In females, fat tends to accumulate around the hips and buttocks (Fig. 2.19). In men, the most prominent fat pads are usually in the chest, abdomen, and flanks (Fig. 2.20). Lipoplasty performed to improve muscular definition typically involves removing the majority of the subcutaneous fat that obscures the appearance of the muscular form beneath, leaving only a thin subdermal layer. Augmentation of muscles is achieved by autologous fat transfer intramuscularly, for example, in the pectoralis major or gluteus maximus.

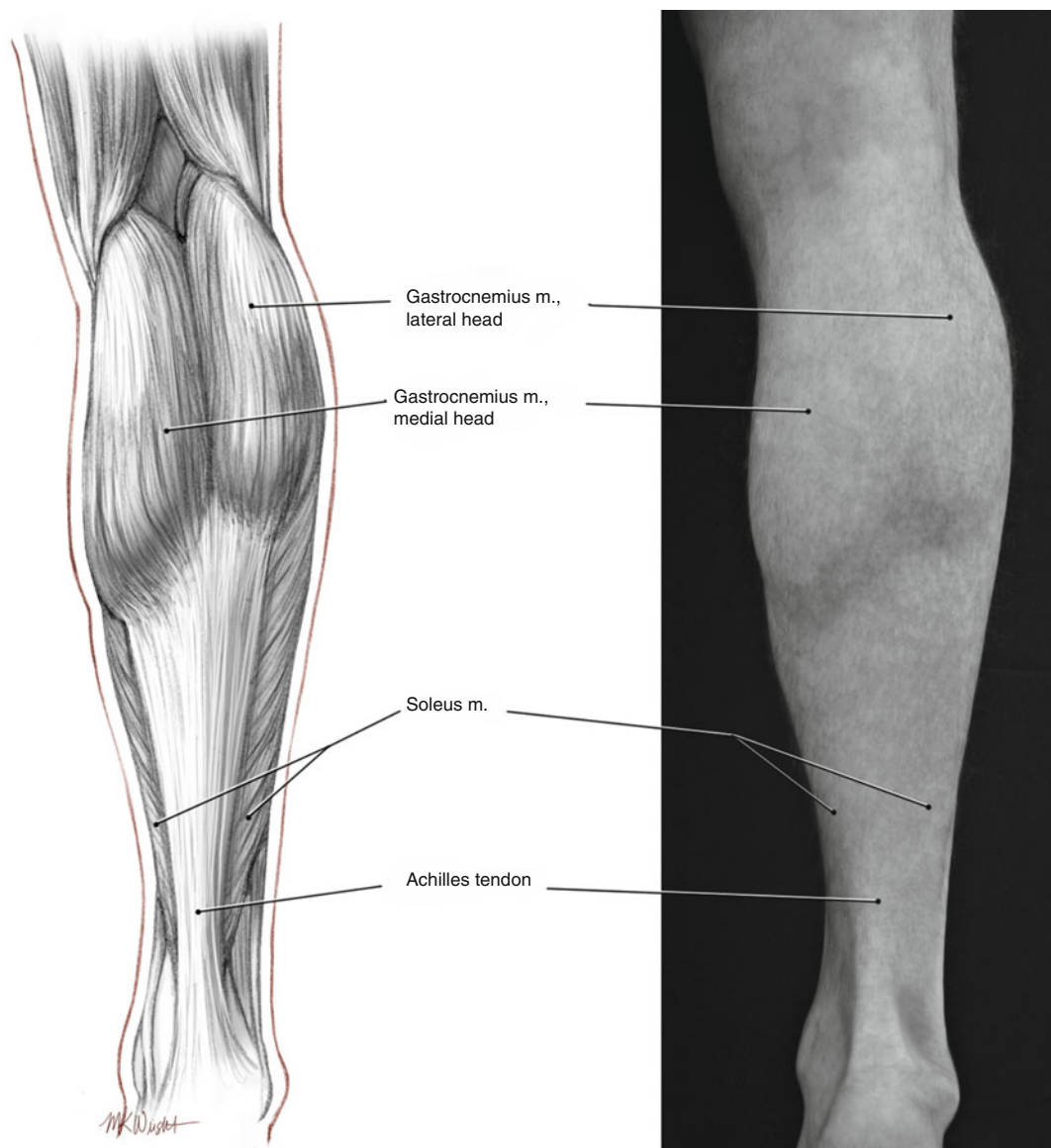


Fig. 2.18 Muscles of the leg. The medial and lateral heads of the gastrocnemius form convex masses that give the leg its contours

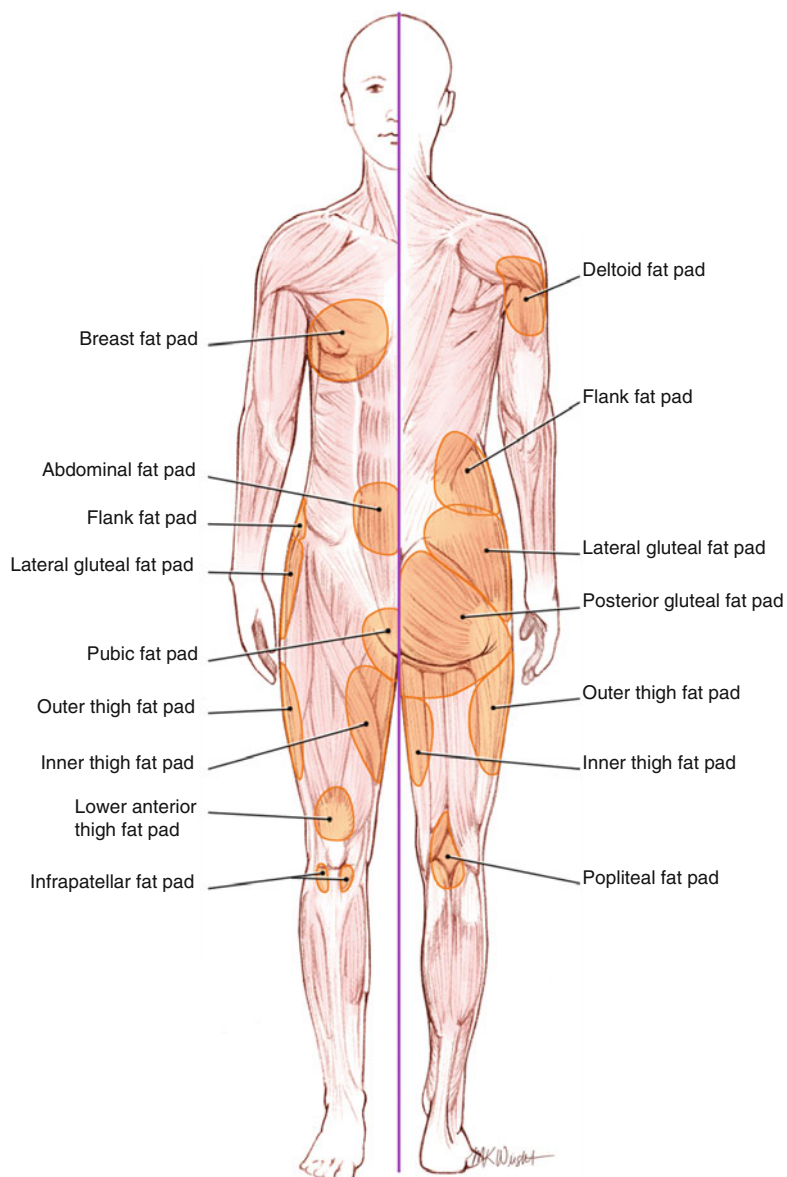


Fig. 2.19 Fat pads in the female

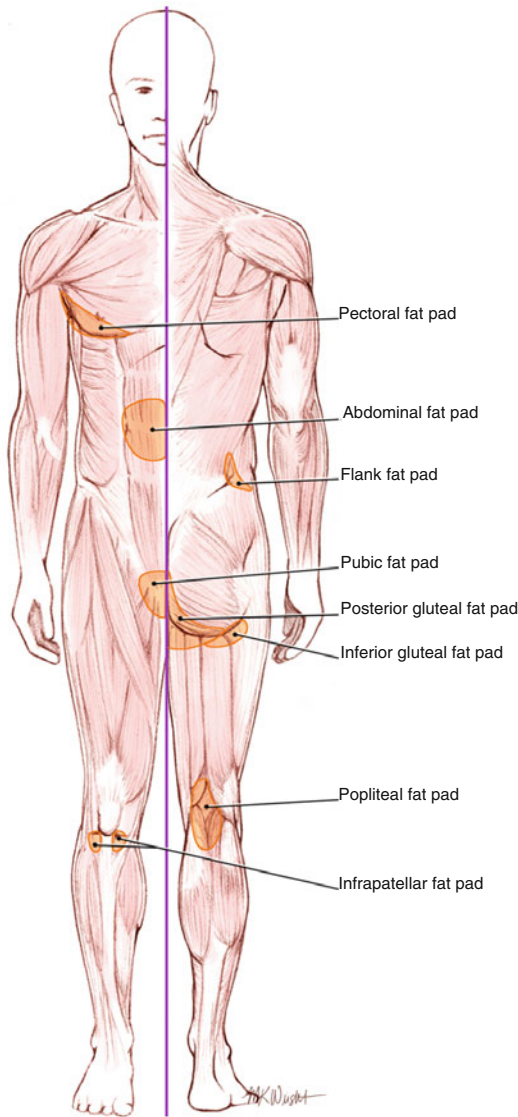


Fig. 2.20 Fat pads in the male

References

1. Rubins DK (1976) *The human figure: an anatomy for artists*. Penguin Books, New York
2. Simblet S, Davis J (2001) *Anatomy for the artist*. DK Publishing, New York
3. Nahas FX (2001) An aesthetic classification of the abdomen based on the myoaponeurotic layer. *Plast Reconstr Surg* 108(6):1787–1795
4. Florer RE, Kiriluk L (1971) Petit's triangle hernia: incarcerated: two case reports. *Am Surg* 37(8): 527–530
5. Hale RB, Coyle T (1977) The rib cage. In: *Anatomy lessons from the great masters*. Watson-Guptill, New York, p 24
6. Williams PL (1995) *Gray's anatomy: the anatomical basis of medicine and surgery*, 38th edn. Churchill Livingstone, Edinburgh, p 811
7. Goldfinger E (1991) *Human anatomy for artists. The elements of form*. Oxford University Press, Oxford, p 289

High Definition Body Sculpting

Art and Advanced Lipoplasty Techniques

Hoyos, A.; Prendergast, P.M.

2014, XVIII, 244 p. 255 illus., 248 illus. in color.,

Hardcover

ISBN: 978-3-642-54890-1