

Giada Anna Beltramini, Francesco Laganà, Alessandro Baj,  
Michele Romano, Antonio Russillo, and Aldo Bruno Gianni

## 2.1 Facial Analysis

Facial analysis involves evaluation of functional and aesthetic disharmonies. It is important to appreciate what constitutes one's own perceptions of beauty and how the clinician can translate this into successful clinical results [1–4]. Facial analysis together with clinical bite examination should provide good diagnosis and treatment plan. Facial analysis identifies positive and negative facial traits and dictates how the bite will be corrected to optimize aesthetic facial goals. ‘The bite indicates a problem; the face indicates how to treat the bite’ Arnett affirms [5]. Ideal occlusal harmony is achieved with the desired cosmetic facial changes. These facial changes dictate what orthodontic or surgical procedures or medical aesthetic treatment should be chosen [6]. Natural head position, centric relation, first tooth contact and relaxed lip position are necessary to accurately assess the face. The patient should be in relaxed lip position to demonstrate the relationship of soft tissues relative to hard tissues without muscular compensation for dentoskeletal abnormalities. The clinical examination starts from the oral cavity: the occlusal classification is determined, and the degrees of incisor overlap and overjet are quantified (Table 2.1), (Figs. 2.1, 2.2, 2.3).

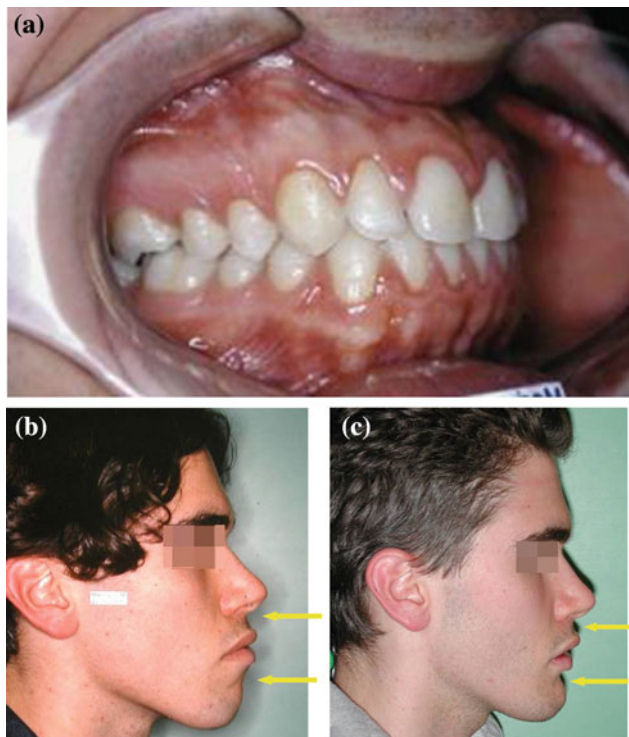
The maxillary and mandibular dental midlines are assessed to determine whether they are congruent with each other and with the facial midline. Deviations are noted and quantified. The presence and degree of dental compensation is also recorded. Dental compensation is the tendency of teeth to tilt in a direction that minimizes the dental mal-

**Table 2.1** Occlusal classifications and orthodontic terminology

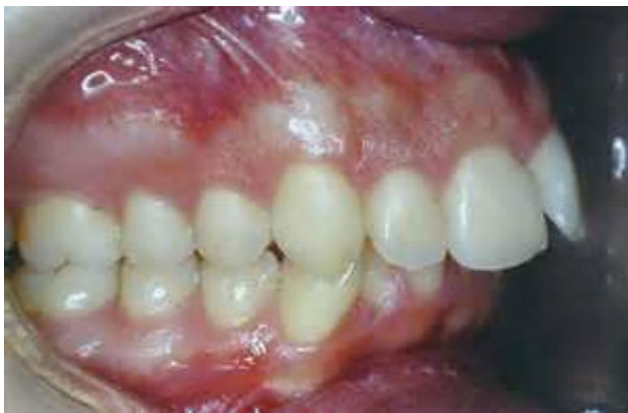Class I occlusion	The mesiobuccal cusp of the first permanent maxillary molar occludes in the buccal groove of the permanent mandibular first molar See Fig. 2.1
Class II malocclusion	The mesiobuccal cusp of the first permanent maxillary molar occludes mesial to the buccal groove of the permanent mandibular first molar See Fig. 2.2
Class III malocclusion	The mesiobuccal cusp of the first permanent maxillary molar occludes distal to the buccal groove of the permanent mandibular first molar See Fig. 2.3
Overjet	Overjet is a horizontal (anterior-posterior) distance, of the upper incisors ahead of the lower incisors. Normal overjet is between 1 and 3 mm
Negative overjet	Negative overjet or reverse overjet is where the upper incisors are behind the lower incisors See Fig. 2.3
Overbite	Overbite is a vertical distance, the maxillary incisors overlap the mandibular incisors. Normal overbite is between 3 and 5 mm
Open bite or apertognathia	Overbite $\leq 0$ mm. Is a type of malocclusion characterized by the occlusion of posterior teeth without anterior occlusion See Fig. 2.5
Deep bite	Deep bite is an increase of the overbite ( $>5$ mm) See Fig. 2.7
Crossbite	Crossbite is an occlusal irregularity where a tooth (or teeth) has a more vestibular or lingual position than its corresponding antagonist tooth in the upper or lower arcade See Fig. 2.5

G. A. Beltramini · F. Laganà · A. Baj · M. Romano · A. Russillo · A. B. Gianni (✉)  
Maxillofacial Surgery, Ospedale Maggiore Policlinico,  
via Sforza 35, 20123 Milan, Italy  
e-mail: aldo.gianni@unimi.it

occlusion. Compensation will camouflage the deformity and restore proper overjet and overlap. If orthodontic tooth movement cannot produce the necessary facial changes, then surgery should be indicated.



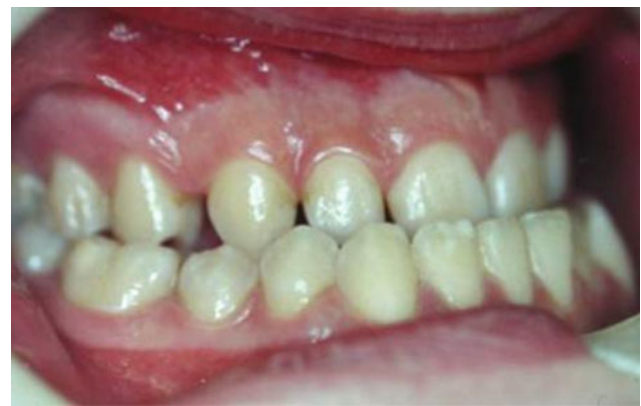**Fig. 2.1** Intraoral photograph of Class I occlusion (a). Despite normal interidental relationships, the aesthetical examination of the same patient (b) documents a jaws biprotrusion. The surgical correction consisted of superior and inferior dentoalveolar osteotomies. (c) Post-operative lateral view



**Fig. 2.2** Class II malocclusion

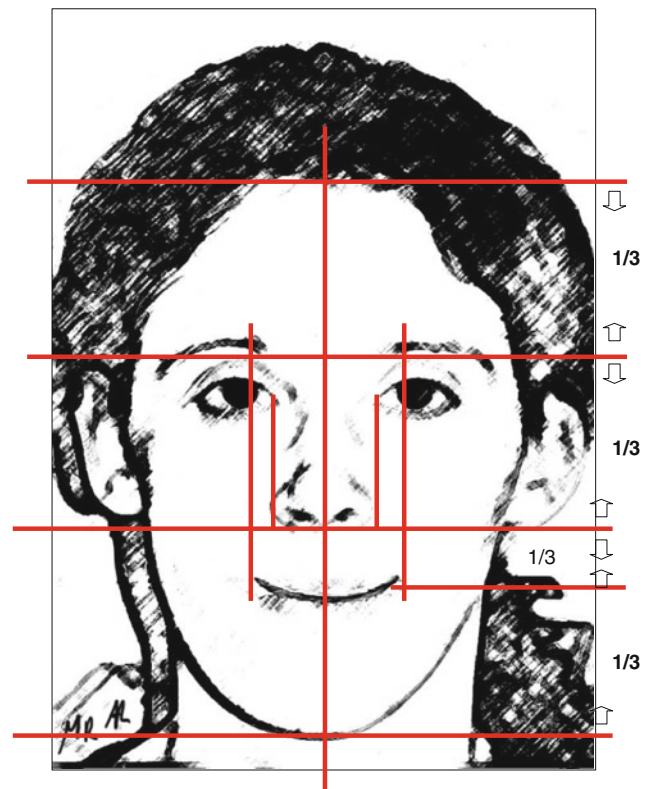
## 2.2 What's Beauty?

Clinical facial analysis [7] defines appearance, proportions, volumes, symmetry and visible deformities; it is a crucial phase of surgical planning that can visualize, evaluate and prioritize existing problems. But what determines beauty? The canons of beauty have changed over time. The harmony of shapes related to 'gold number' or 'divine proportion' to

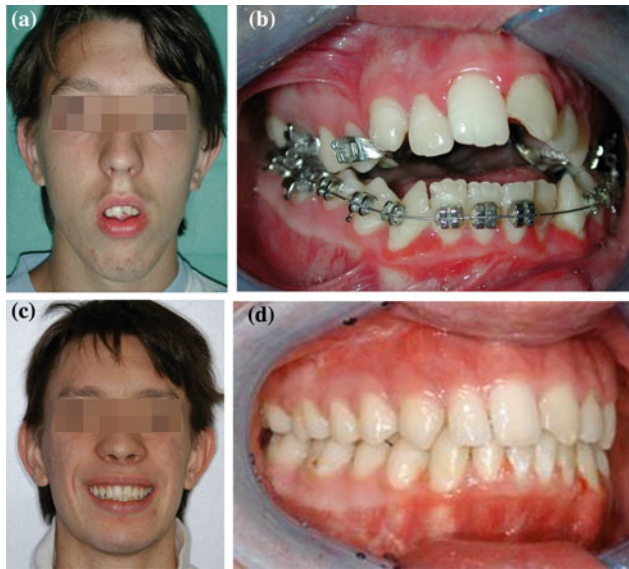

**Fig. 2.3** Class III malocclusion

which artist were inspired in every period of history for their representations (Da Vinci, Vitruvio, Botticelli). Some features symbolize an idea or feeling and inspire emotions absolutely unique in the observer. 'Regions of Interest', or 'facial points of interest', theorized from Yarus, are angles, maximal curvature points and unpredictable curve of the outline (curve that change in the different positions of vision): the lip commissure and the lateral and medial

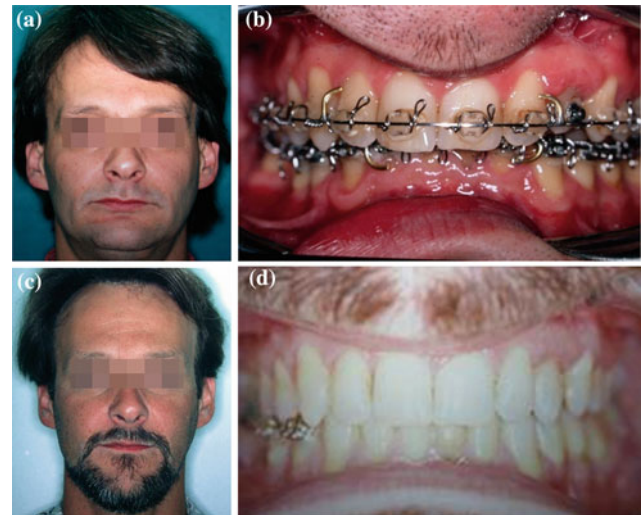


**Fig. 2.4** Frontal facial analysis. The ideal face is vertically divided into equal thirds by horizontal lines adjacent to trichion, glabella, nasal base, and menton. The lower third is divided into two parts: the upper lip makes up the upper third, and the lower lip and chin compose the lower two-thirds



**Fig. 2.5** Long face syndrome. A 'long face' is a long, narrow face, with anterior and posterior maxillary overgrowth, a narrow alar base and lip incompetence. Cephalometric analysis demonstrates steep mandibular and occlusal planes in relationship to the cranial base, and increase in facial height and repositioning of the mandible. Evaluation of study models exhibits increased alveolar bone height, a high palatal vault, and a narrow maxillary arch. The dental relationship may be Class I, II or III (with Class II being the most common), with or without open bite. Clinical (a) and intraoral (b) views of long face, II class, transversalmaxillaryhypoplasia. The treatment plan is divided in two steps: first an orthosurgical expansion, second a Le Fort I maxillary osteotomy for superior repositioning of the maxilla, BSSO and mentoplasty. c and d pictures show the aesthetic and occlusal improvements after surgery

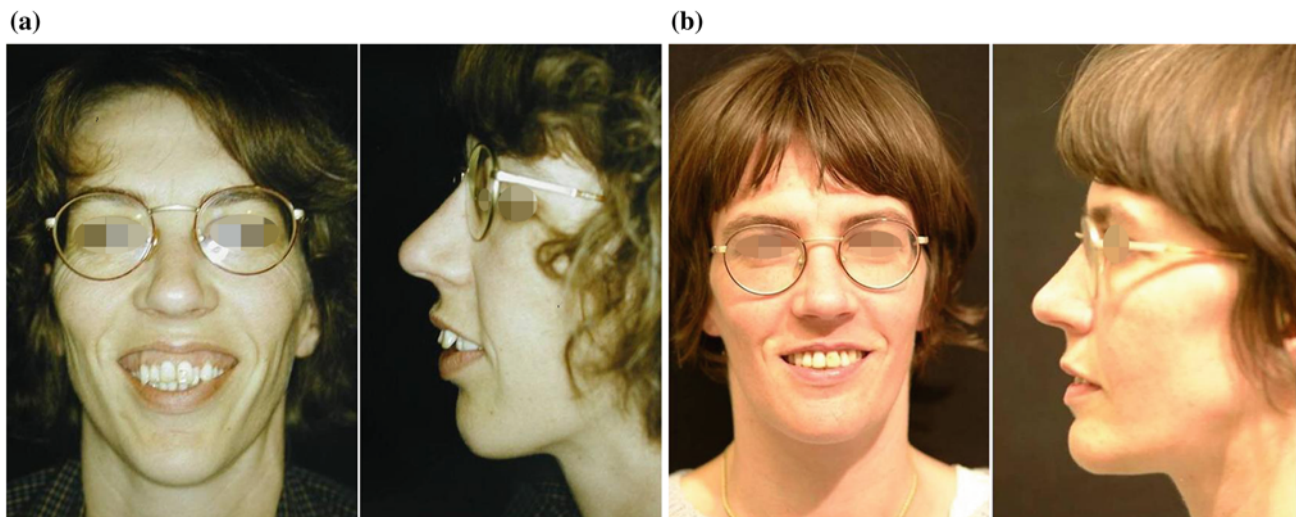
canthus are angular points of interest; the root of the nose and the labial-mental furrow are concavities and the tip of the nose, superior and inferior lip and chin are convexities. In the past, notions of beauty were envisaged as arbitrary cultural conventions with no uniformly accepted standard of what constitutes an attractive face. However, during the last decade, a greater understanding of the shared preferences for attractive faces has led researchers to regard certain aspects of facial attraction as inherent and definable, transcending social and cultural fashions. Some studies suggested that female face attractiveness is greater when the face is symmetrical, is close to the average, and has certain features (e.g. large eyes, prominent cheekbones, thick lips, thin eyebrows and small nose and chin) [8, 9]. Symmetry is a characteristic of attractive faces, but there are some exceptions to the rule. Under certain conditions, symmetry can be completely unattractive; the visual impact of symmetry on the perception of beauty increases significantly when approaching the midline [10]. The frontal facial view (Fig. 2.4) [11] provides information on the midlines, levels, outline and heights of the face. In particular, orbital rim, subpupil and alar base contours are noted. Vertical facial planning of facial or occlusal cants, midline deviations and



**Fig. 2.6** Short face syndrome. A 'short face' is marked by Class II malocclusions with skeletal deep bite and reduced facial height. Treatment is aimed at establishing a proper lip-incisor relationship. The facial skeleton should be expanded to the degree that provides optimal soft-tissue aesthetics. Inferior repositioning of the maxilla and clockwise mandibular rotation is indicated to improve facial aesthetics and function. Clockwise mandibular rotation leads to posterior positioning of the chin; the surgeon needs to assess the new chin position on the cephalometric tracing to determine whether an advancement genioplasty is necessary. Pre-operative facial (a) and occlusal (b) analysis of a short face syndrome. Frontal (c) and intraoral (d) appearance after a two-jaw surgery

general facial outline is determined by information gained from the clinical facial examination. The facial evaluation begins with assessment of these vertical facial thirds: trichion to glabella, glabella to subnasale, and subnasale to menton; each of these facial thirds should be about equal (Figs. 2.5, 2.6). The most important factor in assessing the vertical height of the maxilla is the degree of incisor showing while the patient's lips are in repose. A man should show at least 2–3 mm, whereas as much as 4–5 mm is considered attractive in a woman. If the patient shows the correct degree of incisor in repose, but shows excessive gingival in full smile, the maxilla should not be impacted (Fig. 2.7). The intercanthal distance should be the same as the distance between the medial and lateral canthus of each eye. The inferior orbital rims, malar eminence, and piriform areas are evaluated for the degree of projection. If these regions appear deficient, maxillary advancement is indicated. The alar base width should also be assessed prior to surgery since Le Fort I osteotomy may alter the width. Asymmetries of the maxilla and mandible are documented on physical examination, and the degree of deviation from the facial midline is noted. The soft-tissue envelope of the upper face is evaluated for descent of the malar fat pads, the severity of the nasolabial creases and folds. These changes are associated with aging; however, skeletal movements of the maxilla will affect these areas. It is important for the





**Fig. 2.7** Gummy smile. Clinical views of a patient who presents a severe lip incompetence and accentuation of perialar areas. She sustained superior repositioning of the maxilla, counter clockwise mandibular rotation and chin advancement. The treatment approach is

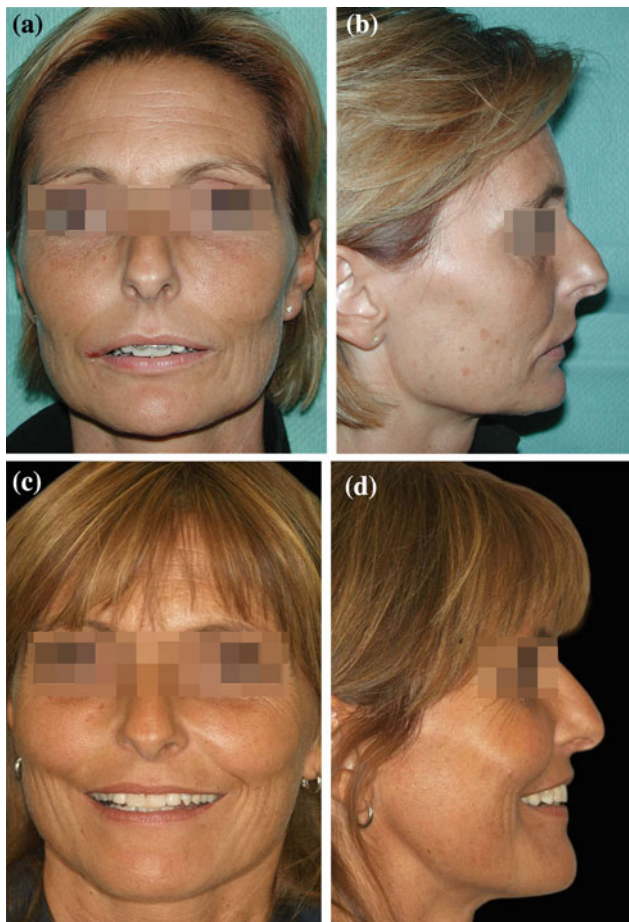
to impact the maxilla to achieve the proper incisor show with the lips in repose. **a** Pre-operative facial appearance. **b** One-year post-operative facial views

surgeon to realize that skeletal expansion (anterior or inferior repositioning of the jaws) will improve the creases and folds, whereas skeletal contraction (posterior or superior movements of the jaws) will accentuate these aspects and appearance of premature aging. The surgeon can frequently take advantage of skeletal expansion to reduce some of these soft-tissue creases, giving the patient a youthful appearance and reducing the signs of aging (Fig. 2.8). In evaluating the chin, the clinician assesses the labiomental angle. An acute angle may indicate a short or prominent chin, and effacement of the crease typically excessive vertical length or insufficient anterior projection. The profile view is used to assess the projections of the face (Figs. 2.9, 2.10). Projections analysis is divided into high midface, maxillary and mandibular areas. An experienced clinician can usually determine whether the deformity is caused by the maxilla, the mandible, or both just by looking at the patient. This assessment is made clinically and verified radiographically with cephalometry. Holdaway describes a ‘harmony line’ or H line that extend from pogonion to the most prominent part of the upper lip. The line that runs from the soft-tissue nasion to the pogonion meets the H line to create the H angle. An average H angle is 10 degrees; a larger angle relates to increasing soft-tissue profile convexity. The proper position of the nose relates to the upper lip, which is supported by the maxillary incisors, and the chin. Because both of these structures may be altered by orthognathic surgery, it is important to predict how the dimensions of the nose will fit into the new facial proportions. The soft tissues of the neck are also assessed. The patient with submental laxity will not benefit aesthetically

from posterior positioning of the mandible. Mandibular advancement, however, will improve the laxity and the cervicomenal angle.

### 2.2.1 Surgical Options: The Orthognathic Surgery

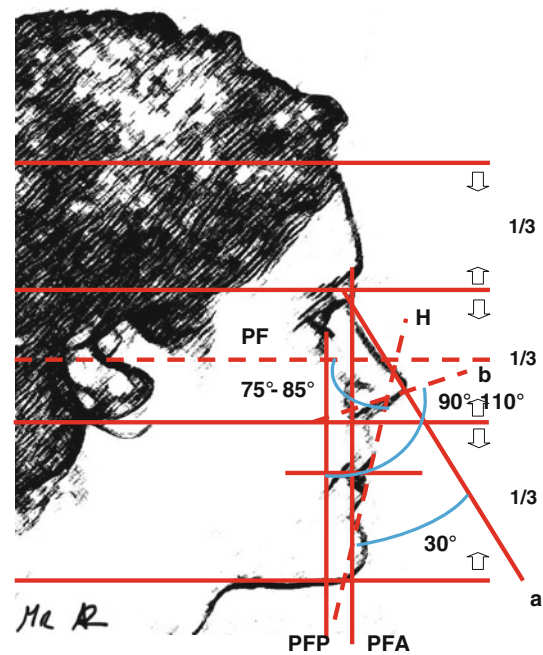
In orthognathic surgery one or more segments of the jaws can be simultaneously repositioned to treat various types of malocclusion and craniofacial deformities [1]. All clinical and radiographic findings are analyzed and pre-surgical model surgery performed. Maxillary advancement improves the facial contour and normalizes dental occlusion when there is a relative deficiency of the midface region. Maxilla movements require Le Fort I osteotomy (Fig. 2.11). The vertical position of the maxilla is recorded by measuring the distance between the medial canthus and the orthodontic arch wire. An incision is made 5 mm above the mucogingival junction from first molar to first molar. A periosteal elevator is used to expose the maxilla around the piriform rim and infraorbital nerve and complete the dissection of the nasal floor and lateral nasal wall. A reciprocating saw or a fissure burr is used to make a transverse osteotomy from the piriform aperture laterally until the maxillary tuberosity; the cut should be made at least 5 mm above the apices of the teeth. A double-balled osteotome is used to release the septum from the maxilla. The Kawamoto-Tessier osteotome is used between the tuberosity of the maxilla and the pterygoid plate of the sphenoid bone to pterygomaxillary disjunction. The maxilla is down fractured with manual pressure or with disimpaction forceps. A splint, obtained



**Fig. 2.8** Pre-operative and post-operative frontal (a) and lateral (b) views in a case of skeletal expansion with facial rejuvenation after orthognathic surgery (Le Fort I osteotomy, Bilateral Sagittal Split Osteotomy, mentoplasty and mandibular angles remodeling—see ‘Surgical Options’)

during the pre-surgical planning on dental models, is used to place the maxilla in its proper position. Intermaxillary fixation is then applied with 26-gauge wires around the surgical lugs. The amount the maxilla will be impacted or elongated and/or advanced was determined in the treatment plan. Two plates on each side, usually L-shaped, can be used to secure the maxilla. The mandibulomaxillary fixation is released and occlusion verified prior to closure. If the alar base is wide, an alar cinch can be performed to normalize the width. Lip shortening may also result from closure; A V-Y closure at the central incisor can help alleviate this effect. Finally, if simultaneous expansion of the maxilla is necessary, the maxilla can be split into two or more pieces to allow simultaneous expansion.

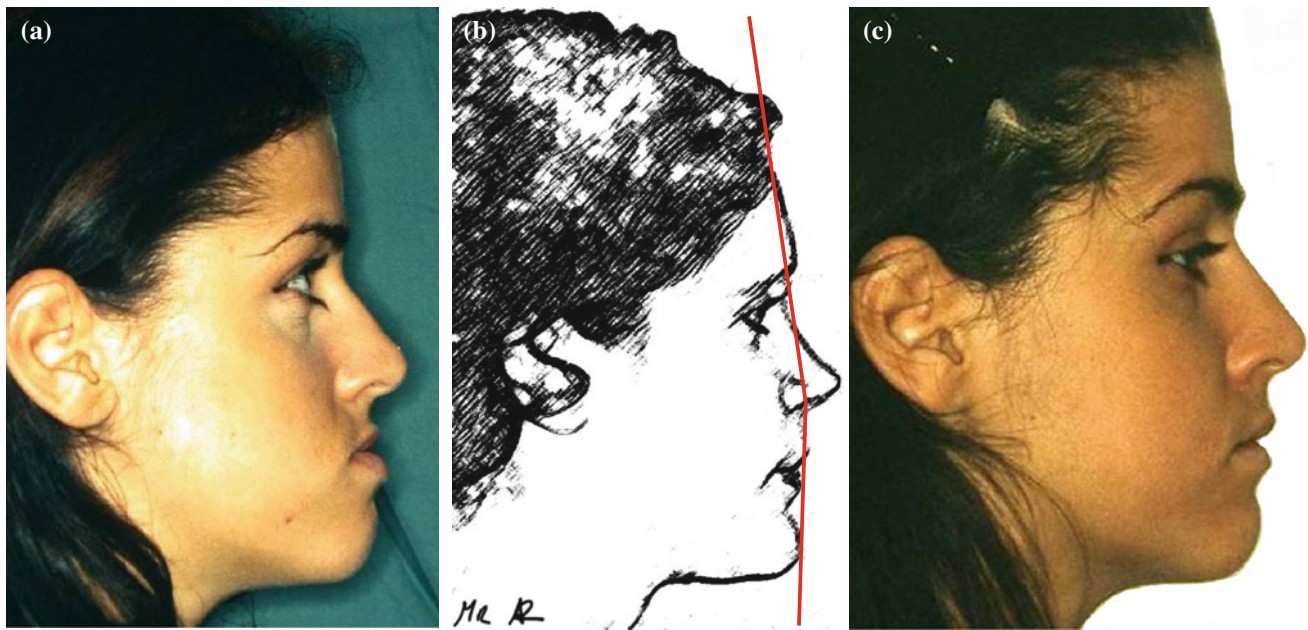
Depending on severity of the occlusal discrepancy and soft tissues profile, problems in the lower face may require surgery on mandible. This can be done in conjunction with or separate to maxillary surgery. The mandible can be advanced, set back and tilted. A combination of these



**Fig. 2.9** Analysis of the facial profile. Four horizontal lines divide the face into three-thirds. These lines are also used for the Frankfurt plane (PF), the front frontal plane (PFA), the rear frontal plane (PFP), the H line (H): this line with the PF form an angle of between 75° and 85°, while a plane passing through the nasion (a) with the PFA form an angle of approximately 30°. Finally, a plane passing through the major axis of the nostril (b) with PFP form an angle of approximately 90° and 110°, respectively in males and females

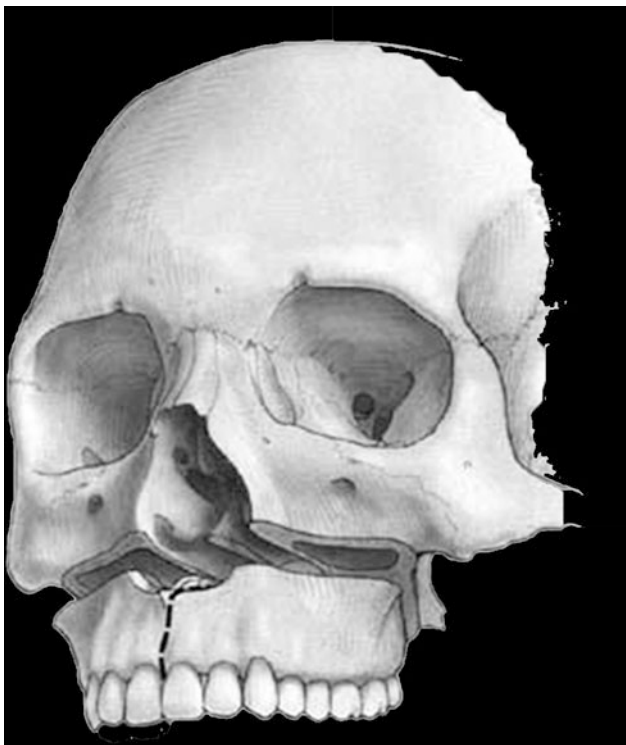
procedures may be necessary. Bilateral sagittal split osteotomy (Fig. 2.12) begins from an incision made about 1 cm from the lateral aspect of the molars and extended from midramus to the region of the second molar. A periosteal elevator is used to expose the lateral mandible and the anterior coronoid process in a subperiosteal plane. The medial aspect of the ramus is also dissected subperiosteally and the mandibular nerve should be identified. A Lindemann side-cutting burr is used to make a cut on the medial ramus that is parallel to the occlusal plane and extends about two-thirds of the distance to the posterior ramus. The cut extends from medial to lateral until the burr is in the cancellous portion of the ramus. A fissure burr or a reciprocating saw is used to make a cut from the midramus down along the external oblique ridge, gently curving to the inferior border of the mandible. The cuts are verified with an osteotome, and then large osteotomes are inserted and rotated to gently separate the segments. The tooth-bearing segment is referred to as the distal segment, and the condylar portion as the proximal segment. The distal segment is placed into occlusion and secured by tightening 26-gauge wire loops around the surgical lugs. If a surgical splint is necessary to establish the required occlusion, it is placed between the teeth prior to intermaxillary wiring. The proximal segment is then gently rotated to ensure it is seated



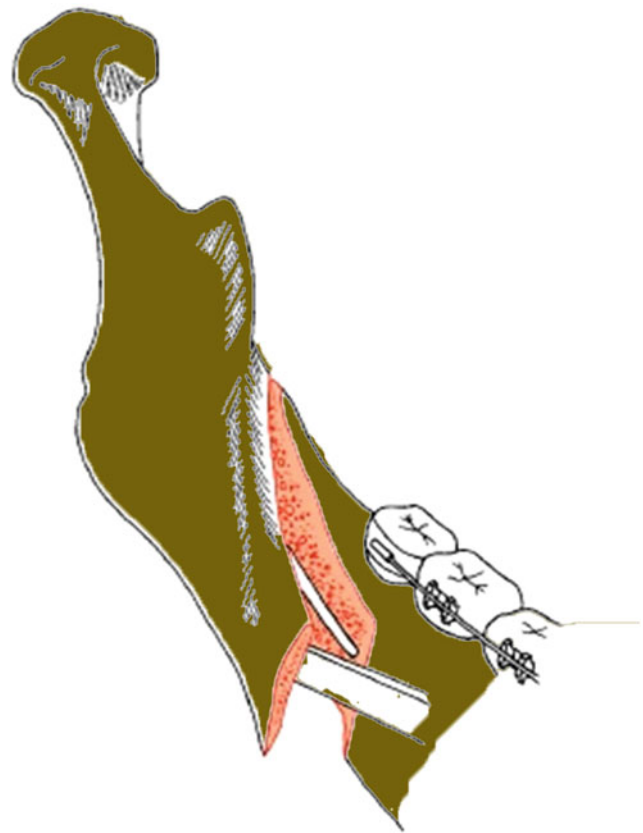


**Fig. 2.10** **a** Clinical views of a III Class with a disharmonic concave profile. **b** Facial convexity angle is the intersection of a line drawn from the forehead to the chin and a line drawn from the bottom of the

nose to the chin (glabella—SN—pogonion,  $165^{\circ}$ – $175^{\circ}$ ). **c** The patient sustained posterior impaction and advancement of the maxilla and mandible set back

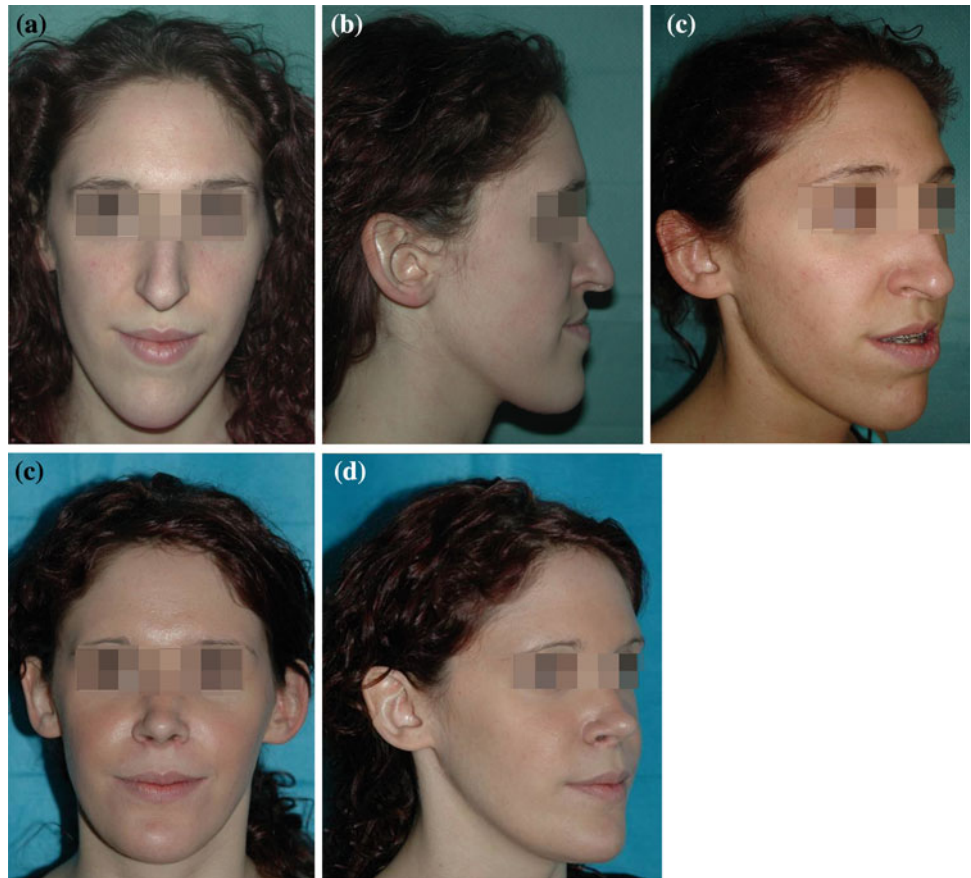

**Fig. 2.11** LeFort I osteotomy. The LeFort I osteotomy is designed to separate the tooth-bearing maxillary component from the superior part of the maxilla. The fracture line extends from the piriform aperture through the lateral maxillary and lateral nasal walls to the posterior region and will often include a segment of pterygoid plates



**Fig. 2.12** Sagittal split osteotomy of the mandible, mandibular osteotomic lines of the obwegeser/dal pont osteotomy; it is a bilateral sagittal split osteotomy of the mandible, ramus and angle, which can be extended into the posterior body. It divides the mandible into two smaller condyle-bearing segments and a large segment consisting of the mandibular body including the teeth and chin

**Fig. 2.13** A case of simultaneous surgical procedure in a female patient with skeletal Class III, nasal deformity, facial asymmetry, zygoma hypoplasia. **a–b–c:** Pre-surgical frontal, lateral and oblique view. **d–e–f:** Post-surgical result after LeFort I osteotomy, mandibular sagittal split osteotomy, mentoplasty, rhynoseptoplasty and lipostructure of the malar area



within the glenoid fossa. Rigid fixation is performed with one or two 2.0 mm plates on each side of the mandible. In a patient with prominent submental fat in whom mandibular advancement is contraindicated, suction-assisted lipectomy is helpful in removing the adipose deposits. The chin is an important component of the facial profile as well as the aesthetic balance. Osseous genioplasty, surgical correction of chin abnormalities by skeletal modification, has the potential of causing refreshing changes in facial harmony. In adult patients, orthognathic surgery can be combined with soft tissues contouring and ancillary procedures to improve aesthetic results. Lipostructure (also known as structural fat grafts, lipofilling, or fat grafting) is a technique with reproducible results. Lipofilling is a safe, long-lasting method of recontouring, filling and supporting the face using intricate layering of infiltrated autologous tissue. This method allows the tissues to be sculpted to enact three-dimensional augmentation of facial elements. To successfully use fatty tissue as such a graft, attention must be paid to the nature of fatty tissue, to the methods of harvesting, transfer and placement and to the preparation of the patient. Successful, three-dimensional sculpting requires attention to patient evaluation and meticulous planning. In 1988, the Coleman personally developed a technique called structural fat grafting (SFG), which allows the fat to be harvested and

injected with minimal risk of necrosis and reabsorption [12–14]. Simultaneous fat injection and orthognathic surgery allow a natural correction of malar hypoplasia, mandibular angle irregularities, or asymmetries.

Patients requiring surgical correction of skeletal deformities and malocclusion often present a coexisting functional and/or aesthetic nasal deformity. The nose has a prominent place in the face, so should ideally be corrected at the same time as the dentofacial disharmonies to achieve an attractive profile [15]. This is in line with Obwegeser's philosophy of 'profile before occlusion' [16]. There are two groups of patients with dentofacial abnormalities who will benefit from rhinoplasty: those with inherent nasal deformities and those who acquired deformities from the orthognathic surgery [17]. Some nasal deformities can be corrected by maxillary osteotomies: a narrow alar base, a slight droopy nasal tip and a mild dorsal hump, which can be corrected by Le Fort I advancement and impaction. Nasal deformities that cannot be improved by maxillary osteotomies include wide alar base, moderate to prominent dorsal hump, saddle nose, broad nasal base, and deformities of the tip and columella. Maxillary advancement can result in raising the tip with an increase in the supratip break depression, widening the alar base, and lowering the columella. Maxillary impaction can result in raising the nasal tip

and upper lip, widening the alar base and retracting the columella at the subnasal. Maxillary setback can result in widening the nasal bridge, an obtuse nasolabial angle and decreased projection of the nasal tip; maxillary downgraft can result in inferior positioning of the alar base and columella, a droopy nasal tip, and an obtuse nasolabial angle. Several advantages of simultaneous rhinoplasty and orthognathic surgery have been described by different authors: a single procedure, one general anaesthesia and stay in hospital for the patient, less post-operative discomfort from infraorbital hypoaesthesia and poor nasal outcome after orthognathic surgery can be corrected immediately, which avoids the prospect of dealing with an unhappy patient. Technically, the maxillary downfracture allows easier septoplasty, harvesting of the nasal septum, and resection of enlarged inferior turbinates. Surgeons who prefer to make the nasal infracture with guarded osteotomes can do so easily at the exposed piriform rim. Simultaneous rhinoplasty and orthognathic surgery minimize pre-operative, perioperative and post-operative problems. Good pre-operative planning is important for a successful outcome. Nasal changes that accompany maxillary osteotomies are taken into consideration when planning a rhinoplasty. Perioperatively, changing the nasotracheal to endotracheal intubation requires an experienced anaesthetist. While surgical oedema is inevitable, it can be reduced by a combination of pre-operative and perioperative steroids and hypotensive anaesthesia with effective surgery. Simultaneous correction of nasal, malar and angular deformities allows a major patient satisfaction (Fig. 2.13).

## References

1. Proffit WR, White RP, Sarver DM (2003) Contemporary treatment of dentofacial deformities. Mosby, St. Louis
2. Proffit WR, Turvey TA, Phillips C (2007) The hierarchy of stability and predictability in orthognathic surgery with rigid fixation: an update and extension. *Head Face Med* 3:21. doi: [10.1186/1746-160X-3-21](https://doi.org/10.1186/1746-160X-3-21)
3. Mendelson BC, Hartley W, Scott M et al (2007) Age related changes of the orbit and midcheek and the implications for facial rejuvenation. *Aesthetic Plast Surg* 31:419–423
4. O’Ryan F, Lassetter J (2011) Optimizing facial esthetics in the orthognathic surgery patient. *J Oral Maxillofac Surg* 69: 702–715
5. Arnett GW, Gunson MJ (2010) Esthetic treatment planning for orthognathic surgery. *J Clin Orthod* 44:196–200
6. Arnett GW, Gunson MJ (2004) Facial planning for orthodontists and oral surgeons. *Am J Orthod Dentofacial Orthop* 126: 290–295
7. Meneghini F, Biondi P (2012) Clinical facial analysis. Springer, Berlin
8. Baudouin JY, Tiberghien G (2004) Symmetry, averageness, and feature size in the facial attractiveness of women. *Acta Psychol* 117:313–332
9. Springer IN, Wannike B, Warnke PH et al (2007) Facial attractiveness: visual impact of symmetry increases significantly towards the midline. *Ann Plast Surg* 59:156–162
10. Zaidel DW, Cohen JA (2005) The face, beauty, and symmetry: perceiving asymmetry in beautiful faces. *Int J Neurosci* 115: 1165–1173
11. Larrabee WF Jr, Makielski K, Henderson JL (2004) Surgical anatomy of the face. Lippincott Williams & Wilkins, Philadelphia
12. Coleman SR (2001) Structural fat grafts: the ideal filler? *Clin Plast Surg* 28:111–119
13. Coleman SR (1998) Structural fat grafting. *Aesthet Surg J* 18:386–388
14. Coleman SR (1997) Facial recontouring with lipostructure. *Clin Plast Surg* 24:347–367
15. Cottrell DA, Wolford LM (1993) Factors influencing combined orthognathic and rhinoplastic surgery. *Int J Adult Orthodon Orthognath Surg* 8:265–276
16. Seah TE, Bellis H, Ilankovan V (2012) Orthognathic patients with nasal deformities: case for simultaneous orthognathic surgery and rhinoplasty. *Br J Oral Maxillofac Surg* 50:55–59
17. Obwegeser HL (2000) Mandibular growth anomalies. Terminology, aetiology, diagnosis, and treatment. Springer, Berlin



<http://www.springer.com/978-88-470-5360-1>

Injectons in Aesthetic Medicine

Atlas of Full-face and Full-body Treatment

Goisis, M. (Ed.)

2014, XI, 297 p. 825 illus., 3 illus. in color., Hardcover

ISBN: 978-88-470-5360-1