
Overview

Observations made during the interview begin the neurologic exam. You should note the patient's speech pattern, mentation, behavior, and even presence of abnormal motor movements. The neurologic exam is divided into specific components that are documented in the record. Doing the exam in an organized, stereotyped way will help to ensure that no component is missed. Below is a recommended order for the neurologic exam as it is commonly performed. For each area, there are additional tests that can be done (see comprehensive neurology textbooks for details). A video demonstrating the normal neurologic exam can also be viewed.

Mental Status Examination

The mental status exam can be more or less thorough depending on the presenting problem and your observations while taking the history. Areas to examine include alertness, attention, cooperation, memory, cognition, affect, speech, and language.

Alertness, attention, and cooperation are evaluated during the history. If the patient fails to demonstrate the ability to attend, to stay awake, or to cooperate, the remainder of the mental status exam should be interpreted cautiously. For

example, problems with memory may be due to the fact that the patient never paid attention to the information presented.

Memory problems are suggested by a vague imprecise history, inability to recall current events, or not remembering the events of the day. One can ask the patient to repeat three objects (like apple, table, and penny) immediately and then after 5 min. Normal subjects usually can repeat at least two of the objects at 5 min, especially with prompting.

Cognition should be evaluated relative to the patient's education and socioeconomic background. As an estimate of the patient's general mental capability, cognition includes reasoning, planning, solving problems, thinking abstractly, comprehending complex ideas, learning quickly, and learning from experience. If a deficit is detected, critical questions include the timing of the onset and whether it is progressive or static in course.

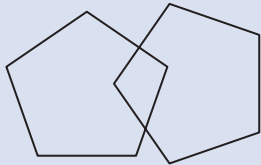
One useful screening test of mental status is called the *Folstein Mini-mental Status Exam* (Table 2.1). The test is not sensitive for mild cognitive impairment as scores as low as 22/30 may be normal depending on education and socioeconomic background.

Mood and affect are assessed during the mental status exam as psychiatric disease such as depression can present with memory complaints. When evaluating affect, it is important to note inappropriate tearful or jocular behavior that may not be congruous with the subject matter being discussed.

Speech and language abnormalities are divided into dysarthria and dysphasia. *Dysarthria* results

Electronic supplementary material The online version of this chapter (doi:-10.1007/978-1-4939-2359-5_2) contains supplementary material, which is available to authorized users.

Table 2.1 Folstein mini-mental status examination. (Adapted from [1])

Task	Instructions	Scoring	
Date orientation	“Tell me the date?” Ask for omitted items	One point each for year, season, date, day of week, and month	5
Place orientation	“Where are you?” Ask for omitted items	One point each for state, county, town, building, and floor or room	5
Register three objects	Name three objects slowly and clearly. Ask the patient to repeat them	One point for each item correctly repeated	3
Serial sevens	Ask the patient to count backwards from 100 by 7. Stop after five answers (Or ask them to spell “world” backwards)	One point for each correct answer (or letter)	5
Recall three objects	Ask the patient to recall the objects mentioned above	One point for each item correctly remembered	3
Naming	Point to your watch and ask the patient “what is this?” Repeat with a pencil	One point for each correct answer	2
Repeating a phrase	Ask the patient to say “no ifs, ands, or buts”	One point if successful on first try	1
Verbal commands	Give the patient a plain piece of paper and say “Take this paper in your right hand, fold it in half, and put it on the floor”	One point for each correct action	3
Written commands	Show the patient a piece of paper with “CLOSE YOUR EYES” printed on it	One point if the patient’s eyes close	1
Writing	Ask the patient to write a sentence	One point if sentence has a subject, a verb, and makes sense	1
Drawing	Ask the patient to copy a pair of intersecting pentagons onto a piece of paper	One point if the figure has ten corners and two intersecting lines	1
			
Scoring	A score of 24 or above is considered normal		30

from poor articulation—like talking with rocks in your mouth. The sentence makes sense but the sound is garbled. Abnormalities of the mouth (poor dentition) or CN IX, X, and XII dysfunction are common causes. Dysarthria does not affect the ability to read or write. *Dysphasia* implies dysfunction in constructing or understanding language. In expressive aphasia, the patient often speaks short truncated sentences without adjectives or adverbs but understanding is relatively preserved. Receptive aphasia usually has normal sounding speech but the content does not make sense relative to the question. In both dysphasias, there is difficulty in repeating phrases such as “No ifs ands or buts.” Dysphasia also affects the ability to read and write. Language abnormalities and apraxias are fully covered in the chapter on higher cortical function

Cranial Nerves

I. Olfaction is seldom routinely tested unless the patient has a complaint of poor taste or smell or history suggesting problems with frontal lobes or facial bones. First, ensure that there are no obstructions in the nasal passages by inspection with otoscope. Smell cannot be tested on each side separately since both sides of the nose communicate. Ask the patient to close their eyes and to identify the odor when presented and then identify the odor’s name. Common substances such as coffee grounds, unlit cigarettes, and perfumed soap are convenient to test. Use of alcohol or ammonia should not be used as those odors stimulate CN V fibers located in the anterior nose and give a false-positive test.

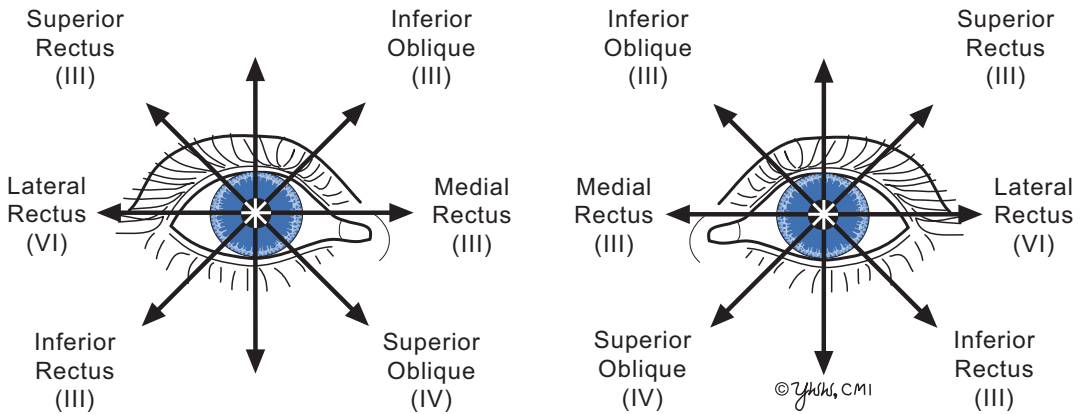


Fig. 2.1 Directions of gaze

II. Optic nerve function is usually divided into visual acuity, visual fields, and fundoscopic exam. To test *visual acuity* in each eye with their glasses, one can use a Snellen eye chart or a near-vision card. Ability to read standard newsprint suggests 20/40 or better acuity. If their glasses are not available, a pinhole card (paper with pin pushed through the center) can improve their vision. If visual acuity is 20/50 or better, the problem is usually ocular and not neurologic.

Visual fields are evaluated by confrontation testing each eye separately. Standing about 4 feet away with one eye closed and the patient looking at your nose, the patient is asked to count the number of fingers (1, 2 or 5) presented in the four visual quadrants. Confrontational testing can detect a homonymous hemianopia or quadranopia but not constriction of visual fields from glaucoma.

On fundoscopic examination, carefully observe the retinal vessels for hemorrhages and exudates and then follow them into the optic disc itself. Color and size of the disc and the presence of papilledema are particularly important. Papilledema is suggested by swollen optic disc heads with the margins appearing blurred/raised.

Pupil size and the light reflex involve CN II and autonomic eye nerves. Observe the pupils in dim light with illumination from below. The pupils should be round and be within 1 mm of each other in size and constrict equally when the patient attempts to look at their nose (*accommodation*). Anisocoria or unequal pupil sizes signifies dysfunction of sympathetic nerve (small pupil or miosis) or parasympathetic nerve (large pupil or

mydriasis). In the *light reflex*, one tests a direct light reflex (the pupil constricts when a light is shined into it) and then a consensual reflex (the opposite pupil constricts when a light is shined into the other). Both pupils should constrict briskly and equally to light. Shining the light into one eye and failing to see both pupils to constrict imply ipsilateral retina or CN II dysfunction, failure of ipsilateral iris to constrict implies dysfunction of ipsilateral sympathetic nerve, and failure of contralateral pupil to constrict suggests dysfunction of contralateral sympathetic nerve.

III, IV, VI. Oculomotor, trochlear, and abducens nerves innervate the extraocular eye muscles. They are evaluated by observing the eye move correctly when the patient is asked to follow your finger in all nine directions of gaze (Fig. 2.1). Observe whether the eye movements are conjugate (move together), move the entire range, and are smooth. Presence of double vision in one gaze direction suggests dysfunction of a given nerve or eye muscle. In Fig. 2.2, a patient with a right CN VI palsy is unable to move his right eye laterally. *Nystagmus* can be seen in healthy people at the far end of horizontal gaze, but is an abnormal sign at rest, near mid position or is sustained.

The size of the palpebral fissure (distance between upper and lower eyelid) depends on CN III and sympathetic nerves. Marked drooping of the upper eyelid (ptosis) that interferes with vision implies CN III dysfunction or prior eye trauma. Mild ptosis without obstructing vision implies sympathetic nerve dysfunction. When mild ptosis is

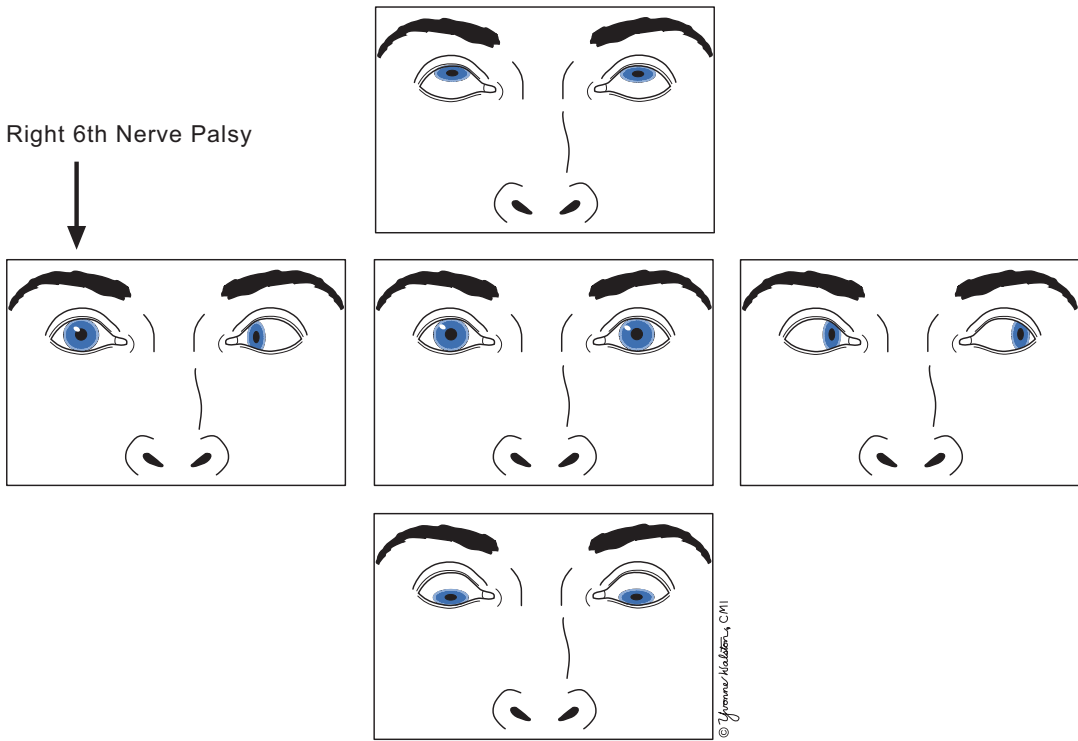


Fig. 2.2 Right 6th nerve palsy

accompanied by ipsilateral miosis (pupillary constriction), the lesion is called Horner's syndrome.

V. Trigeminal nerve function is tested by evaluating face sensation. Lightly touch the 3 divisions of the CN V with a cotton tip, your fingers or a cool tuning fork. The patient should perceive these as equal on both sides. The corneal reflex (touching the edge of the cornea over the outside of the iris with a wisp of cotton or a soft facial tissue) should produce prompt blinking of both eyes. Failure to blink in either eye suggests an afferent problem in the stimulated CN V, failure of ipsilateral eye but not contralateral eye to blink suggests dysfunction of ipsilateral CN VII, and failure of contralateral eye to blink but not ipsilateral eye suggests dysfunction of contralateral CN VII. Having the patient open her jaw and attempt to move the jaw laterally against resistance test motor fibers of CN V.

VII. Facial nerve function is evaluated by testing facial muscles. Ask the patient to open her eyes wide, close them shut tightly and pull back her lips. The muscles of facial expression, inner-

vated by CN VII, should show equal and symmetrical movement on both sides of the face.

A lower motor neuron lesion (facial nerve or nucleus) produces weakness of both the upper and lower face. An upper motor neuron lesion (corticobulbar tract above the level of CN VII nucleus) causes weakness only of the lower face because forehead muscles receive bilateral innervation.

The chorda tympani nerve branch can be tested by determining whether the patient can detect the taste of sugar or salt placed on the anterior two-thirds of one side of the tongue.

VIII. Auditory nerve hearing evaluation is tested by masking the opposite ear with finger or sounds and determining whether the patient can hear whispers (mid sound frequencies) or rubbing fingers (higher sound frequencies) in the other ear. If there is hearing loss, the external auditory canal should be inspected with an otoscope. *Vestibular* nerve testing is described in the chapter on dizziness and vertigo.

IX. *Glossopharyngeal nerve* function is tested by asking patient to say, “aah” and observing the soft palate and uvula rising symmetrically. Deviation of the uvula and soft palate to one side indicates a lesion on the contralateral nerve. Touching the pharynx with a cotton Q-tip should elicit a gag reflex from CN IX and X.

X. *Vagus nerve* function is tested by listening for hoarseness in the patient’s voice. If present, vocal cord movements can be visualized by otolaryngology to confirm paralysis.

XI. *Accessory nerve* function is tested by shoulder shrug and head turn. Ask the patient to shrug her shoulders to her ears and then push down. Strength should be symmetric. Then ask her to turn her head to either side while you apply resistance with your entire hand on her lower jaw. Again, strength should be symmetric. Remember that the right sternocleidomastoid muscle turns the head to the left.

XII. *Hypoglossal nerve* function is evaluated by asking a patient to protrude the tongue straight out and moving it from side to side. Deviation of the tongue to one side with atrophy and fasciculations in that side of the tongue suggests an ipsilateral lower motor neuron lesion.

Neck: The patient should be able to smoothly flex her neck to touch her chin on the chest and rotate the head fully towards the shoulders. In meningitis, the patient cannot flex or resists flexing the neck while in cervical arthritis, there is restricted rotation of the neck, called meningismus.

Motor Examination

A complete motor examination includes the evaluation of muscle bulk, tone, strength, and gait. In addition, any involuntary movements should be noted.

Muscle bulk compares the size of muscles on each side. In particular observe the hands for atrophy of small intrinsic muscles and feet for atrophy of intrinsic foot muscles seen by permanent elevation of toes at the second metatarsal joints (hammer toes). Atrophy from lower motor neuron lesions (denervation) shrinks a muscle by two-thirds its normal size. If the denervation is

Table 2.2 British Medical Research Council method of scoring muscle strength

Score	Strength finding
0	No movement
1	Flicker movements
2	Movement with gravity eliminated
3	Movement against gravity only
4	Full movement against some resistance
5	Full movement against full resistance

active, fasciculations are seen. Upper motor neuron lesions, disuse, or deconditioning reduces bulk by only one-third without fasciculations.

In evaluating *muscle tone*, the patient is asked to relax like being a “rag doll” while you move the limbs through extension, flexion, and rotation. Think of the tone as a rubber band and decide if she is floppy (hypotonic), normal, or too tight (spasticity or rigidity). Hypotonia suggests a cerebellar or lower motor neuron lesion. Spasticity is increased tone that depends on how quickly you move the limb—with faster movement, there is more spasticity and with slow movement, less increase in tone. Rigidity is resistance to limb movement that is consistent through the entire range (like bending a lead pipe) as seen in Parkinson’s disease.

Muscle strength is commonly evaluated using the British Medical Research Council method where strength is graded on a relative scale of 0 to 5 (Table 2.2). In this relative system, the muscle strength of both a healthy grandmother and a young male weightlifter would both be scored at 5. The value of this scoring system is that it is highly reproducible between examiners. The disadvantage is that it is insensitive to slight worsening of mild weakness since both would be scored 4.

Since there are over 400 muscles in the human body, it is useful to group muscles into proximal and distal muscles (Table 2.3). It is helpful to ask the patient to flex or extend the limb and hold it there against your force. Start with minimal pressure and then increase until maximal or the limb gives way. True weakness tends to be gradually overcome as pressure increases. Give-way or suddenly “letting go” of a position by a patient may indicate pain in a limb or reluctance to give “full effort”.

Table 2.3 Muscles commonly tested and their nerve root and peripheral nerve

	Muscle and (function)	Nerve root	Peripheral nerve
<i>Proximal arm</i>	Deltoid (adducts shoulder)	C5	Axillary
	Biceps (flexes elbow)	C5	Musculocutaneous
	Triceps (extends elbow)	C7	Radial
<i>Distal arm</i>	Flexor carpi radialis and ulnaris (wrist flexors)	C6–7	Median and ulnar
	Extensor carpi radialis and ulnaris (wrist extensors)	C6–8	Radial
	Abductor pollicis brevis (abducts thumb)	C8	Median
	Abductor digiti minimi (abducts little finger)	T1	Ulnar
<i>Proximal leg</i>	Iliopsoas (hip flexion)	L2–4	Femoral
	Quadriceps (knee extension)	L2–4	Femoral
	Hamstrings (Knee flexion)	L4–S1	Sciatic
<i>Distal leg</i>	Tibialis anterior (ankle dorsiflexion)	L4–5	Peroneal
	Gastrocnemius (ankle flexor)	S1–2	Tibial
	Tibialis posterior (ankle inversion)	L5	Tibial
	Extensor hallucis longus (dorsiflexes great toe)	L5–S1	Peroneal
	Foot flexors (dorsiflexion of all toes)	L5–S1	Tibial

Weakness comes from many anatomic locations. Figure 2.3 gives the key anatomy of the corticospinal tract that produces upper motor neuron lesions. Chapters on the approach to the patient and disorders of muscle, neuromuscular junction, peripheral nerve, spinal cord, brainstem, and cerebrovascular disease give additional ways to evaluate the motor system.

Gait evaluation is the most useful screening test of the motor system. Ask the patient to get out of chair and walk normally, on toes and heels, and turn. One can also ask a patient to hop or walk backwards. Observe for smoothness of the gait, posture of the trunk and arms, unsteadiness during turns, appropriate arm swing, and any balance abnormalities. The presence of an asymmetrical gait or limp can be caused by many processes such as hemiparesis, leg joint arthritis, old fractures, balance problems, or even leg pain that must be sorted out during the rest of the neurologic exam.

Balance can be evaluated by using the Romberg position and tandem gait. In the Romberg test, the individual is asked to put her feet together and balance with her eyes open. If the balance is normal, the patient is asked to close her eyes, thus assuming the Romberg position. Marked sway or loss of balance with eyes closed, but not when open, is the Romberg sign. This sign is usually due to poor position sense in the feet. In tandem walking, the patient attempts to walk heel

to toe in a straight line. Abnormal tandem gait implies dysfunction of inner ear, position sensors in the feet, vestibular brainstem/cerebellar nuclei or tracts, or orthopedic leg problems.

Involuntary movements should be noticed during the history and exam. In general, the movements should be characterized by: (1) location (bilateral vs. unilateral, upper extremities vs. lower extremities); (2) duration (continuous vs. intermittent); (3) provoking factors (at rest vs. posture vs. action); and (4) alleviating factors (change of position vs. voluntary suppression). Types of involuntary movements include tremor, dystonia, chorea, ballismus, tics, and myoclonus. Most involuntary movements are due to disorders of the basal ganglia and that chapter describes these involuntary movements.

Coordination

For coordination to be tested accurately, the patient must have normal or near-normal muscle strength of their limbs. The finger–nose–finger test asks the patient to touch the tip of the index finger to her nose, then to the examiner’s finger, and back to the nose again. Cerebellar dysfunction causes a tremor perpendicular to the direction of movement that intensifies as the finger nears the target and is especially worse coming

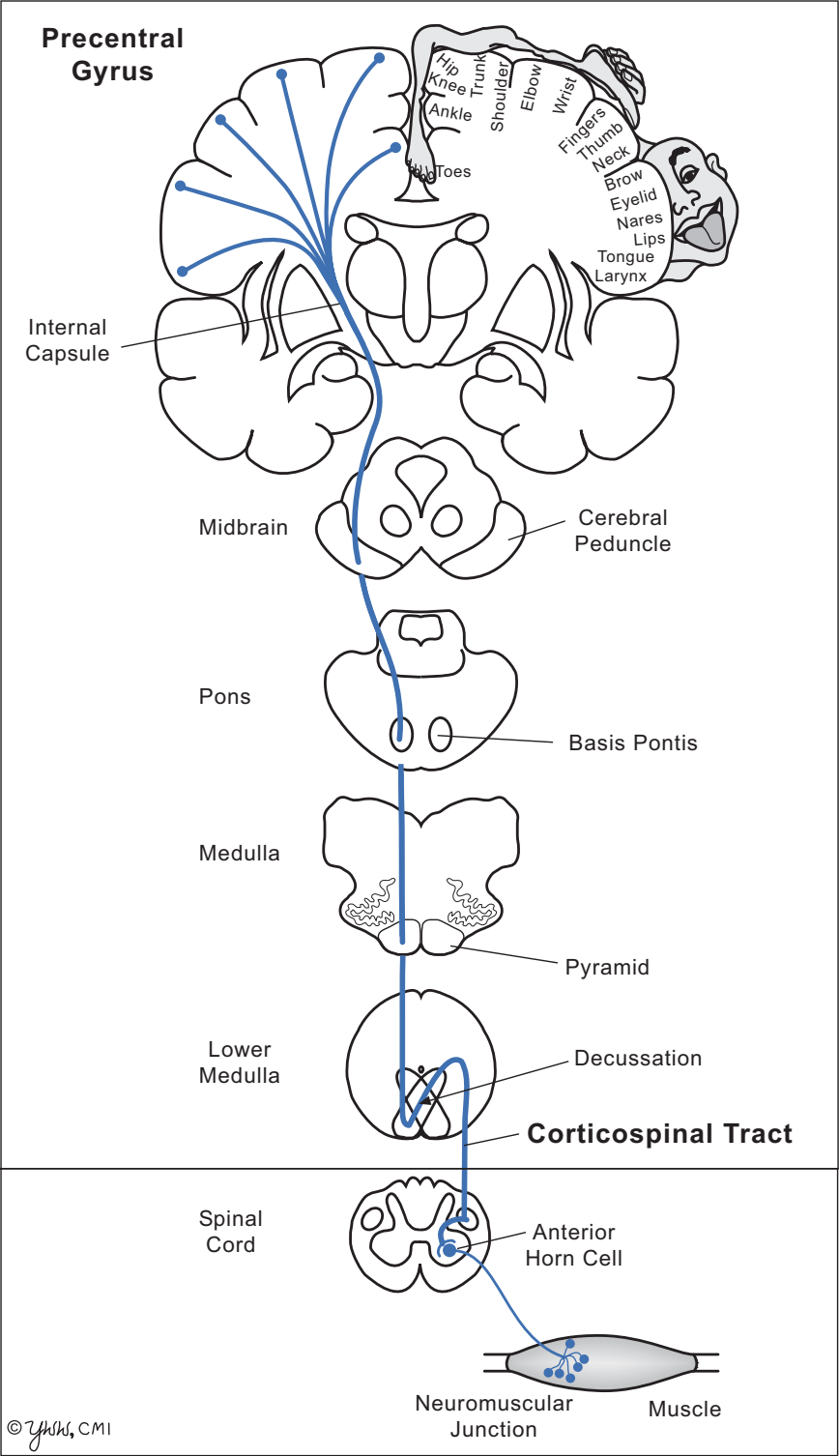


Fig. 2.3 Anatomy of the corticospinal tract

in to the nose. The heel-to-shin test asks the patient to place a heel on the opposite knee with the ankle dorsiflexed and then slide the heel down the front of the shin to the great toe. Again cerebellar dysfunction causes the heel to move perpendicular to the line of heel movement. Rapid alternating movement test asks the patient to pat the knee with the palm and then the back of the hand as she gradually increases the speed.

Sensation

The evaluation of sensation is often divided into small unmyelinated nerve fiber peripheral nerve functions (pain, temperature), larger thinly myelinated nerve fiber functions (vibration, position sense) and cortical sensory functions (stereognosis, graphesthesia, two-point discrimination). Normally, the tests are performed on the hands and feet unless the history or exam suggests damage to particular nerves or roots (Fig. 2.4a, b).

Pain is usually tested with a new safety pin and the patient is asked to determine whether the gentle prick was “sharp” from pin edge or “dull” from clip edge. One compares the sides and other areas in the limb. Pain stimulates both unmyelinated and thinly myelinated sensory fibers. Always discard the safety pin when finished.

Temperature is usually tested with a cool metal object such as a tuning fork. The control temperature for comparison is the face or upper arm. The patient is asked whether the test skin area is as cool as the control skin area. The test is usually done on the dorsum of the foot and moves up the leg until the temperature is perceived as cool.

Vibration is tested with a 128 cps tuning fork by pressing the stem over the great toe and placing your finger beneath the toe. The patient is asked to say when the vibration disappears, which should be when you can no longer feel it vibrate in your finger. The tuning fork is moved up the leg proximally until the patient perceives the vibration well. If the toes have normal vibration sensation, testing the fingers is seldom necessary.

Position sense is determined by grasping the great toe on the sides and instructing the patient

to respond “up or down” from where the toe was last time. Move the toe only a millimeter or two. If the patient has trouble distinguishing up or down, you can move the toe in a larger arc until you are satisfied they can detect movement. If the toes are normal, testing the fingers is seldom necessary.

Stereognosis is tested with the eyes closed and asking the patient to identify simple objects placed in the hand, such as coins or a key. *Graphesthesia* is tested with the eyes closed and asking the patient to identify numbers or letters written on the palm of each hand. These tests require normal primary sensation and abnormalities imply dysfunction in the contralateral sensory cortex or parietal lobe (see chapter on higher cortical function).

Reflexes

Deep tendon reflexes (DTRs) or stretch reflexes evaluate a local circuit from muscle spindles to spinal cord level and back to appropriate muscles. The most common reflexes tested are biceps jerk (TJ), triceps jerk (TJ), knee jerk (KJ), and ankle jerk (AJ) (Fig. 2.5). Position the patient comfortably, usually with arm resting on the thigh and feet just touching the exam step or the floor. Using a long well-balanced hammer with a soft percussion tip, tap the tendon to deliver the stimulus. The key is to be consistent in the application of force. If the reflex is difficult to attain, it can be augmented by asking the patient to grit her teeth or make a fist with the other hand. Children and young adults, especially if anxious or cold, tend to have brisk reflexes while the elderly often have diminished reflexes. DTR are scored per Table 2.4.

The extensor *plantar reflex* or *Babinski sign* suggests damage to the corticospinal tract (upper motor lesion) in children older than 2 years and adults. It is elicited by scratching the sole of the foot from the heel, along the lateral aspect of the foot, and finally arching across the ball of the foot to the great toe. The Babinski sign is present if the great toe extends—often with fanning of the other toes accompanying the great toe exten-

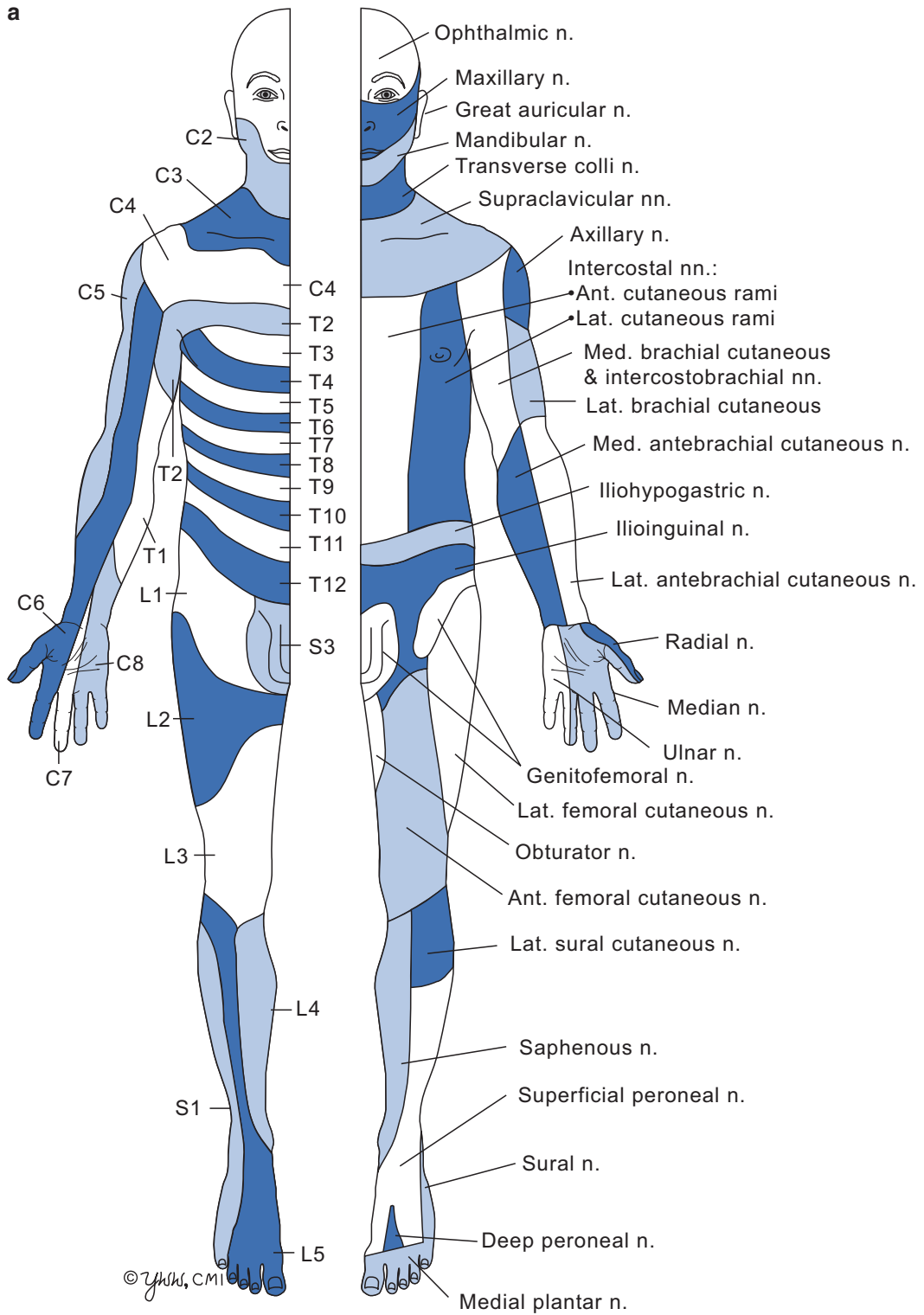
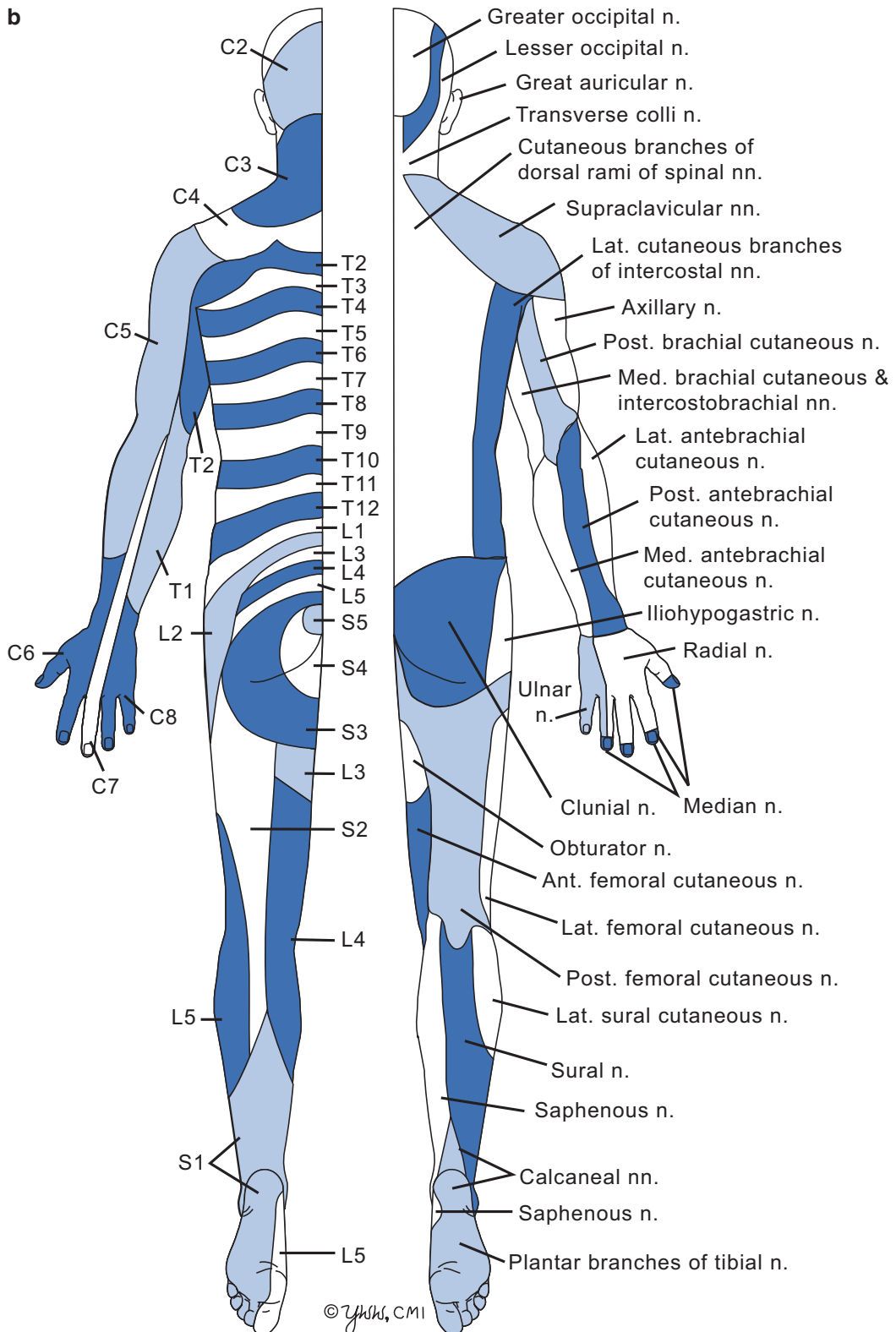


Fig. 2.4 Dermatomes and peripheral nerve distributions. **a** Anterior view.

b**Fig. 2.4** (continued) **b** Posterior view

<http://www.springer.com/978-1-4939-2358-8>

Fundamentals of Neurologic Disease

Davis, L.E.; Pirio Richardson, S.

2015, XV, 294 p. 101 illus., 72 illus. in color. With online files/update., Softcover

ISBN: 978-1-4939-2358-8