

Chapter 2

Category I: Nondiagnostic

Background

Nondiagnostic is used independent of the term unsatisfactory. Unsatisfactory (for evaluation) indicates that a specimen is not able to be evaluated rather than not able to be interpreted or diagnosed. Any specimen that is processed is able to be evaluated, and as such, there is a corresponding technical billing component for that process. The inability to make a diagnosis or meaningful interpretation from a specimen by a pathologist relative to the lesion sampled indicates that the biopsy is evaluated under the microscope, correlated with imaging and ancillary testing, and deemed nondiagnostic.

Nondiagnostic specimens may result from technical or sampling issues. The clinical and imaging context should always be taken into consideration. For example, normal pancreatic tissue may well be representative of vague fullness of the pancreas with no discrete mass. The absence of “epithelial cells” in the sample does not necessarily make a specimen nondiagnostic. There is no established set number for cellular adequacy in pancreaticobiliary cytology, especially with the advent of endoscopic ultrasound fine-needle aspiration (EUS-FNA) where gastrointestinal (GI) contamination contributes to specimen cellularity. Rare high-grade malignant cells may be sufficient for a definitive diagnosis of adenocarcinoma, whereas numerous well-differentiated glandular sheets may not be enough for a confident diagnosis of well-differentiated adenocarcinoma in the setting of a transgastric FNA. Cyst fluids also have few to no epithelial cells. Pseudocysts, by definition, have no epithelial component; thick, colloid-like mucin without an epithelial component supports the interpretation of a mucinous cyst, not otherwise specified; and just a few well-preserved high-grade epithelial cells in a mucinous background is sufficient to interpret a high-risk mucinous cyst leading to proper patient management.

Pathologist experience and expertise in interpreting pancreaticobiliary cytology specimens also contributes to the threshold of what is considered nondiagnostic. Repeat sampling of the pancreas is much more involved and expensive than repeat sampling of superficial lesions. As such, it is in the best interest of patient care to maximize the evaluation of the pancreatic biopsy with proper specimen triage for ancillary testing and to obtain a second opinion on the microscopic findings if in doubt about the interpretation of the sample.

Definition A nondiagnostic cytology specimen is one that provides no diagnostic or useful information about the lesion sampled. Any cellular atypia precludes a nondiagnostic report.

Cytological Criteria Nondiagnostic (Figs. 2.1, 2.2, 2.3, 2.4, and 2.5)

- Preparation artifact precludes evaluation of the cellular component.
- Obscuring artifact precludes evaluation of the cellular component.
- Gastrointestinal epithelium only.
- Normal pancreatic tissue elements in the setting of a clearly defined solid or cystic mass by imaging.
- Acellular aspirates of a solid mass or pancreaticobiliary brushing.
- Acellular aspirate of a cyst without evidence of a mucinous etiology such as thick colloid-like mucus, elevated CEA or *KRAS* or *GNAS* mutation (See Chap. 6).

Fig. 2.1 Nondiagnostic. Tissue is uninterpretable due to obscuring blood clot. Tissue casts and clots expressed onto glass slides should be picked up off the glass slide with the needle tip and placed in formalin for processing as a cellblock. (Direct smear; Hematoxylin and Eosin)

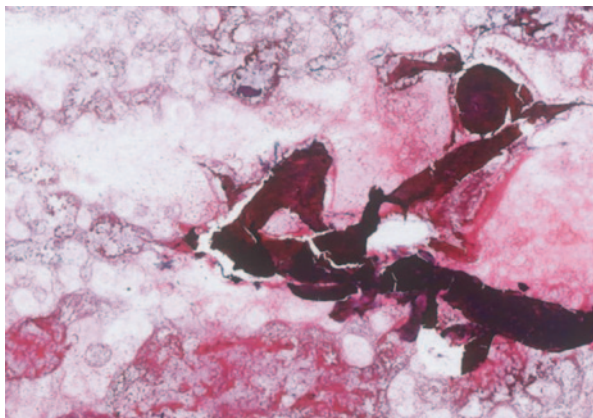
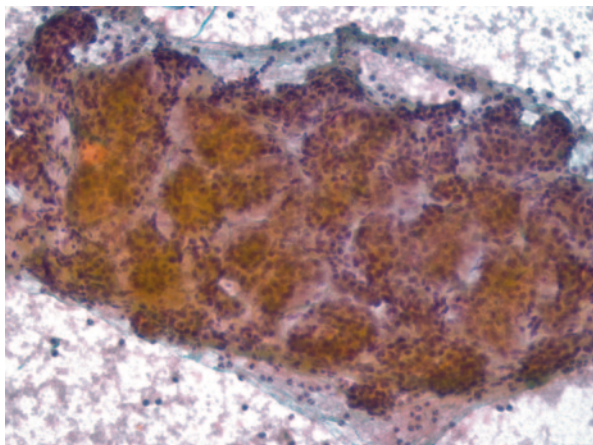


Fig. 2.2 Nondiagnostic. Normal pancreatic acinar tissue. When an FNA is performed to evaluate a discrete solid or cystic mass lesion, normal pancreatic tissue does not explain the mass and indicates a sampling error. Benign tissue may be present in the setting of chronic pancreatitis where fibrosis forms a mass lesion, but normal appearing acinar tissue is nondiagnostic. (Direct smear; Papanicolaou)



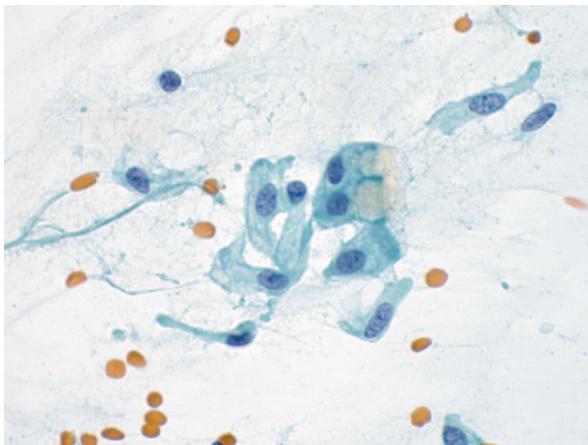
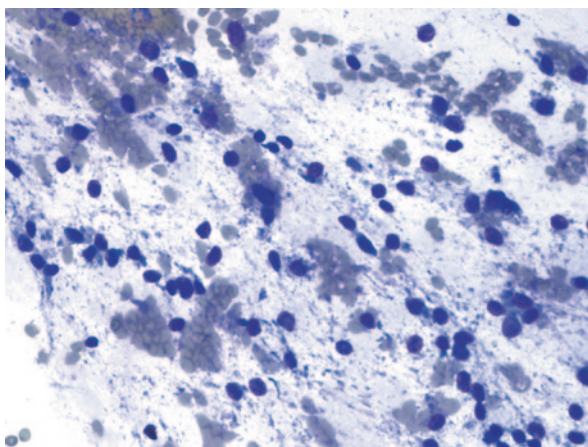


Fig. 2.3 Nondiagnostic. Few gastric epithelial cells only. Recognizing gastric and duodenal epithelial contamination is critical to accurate interpretation of EUS-FNAs. Benign gastric epithelial cells from the EUS-FNA of a solid mass lesion are easily recognized as contamination. It is more challenging to differentiate gastric epithelium from low-grade dysplasia of a mucinous cyst. The organ traversed (duodenum versus stomach), ancillary testing results (CEA and *KRAS* or *GNAS* mutations), and quality and quantity of the gastric-type epithelium all contribute to the decision to classify an FNA as nondiagnostic. (Direct smear; Papanicolaou)

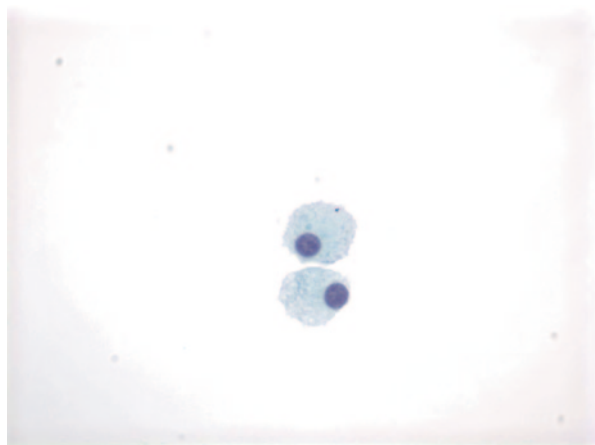
Fig. 2.4 Nondiagnostic. Stripped naked nuclei consistent with gastric contamination. Gastric epithelial cells may lose their cytoplasm and form a sea of naked nuclei, some with nuclear grooves, entrapped in a mucoid background. The phenomenon is not a feature of mucinous cystic lesions. (Direct smear; Diff-Quik)



Explanatory Notes

It is very important for the pathologist to take into consideration the imaging characteristics of the lesion being sampled and all ancillary testing performed on the specimen when determining whether a biopsy is nondiagnostic. This is particularly important for pancreatic cysts. Cyst fluid analysis with biochemical and molecular testing is a vital component of the overall evaluation of the specimen and should be

Fig. 2.5 Nondiagnostic. Thin, clear cyst fluid with rare histiocytes, CEA of 85 ng/ml, which is not elevated above our cutoff level of 192 ng/ml to support a mucinous cyst and no *KRAS* or *GNAS* mutations to support a mucinous etiology. (Cytospin; Papanicolaou)



incorporated into and reported with the specimen when available, just like with any pathology specimen where ancillary testing refines the diagnosis (see Chap. 6 and sample reports below). CEA and amylase testing should be available at the time of sign out whereas molecular testing usually takes longer. A low CEA and unavailable molecular result may well lead to a nondiagnostic report.

Rapid on-site evaluation (ROSE) is a valuable tool for ensuring that diagnostic tissue is obtained from FNAs of solid pancreatic masses [1–3]. ROSE is not recommended, however, for pancreatic cysts. Cyst fluid is optimally processed using a strict volume triage protocol to maximize the information from the cyst fluid, which includes assessment for CEA, amylase, and in selected cases, molecular mutations [4].

Management

A nondiagnostic cytology specimen is a “non-test,” e.g., the test does not provide any information about the lesion being sampled. Clinical and imaging data thus become the sole means for evaluating the patient. If the imaging features are sufficiently suspicious for a high-risk lesion to proceed to surgery, this may be elected rather than attempting to obtain diagnostic tissue by cytologic methods. For patients with unresectable imaging, however, a diagnostic tissue biopsy is required prior to instituting neoadjuvant therapy [5].

A nondiagnostic bile duct brushing may be followed with a repeat brushing or an FNA of the surrounding stricture site [6]. A nondiagnostic percutaneous FNA should be followed by an EUS-FNA, even if referral to an institution with expertise in EUS-FNA is required [7, 8]. A repeat EUS-FNA for a nondiagnostic EUS-FNA is generally more cost-effective than other means of obtaining diagnostic tissue such as laparoscopy or laparotomy [7].

Sample Reports

Example 1:

Satisfactory for evaluation.
Nondiagnostic.
Gastrointestinal contamination only.

Example 2:

Satisfactory for evaluation.
Nondiagnostic.
Normal acinar and ductal epithelium. The biopsy does not explain the well-defined pancreatic mass seen on imaging.

Example 3:

Evaluation limited by preparation artifact.
Nondiagnostic.
Tissue entrapped in blood clot and fibrin precluding cytological evaluation.

Example 4:

Evaluation limited by scant cellularity.
Nondiagnostic.
Cyst fluid with scant thin extracellular mucin of uncertain origin and rare histiocytes. No epithelial cells present. See note.
Note: No cyst fluid analysis is available to further characterize the cyst.

References

1. Chen J, Yang R, Lu Y, Xia Y, Zhou H. Diagnostic accuracy of endoscopic ultrasound-guided fine-needle aspiration for solid pancreatic lesion: a systematic review. *J Cancer Res Clin Oncol*. 2012;138(9):1433–41.
2. Collins BT, Murad FM, Wang JF, Bernadt CT. Rapid on-site evaluation for endoscopic ultrasound-guided fine-needle biopsy of the pancreas decreases the incidence of repeat biopsy procedures. *Cancer Cytopathol*. 2013;121(9):518–24.
3. Hebert-Magee S, Bae S, Varadarajulu S, et al. The presence of a cytopathologist increases the diagnostic accuracy of endoscopic ultrasound-guided fine needle aspiration cytology for pancreatic adenocarcinoma: a meta-analysis. *Cytopathology*. 2013;24(3):159–71.
4. Pitman MB. Pancreatic cyst fluid triage: a critical component of the preoperative evaluation of pancreatic cysts. *Cancer Cytopathol*. 2013;121(2):57–60.
5. Gillen S, Schuster T, Meyer Zum Buschenfelde C, Friess H, Kleeff J. Preoperative/neoadjuvant therapy in pancreatic cancer: a systematic review and meta-analysis of response and resection percentages. *PLoS Med*. 2010;7(4):e1000267.
6. Rosch T, Hoffrichter K, Frimberger E, et al. ERCP or EUS for tissue diagnosis of biliary strictures? A prospective comparative study. *Gastrointest Endosc*. 2004;60(3):390–6.
7. Suzuki R, Lee JH, Krishna SG, et al. Repeat endoscopic ultrasound-guided fine needle aspiration for solid pancreatic lesions at a tertiary referral center will alter the initial inconclusive result. *J Gastrointest Liver Dis*. 2013;22(2):183–7.
8. Kurtycz D, Tabatabai L, Michaels C, et al. Postbrushing and fine-needle aspiration biopsy follow-up and treatment options for patients with pancreatobiliary lesions: the papanicolaou society of cytopathology guidelines. *Diagn Cytopath*. 2014;42(4):363–71.

The Papanicolaou Society of Cytopathology System for
Reporting Pancreaticobiliary Cytology

Definitions, Criteria and Explanatory Notes

Pitman, M.B.; Layfield, L.

2015, XV, 96 p. 70 illus. in color., Softcover

ISBN: 978-3-319-16588-2