

2.1 Embryology and Penile Development

Between the fourth and seventh weeks, the mesodermal mesenchyme migrates to the cranial aspect of the cloacal membrane to form the genital tubercle. The cloacal membrane itself is composed of two layers: endoderm and ectoderm. The caudal portion of the cloacal membrane develops into urogenital folds. These structures are the precursors for external genitalia in both males and females. In those with a Y chromosome, the SRY gene signals the differentiation of primitive sex cords into the testes by first signaling the development of Sertoli cells. Sertoli cells then aid in the development of germ cells and Leydig cells within the testes. Leydig cells produce testosterone, which is converted to dihydrotestosterone to induce external genitalia development. Normal embryogenesis of the male genitalia involves the formation of the penis and scrotum. The early development of the external genitalia in the two sexes is similar before the ninth week of gestation. Understanding factors and sequential steps in normal embryogenesis is fundamental in the comprehension of the pathogenesis of male genital anomalies. These factors include testosterone synthesis by the fetal testis and its enzymatic conversion into dihydrotestosterone by 5 α -reductase and the presence of androgen receptors able to recognize the androgenic hormones. The influence of dihydrotestosterone on

the androgen receptors results in the differentiation of the genital tubercle, genital (labioscrotal) folds, and genital swelling between 9 and 13 weeks of gestation into the male structures of the glans penis, penile shaft, and scrotum, respectively [1].

The male develops in a proximal to distal manner. As the penis forms from the elongation and enlargement of the phallus, the lateral walls of the urethral groove form from the ventrally located genital folds. The genital folds then fuse in the midline. The glanular urethra forms from the ingrowth of surface epithelium, but this long-held theory has been challenged with evidence suggesting that it is due to the fusion of the urethral plate. The scrotum forms through the inferomedial migration and midline fusion of the genital folds as delineated by the scrotal raphe. In females and in males with abnormalities in testosterone and/or dihydrotestosterone production, 5 α -reductase deficiency, or androgen receptor insufficiency, the genital tubercle, genital folds, and genital swellings passively become the clitoris, labia minora, and labia majora, respectively.

Congenital penile or scrotal anomalies can be isolated variations of external genitalia development, or they can represent significant underlying malformations. Prompt diagnosis and potential surgical planning are essential to allay the anxieties of parents as well as to identify other potentially clinically significant conditions. Congenital

penile anomalies have been shown to be increasing in incidence. The weighted incidence of anomalies including hypospadias has increased from 7 of every 1,000 newborns (1988–1991) to 8.3 of every 1,000 newborns (1997–2000), but this may be a result of increased reporting. Multiple etiologies in abnormal development have been proposed, including genetic, hormonal, and environmental influences. Whereas molecular pathology has aided in the identification of key steps in abnormal development, modern imaging techniques continue to refine the evaluation and treatment of such anomalies [2].

2.2 Penile Agenesis (PA)

Nomenclature

Aphallia, apenia, ablatio penis, penile agenesis

Definition

Congenital absence of the penis, which is a rare anomaly caused by developmental failure of the genital tubercle

Historical Background

The earliest case report of aphallia was by Imminger in 1853; since then approximately 80 cases have been reported in the literature, but very recently many cases in the process of reporting [3].

Approximate Incidence

1 in 10–30 million population, the incidence of stillbirth or neonatal death is approximately one-third of cases.

The phallus is completely absent, including the corpora cavernosa and corpus spongiosum. Usually, the scrotum is normal and the testes are undescended, but there are many cases reported where both testicles are normally descended with normal development (Figs. 2.1 and 2.2).

The urethra opens at any point of the perineal midline from over the pubis to, most frequently, the anus or anterior wall of the rectum. In Fig. 2.3, no urethral opening could be appreciated.

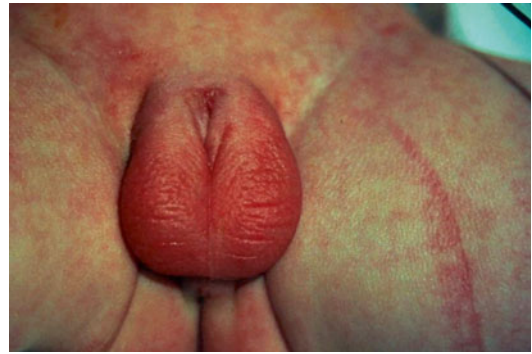

Fig. 2.1 Complete aphallia with normal scrotum and testicles

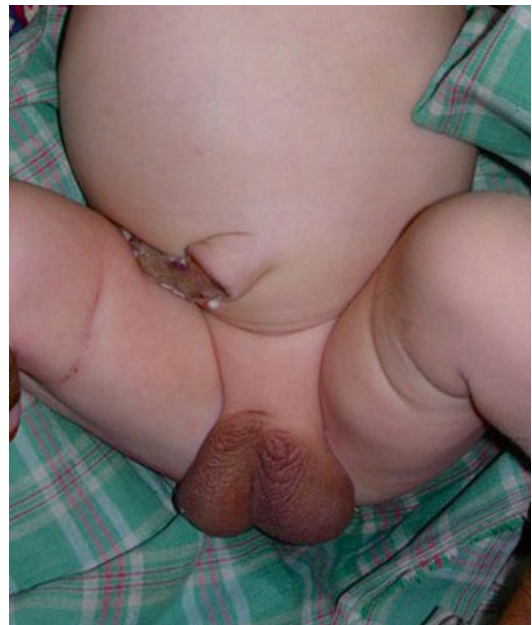

Fig. 2.2 Neonate with aphallia and normal testicle

Etiology

Agenesis of the penis occurs as a consequence of single gene disorders, teratogenic effects, or malformation sequences and associations of unrecognized patterns of anomalies. It thus should be considered a developmental field defect. Its concurrence with scrotal hypoplasia, absent raphe, and anal anomalies implies a major disturbance of the caudal mesoderm; in such cases severe renal defects are usually seen, and the prognosis is poor. When the patient has a patent urethra and normal scrotum, raphe, and testes, the baby may

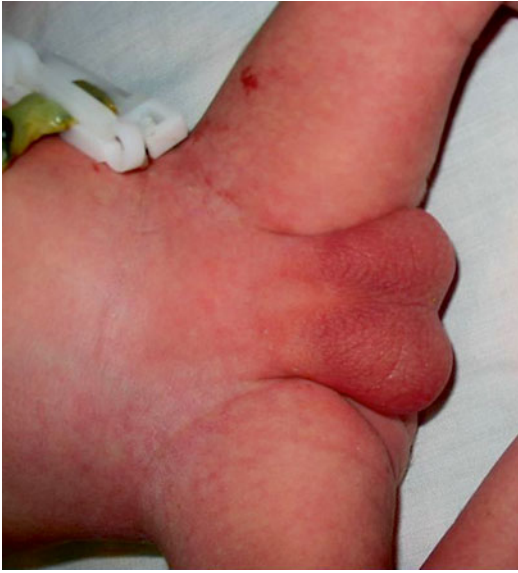

Fig. 2.3 Aphallia without urethral opening

survive with such anomaly; however, penile agenesis may be a localized malformation of the genital tubercle potentially related to penoscrotal transposition. Reports indicate that aphallia may be associated with pregnancy complicated by poorly controlled maternal diabetes [4].

Associated Anomalies

More than 50 % of patients with penile agenesis have associated genitourinary anomalies, the most common of which is cryptorchidism, renal agenesis, and dysplasia. Cardiovascular gastrointestinal defects, such as caudal axis anomalies, also have been described. Skoog and Belman [5] reviewed 60 reports of aphallia and found that the more proximal the urethral meatus, the greater the likelihood of neonatal death and the higher the incidence of other anomalies. Sixty percent of patients had a postsphincteric meatus located on a peculiar appendage at the anal verge. This group of patients had the highest survival rate (87 %) and the lowest incidence of other anomalies (1.2 per patient). Twenty-eight percent of patients had presphincteric urethral communications (prostatorectal fistula), and there was a 36 % neonatal mortality rate. Twelve percent had urethral atresia and a vesicorectal fistula for drainage. This group had the highest incidence of

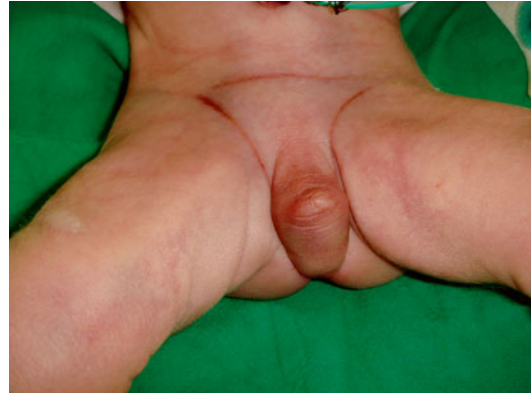

Fig. 2.4 Aphallia with absent testicles and only skin covering the urethral opening

other anomalies and an almost a 100 % mortality rate (Fig. 2.4).

Classifications

Skoog and Belman [5] suggested three variants, based on urethral position in relationship to the anal sphincter, as postsphincteric, presphincteric (prostatorectal fistula), and urethral atresia. The more proximal the bladder outlet, the greater the likelihood of other anomalies and death.

We adopted herein and after reviewing many cases and literature concerning with this issue another classification according to presence or absence of external urinary meatus and if this problem takes place with another syndrome or not:

- Aphallia with other genitourinary anomalies
- Aphallia with other syndromes
- Aphallia with absent urethra
- Aphallia with caudal regression syndrome

All reported cases of aphallia with absent external urinary meatus showed short span of life and there is no record of any survival whatever the measurers taken, and most of those cases are associated with imperforate anus and showing a degree of caudal regression (Fig. 2.5), and this could explain the association between aphallia and sirenomelia (Fig. 2.6). This classification correlated with Evans et al. who suggest that most cases can be classified into either a severe form (16 %) with renal aplasia or dysplasia and other caudal anomalies or a second group (72 %)

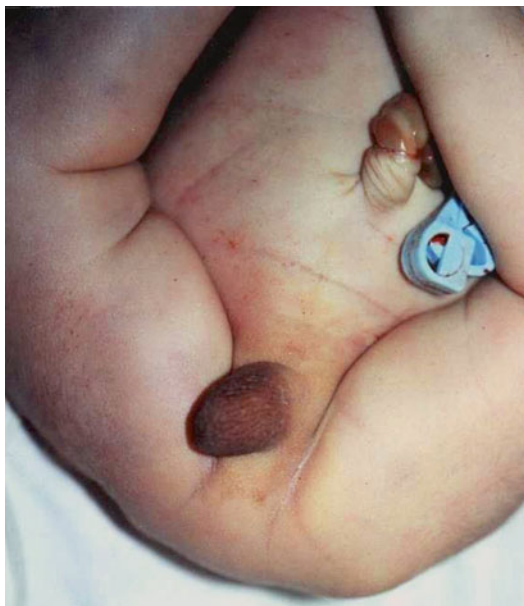

Fig. 2.5 Aphallia with partial caudal regression, no anal opening, and a hump of skin replacing the phallus

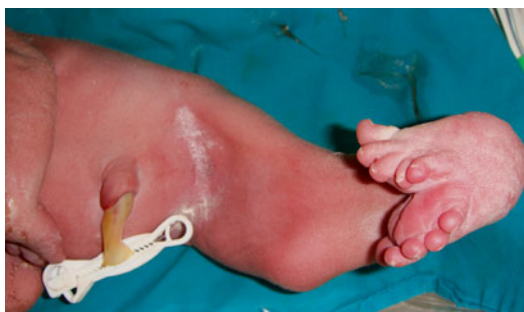

Fig. 2.6 Aphallia in association with sirenomelia

with low mortality and fewer additional malformations [6].

Diagnosis

The diagnosis of PA requires the absence of corpora cavernosa and corpus spongiosum with urethral opening at any point on the perineum in midline, over the pubis, at the anterior aspect of the scrotum, or, most frequently, just anterior to the anus and anterior wall of the rectum. This rare entity should be differentiated from concealed penis, rudimentary penis, micropenis, epispadias, hypospadias pseudohermaphroditism, and intrauterine amputation of

the penis. Anorectal anomalies such as imperforate anus, congenital rectal strictures, and rectovesical fistula, cryptorchid testis, hydrocele, hernia, renal dysplasia, horseshoe kidneys, and agenesis of the prostate could be an associated malformations [7]. When oligohydramnios or anhydramnios hinders proper diagnosis by ultrasound, MRI is an excellent technique for revealing the anatomy of genitourinary anomalies in the fetus, and many cases of aphallia could be diagnosed early in pregnancy along with other associated anomalies [8].

Management

Children with this lesion should be evaluated immediately with a karyotype and other appropriate studies to determine whether there are associated malformations of the urinary tract or other organ systems. Gender reassignment was recommended for affected newborns in the past. However, with more recent revelations that some of these patients have a male gender identity despite reconstruction as a female, the recommendation to perform gender reassignment should be made very carefully and only after full evaluation by an ambiguous genitalia assessment team that includes a pediatric urologist, endocrinologist, and psychiatrist. As a male, the patient would potentially be fertile, but currently there is an inability to construct a cosmetically acceptable phallus that would allow normal urinary, sexual, and reproductive function. The issues are similar to those under consideration in many genetic males born with cloacal exstrophy. Gender reassignment involves orchiectomy and feminizing genitoplasty in the newborn period. At a later age, construction of a neovagina is necessary. Urinary tract reconstruction with simultaneous construction of an intestinal neovagina through a posterior sagittal and abdominal approach in patients with penile agenesis has been described [9].

Infants with penile agenesis historically have undergone gender reassignment surgery, including bilateral orchiectomy with preservation of the scrotal skin for later vaginal reconstruction, labial construction, and urethral transposition [10]. However, questions remain regarding in utero gender imprinting and the long-term psychological effects of gender conversion, and increasing controversy

surrounds the timing, role, and the necessity of gender reassignment. The long-accepted notion regarding the presence of a phallus or phenotypic phallic growth potential should not be the major criterion in recommending gender reassignment.

2.3 Microphallus

Nomenclature

Micropenis

Definition

The term microphallus, or micropenis, is applicable only to a normally formed yet abnormally short penis. The term specifically applies to a penis with a stretched length more than 2.5 standard deviations (SD) less than the mean for age (Table 2.1). In general, the penis of a full-term neonate should be at least 1.9 cm long. One must differentiate buried penis or webbed penis from the micropenis, with the former having a normal penile shaft. Measurement (stretched penile length) is very important in differentiation of the various types of pseudomicropenis, particularly the buried penis in the obese infant and the penis concealed by an abnormal skin attachment or excessive suprapubic fat which is commonly referred to as an inconspicuous penis.

This condition may be considered a minor form of ambiguous genitalia with correlated med-

ical and psychological problems similar to those of the major intersex form. The scrotum usually is normal (Fig. 2.7), but sometimes the testes are small or undescended, or the scrotum may migrate cephalically engulfing the small phallus as a minimal scrotal transposition (Fig. 2.8). In a few cases, the corpora cavernosa are severely hypoplastic, and it is not rare to have microphallus with severe hypospadias and deficient corpus spongiosum (Fig. 2.9).

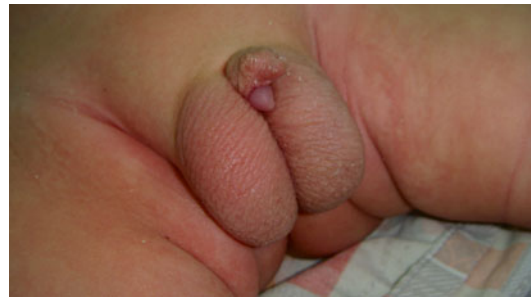

Fig. 2.7 Microphallus with normal testicles



Fig. 2.8 Microphallus with scrotal transposition

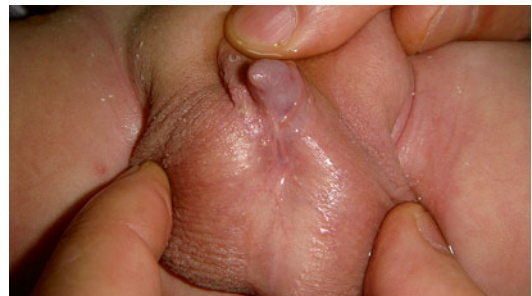

Fig. 2.9 Microphallus with corpus spongiosum deficiency and hypospadias

Table 2.1 Normal penile size [11]

Age	Mean±SD	Mean-SD
Newborn 30-week gestation	2.5±0.4	1.5
Newborn 34-week gestation	3±0.4	2.0
0–5 months	3.9±0.8	1.9
6–12 months	4.3±0.8	2.3
1–2 years	4.7±0.8	2.6
2–3 years	5.1±0.9	2.9
3–4 years	5.5±0.9	3.3
4–5 years	5.7±0.9	3.5
5–6 years	6±0.9	3.8
6–7 years	6.1±0.9	3.9
7–8 years	6.2±1.0	3.7
8–9 years	6.3±1.0	3.8
9–10 years	6.3±1.0	3.8
10–11 years	6.4±1.1	3.7
Adult	13.3±1.6	9.3

Historical Note

Perceptions of penile size are culture specific, so in ancient Greece and in Renaissance art, an uncircumcised and small penis was culturally seen as desirable in a man, whereas a bigger or circumcised penis was viewed as comical or grotesque. Ancient Rome may have had a contrary view, and a larger penile size was preferred in medieval Arabic literature.

Incidence

The condition is thought to affect 1 in 200 males that are born. According to the Network on Psychosexual Differentiation, incidence for a micropenis is below 2 %. In Colombia, the incidence is 19:100,000 people, while the incidence for hypospadias in the same study, a factor of 10 higher [12].

The observed significant increase in recent years of such cases in neonates by some authors is probably due to the influence of exogenous substances, such as antiandrogens, estrogen, and chemical compounds that bind to the androgen receptors [13].

Etiology

Micropenis results from a multiplicity of endocrine and nonendocrine conditions. The most common etiologies include hypogonadotropic hypogonadism, hypergonadotropic hypogonadism, and idiopathic micropenis [14].

- In hypogonadotropic hypogonadism, secretion of gonadotropin-releasing hormone (GnRH) by the hypothalamus is impaired. This leads to decreased pituitary secretion of luteinizing hormone and follicle-stimulating hormone, depriving the testis of its stimulus to secrete testosterone. This pathogenesis exists in some hypothalamic dysfunctions, such as Kallmann syndrome or Prader–Willi syndrome.
- Micropenis secondary to hypergonadotropic hypogonadism is associated with conditions in which the testes are impaired functionally and unable to respond to hypothalamic–pituitary stimulation; an example of this condition is gonadal dysgenesis.
- In so-called idiopathic micropenis, endocrine analysis demonstrates a normal hypothalamic–

pituitary–testicular axis, but some recognized causes could be implicated:

- Primary testicular failure, e.g., anorchia, partial gonadal dysgenesis, and Klinefelter's syndrome
- Hypogonadotropic hypogonadism, Kallmann syndrome, and CHARGE syndrome
- Defects in testosterone action, partial androgen insensitivity, and 5 α -reductase deficiency
- Developmental anomalies, aphallia, and cloacal exstrophy [15]

Differential Diagnosis

Congenital micropenis should be differentiated from:

- Inconspicuous penis, which refers to a penis that appears to be small with a normal stretched penile length measured from the pubic symphysis to the tip of the glans and normal diameter of the penile shaft.
- Buried penis, also referred to as hidden or concealed penis, is a form of inconspicuous penis. A buried penis is a normally a developed penis that is hidden away by the suprapubic fat pad.
- Webbed penis

Management

Topical application of 5 % testosterone cream causes increased penile growth. The objective is to provide sufficient testosterone to stimulate penile growth without altering growth and closure of the epiphyses. Therapy should be started by age 1 year and aimed at maintaining genital growth commensurate with general body growth. Hormonal stimulation, especially with dihydrotestosterone, may produce some penile growth even after puberty. This can be given in a 2.5 % gel formulation once per day, with review after 6–8 weeks to assess the effect. The most common therapeutic regimen for injectable testosterone is testosterone enanthate 25–50 mg intramuscularly once a month for 3 months [16].

Patients with micropenis who also suffer from penile dysmorphic disorder require careful and intensive psychological counseling. Corrective surgery for micropenis can be performed in patients with

realistic expectations. Total phalloplasty using radial artery-based forearm skin flaps can offer restoration of normal penile length in selected patients. More conservative surgical techniques to improve length or girth are limited by minimal enhancement but associated with a significantly lower rate of complications and comorbidity compared to total phalloplasty. Emerging tissue engineering techniques might represent a suitable alternative to penile replacement surgery in the future [17].

Because micropenis is the result of numerous pathological conditions, assignment of sex of rearing generally is deferred until a physician determines whether the penis can grow in response to testosterone administration or not. In individuals with micropenis who are insensitive to the androgen, castration and gender conversion can be considered. However, in most patients with micropenis, male gender assessment can be maintained with androgen stimulation [18].

2.4 Megalopenis

Definition

Abnormal largeness of the penis is an anomaly whereby the phallus enlarges rapidly in childhood due to high level of production of testosterone, e.g., interstitial cell tumors of the testicle, hyperplasia or tumors of the adrenal cortex, or secondary to other congenital anomalies.

Nomenclature

Megalopenis, macrophallus, and macropenis

Etiology

Hypothalamic tumor associated with precocious puberty may be the cause of macrophallus. Benign familial infantile seizures with inversion of chromosome 15 are reported to be associated with macrophallus, and also some cases are reported with heterochrony development where deletion of chromosomal region 13q21q31 is associated with macropenis [19].

Femoral hypoplasia–unusual facies syndrome (FHUFS) which is characterized by bilateral, mostly asymmetrical, femoral hypoplasia with

variable lower limb shortening and nonspecific facial dysmorphism is commonly associated with megalopenis [20].

Macropenis is an uncommon finding of Fraser syndrome, which is characterized by cryptophthalmos, cutaneous syndactyly, malformations of the larynx and genitourinary tract, craniofacial dysmorphism, orofacial clefting, mental retardation, and musculoskeletal anomalies. The inheritance is autosomal recessive. No diagnostic cytogenetic abnormalities have been documented in affected patients, and no molecular genetic studies have been reported.

Isolated cases of macropenis in a normal baby and without any associated anomalies are extremely rare (Fig. 2.10), but macropenis could be noticed in other congenital penile or urethral anomalies which will be discussed later on like congenital megalourethra (Fig. 2.11) and congenital penile lymphedema (Fig. 2.12); in those

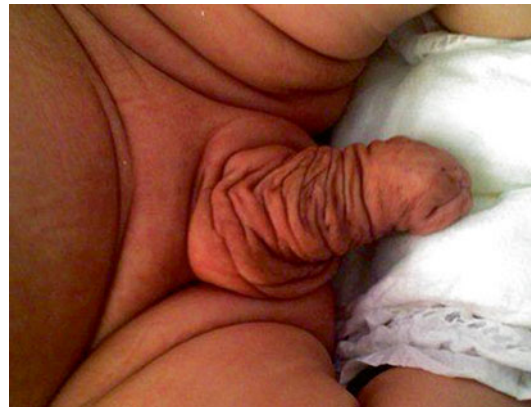

Fig. 2.10 Isolated megalopenis

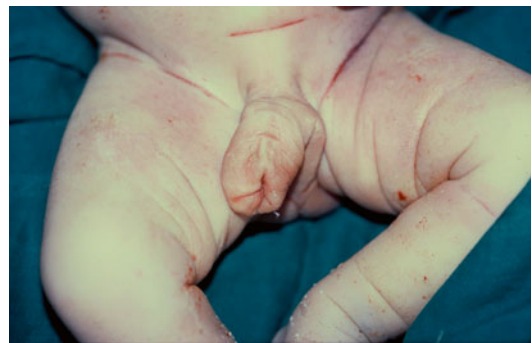

Fig. 2.11 Megalopenis in congenital megalourethra

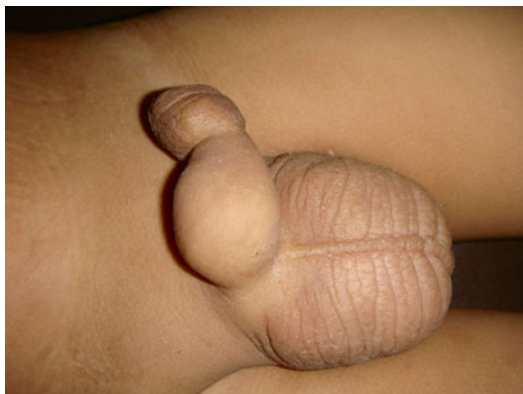

Fig. 2.12 Megalopenis in congenital lymphedema

conditions the penile gigantism is not a true one. Megalopenis should be also differentiated from megaprepuce or macroposthia which also will be discussed in Chap. 3.

2.5 Penile Duplication (PD)

Definition

Duplication of the penis, or diphallia, is a rare anomaly resulting from incomplete fusion of the genital tubercle. It is an extremely rare but well-documented anomaly.

Nomenclature

Diphallia, penile duplication, diphallic terata, or diphallasparatus

Incidence

It is estimated to occur in one out of five million live births. It is usually accompanied by other congenital anomalies such as renal, vertebral, hindgut, or anorectal duplication; also there is a higher risk of spina bifida.

Historical Background

The first reported case of PD was reported by Johannes Jacob Wecker in 1609 [21]. Penile duplication is a normal finding in some animal species, male snakes and lizards, each possessing a pair of penis-like organs.

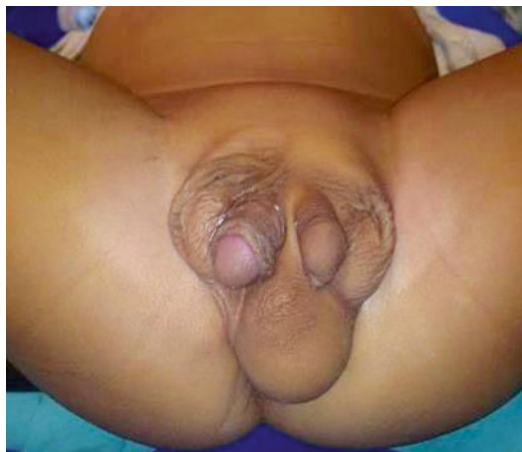

Fig. 2.13 Complete diphallia with two urethral openings and two scrotums

Definition

Duplication of the penis is a rare anomaly and has a range of appearances from a small accessory penis to complete duplication. In some cases, each phallus has only one corporal body and urethra, whereas others seem to be a variant of twinning, with each phallus having two corpora cavernosa and a urethra (Fig. 2.13). The penises usually are unequal in size and lie side by side, but very rarely the other moiety lies beneath the first one in a sagittal plane (Fig. 2.14).

Associated anomalies are common, including hypospadias, bifid scrotum, and duplication of the bladder, renal agenesis or ectopia, and diastasis of the pubic symphysis. Anal and cardiac anomalies also are common (Fig. 2.15). Evaluation should include imaging of the entire urinary tract. Sonography has been reported to aid in assessment of the extent of phallic development [22]. MRI can also be used to assess penile development. MRI is a valuable method for achieving the accurate diagnosis of these anomalies and associated malformations. It also provides the appropriate knowledge regarding anatomical detail and assists the surgeon in decision making and preoperative planning for the optimal surgical approach [22].

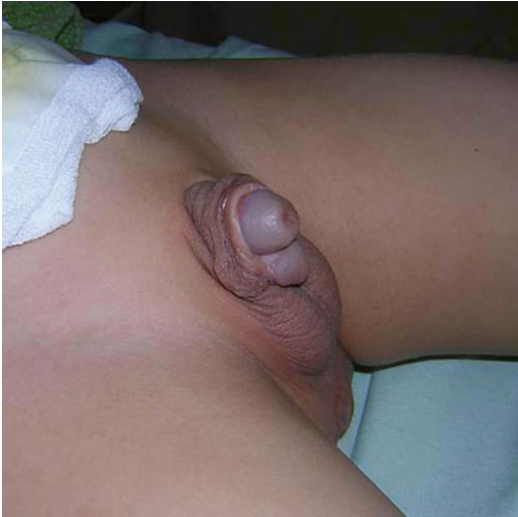

Fig. 2.14 Diphallia in a sagittal plane

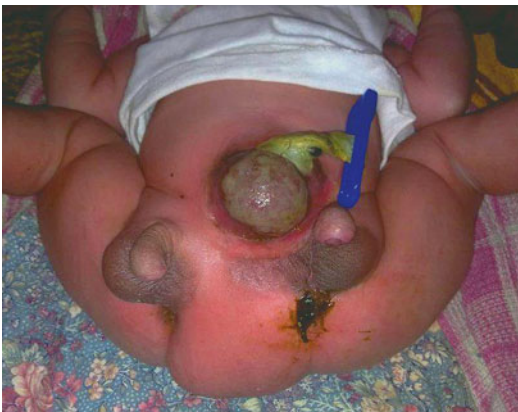

Fig. 2.15 Complete diphallia with two phalli and two anal openings and exomphalos

Etiology

Hollowell et al. [23] reviewed the embryogenesis of diphallia and suggested that complete diphallus could result from longitudinal duplication of the infraumbilical cloacal membrane before the fourth week of gestation, the subsequent mesodermal migration allowing two separate, complete sets of genital tubercle, genital folds, and genital swellings to develop. The fusion of the genital folds and swellings may not, however, be entirely normal, accounting for the finding that one of the two

urethras may be a blind pit or else be stenotic. One or both urethras also may be hypospadiac or epispadiac. A wide range of scrotal abnormalities may be present. Because the duplicated cloacal membrane is likely to be a widened structure, the “wedge” effect could result in the stigmata of covered exstrophy. In some patients, the abnormalities suggest a form of partial caudal duplication with extensive midline defects or duplication involving the derivatives of the allantois, hindgut, and neural tube [24].

It is thought that diphallia occurs in the fetus between the 23rd and 25th days of gestation when an injury, chemical stress, or malfunctioning homeobox genes hamper proper function of the caudal cell mass of the fetal mesoderm as the urogenital sinus separates from the genital tubercle and rectum to form the penis.

Classification

Two distinct forms of penile duplication exist:

- The most common form is associated with bladder exstrophy complex. The patient exhibits a bifid penis, which consists of two separated corpora cavernosa that are associated with two independent hemiglans.
- The second form, or true diphallia, is an extremely rare congenital condition. It presents in many ways, ranging from duplication of the glans alone to duplication of the entire lower genitourinary tract.

The urethral opening can be in normal position or in a hypospadiac or epispadiac position. Associated anomalies of the GI, genitourinary, and musculoskeletal systems are expected. Because these anomalies are the principal causes of mortality, examining and treating patients for these conditions as soon as possible is important.

According to Schneider [24], diphallia can be divided into four categories:

1. Duplication of the glans alone
2. Bifid diphallia
3. Complete diphallia with each penis having two corpora cavernosa and a corpus spongiosum
4. Pseudodiphallia in which there is a rudimentary atrophic penis existing independently of the normal penis

Treatment

Treatment must be individualized with consideration of the associated anomalies with the goal of attaining a satisfactory functional and cosmetic result.

2.6 Penile Deviation

Nomenclature

Penile torsion, penile diversion, penile curvature

Definition

Penile torsion is a rotational defect of the penile shaft. Almost always the shaft is rotated in a counterclockwise direction (i.e., to the left side) (Fig. 2.16); right-sided rotation is a rare entity (Fig. 2.17). In most cases, penile size is normal and the condition is unrecognized until circumcision is performed or until the foreskin is retracted. Penile torsion may also be associated with hypospadias or a dorsal hood deformity without a urethral abnormality. In most cases of penile torsion, the median raphe spirals obliquely around the shaft (Fig. 2.18).

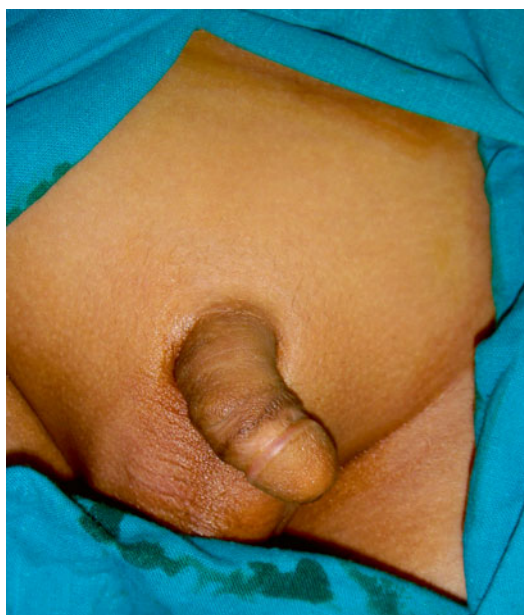

Fig. 2.16 Left-sided penile rotation

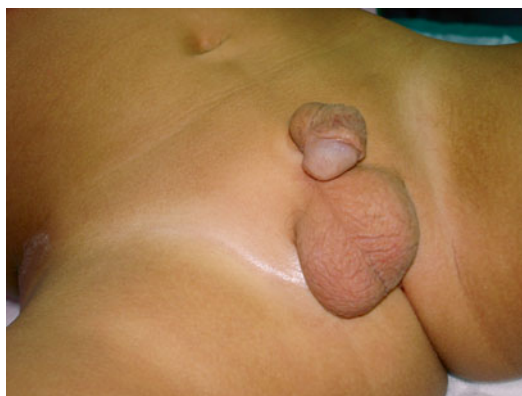

Fig. 2.17 Right-sided rotation



Fig. 2.18 Median raphe spirals obliquely around the shaft

Historical Background

Verneuil described penile torsion in 1857 [25]. In the past, physicians did not recommend operative correction because they believed that attempts to move the skin would not correct spiral alignment of the corpora cavernosa.

Classifications

Generally, curvature of the penis may occur along the vertical (i.e., ventral or dorsal direction) or horizontal (i.e., lateral direction) plane of the penis:

- Lateral penile curvature, either right or left
- Dorsal or ventral penile deviation

Etiology

Congenital curvature is rare, and there is no evident cause; lateral penile curvature usually is caused by overgrowth or hypoplasia of one

corporal body. A single study analyzing the ultrastructure of the tunica albuginea demonstrated widening and fragmentation of collagen fibers, with complete disappearance of striation and transformation into electron-dense, fibrous, granulated material and elastin accumulation. Although the glans may be directed more than 90° from the midline, the orientation of the corporal bodies and the corpus spongiosum at the base of the penis is normal. Hemihypertrophy of a corpus cavernosum and its accompanying thickened tunica albuginea, with or without contralateral concomitant hypoplasia (rudimentary corpus), is responsible for the lateral deviation in congenital curvature of the penis. Rarely, penile deviation is accompanied by penile torsion. Although the deformity generally is not severe enough to preclude sexual intercourse, it can be a source of great concern to the patient and may cause him to avoid sexual contact, and in the younger age the baby and the family may be troubled by the abnormal urinary stream instigated by deviation (Fig. 2.19).

One-hundred-and-eighty-degree malrotation of the penis is a common finding in Fraser syndrome [26].

Management

In general, the defect has primarily cosmetic significance, and correction is unnecessary if it is

less than $60\text{--}90^\circ$ from the midline. In the milder forms, the penile skin may be degloved and simply reoriented so that the median raphe is restored to its normal position. However, in boys with penile torsion of 90° or more, simply rearranging the skin on the shaft of the penis is not sufficient. In these more severe forms of the disorder, the base of the penis must be mobilized so that dysgenic bands of tissue can be identified and incised. If the penis still remains rotated, correction may be accomplished by placing a nonabsorbable suture through the lateral aspect of the base of the corpora cavernosa on the side opposite the direction of the abnormal rotation (i.e., on the right corporal body) and fixing it to the pubic symphysis dorsal to the penile shaft [26].

The intraoperative technique of artificial erection using a normal saline solution is critical to the procedure's success. An alternative is to inject alprostadil, $14\text{ }\mu\text{g}$, into the corpora intraoperatively while manually compressing the corporal base. This technique allows tumescence throughout the penile repair. Detumescence is induced by infiltrating the corporal bodies with phenylephrine, $40\text{ }\mu\text{g}$. During correction, one must be careful to avoid injury to the neurovascular bundles [26, 27]. Repair of dorsal penile deviation is performed by excising ellipses from the ventral corporal bodies.

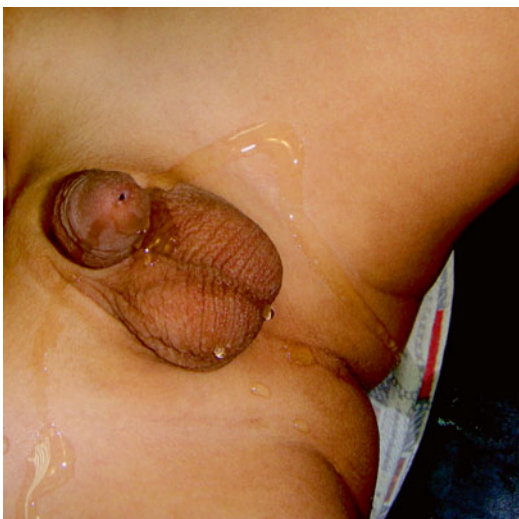

Fig. 2.19 Abnormally deviated urinary stream

2.7 Penile Chordee

Congenital chordee is caused by reduced elasticity in one or more of the fascial layers of the penis, leading to shortness of the corpus spongiosum when erection occurs. The bend is usually ventral but could be dorsal or complex.

Nomenclature

The term “chordee” was introduced into medical literature in the seventeenth century from the French in relation to gonorrhea. Most hypospadias pioneers in the nineteenth century used terms such as incurvation, curvature, or bending. Clinton Smith, in the 1930s, was probably the first to use the term chordee to describe congenital curvature associated with hypospadias [28].

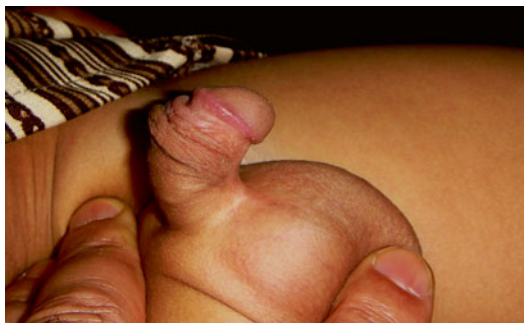

Fig. 2.20 Penile chordae with ventral bending not associated with any other urethral anomaly

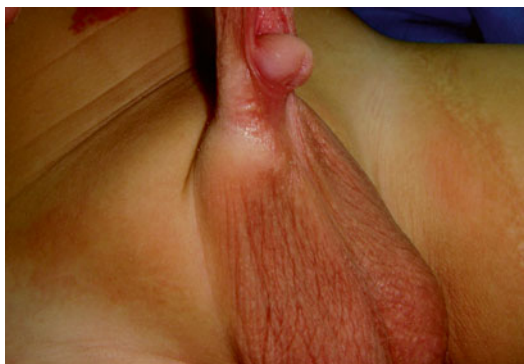

Fig. 2.21 Ventral curvature associated with hypospadias

Etiology

Chordee may occur alone (Fig. 2.20), but it is often found in association with various other congenital penile anomalies such as hypospadias (Fig. 2.21) or with deficient corpus spongiosum, where the urethra could be seen superficial under the skin (Fig. 2.22). The exact cause of chordee is unclear, but when it is associated with hypospadias, the presence of fibrous bands may explain its existence, where the mesenchyme distal to the meatus ceases to differentiate, creating a fan-shaped band of dysgenetic fascia; however, when found independently from other conditions, chordee is postulated to result from fibrotic superficial and deep penile fascia, skin tethering, or corporal disproportion. If untreated, congenital penile curvature may prohibit or significantly interfere with sexual intercourse. Acquired chordee may result from trauma or Peyronie's disease [29].



Fig. 2.22 Ventral penile curvature with deficient corpus spongiosum and superficial urethra

Management

Ventral curvature in boys without hypospadias can generally be corrected by degloving of the penis, excision of fibrous tissue that is usually confined to the region superficial to Buck's fascia, and development of a Byars flap for penile skin coverage as necessary. In more severe cases, simple dorsal plication, Nesbit dorsal excision, or corporeal rotation may be essential. In the most severe cases, the urethra is short, and urethral reconstruction, for example, an interposition island flap of the dorsal foreskin, must be performed. Intraoperative artificial erection with injectable normal saline may be necessary to confirm that complete chordee correction has been performed. Some cases of chordee may be aggravated by a prominent frenulum, resulting in distal penile chordee with ventral glanular deflection. In these cases, frenulotomy will improve and may correct the chordee.

2.8 Webbed Penis

Nomenclature

Penoscrotal fusion, buried penis, penis palmatus, penoscrotal pterygium

Incidence

There is no accurate figure about the exact incidence of webbed penis, but Rudin and Osipova presented the largest series on webbed penis;

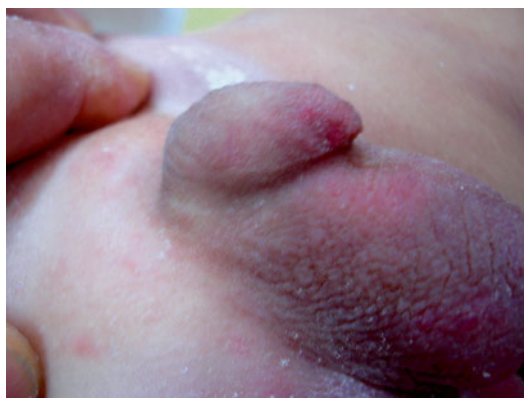

Fig. 2.23 Webbed penis in a neonate



Fig. 2.24 Webbed penis as a variant of penoscrotal transposition

they described 30 boys with webbed penis along with their clinical symptoms and anatomical and morphological features underlying the development of this entity [30].

Definition

Webbed penis is a congenital condition resulting from the scrotal skin extending onto the ventrum of the penis (Fig. 2.23); this condition represents an abnormality of the normal topographic relation between the penis and the scrotum and could be considered as a spectrum of penoscrotal transposition, whereas the penis loses the normal orientation with obscured penoscrotal angle (Fig. 2.24). Usually the penis, the urethra, and the remainder of the scrotum typically are normal (Fig. 2.25).

Differential Diagnosis

This condition should be differentiated from hidden penis which is an acquired condition where

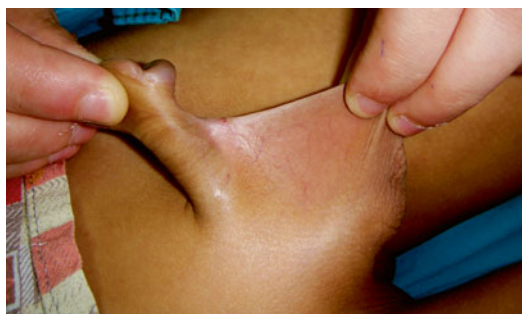

Fig. 2.25 Normal penile size, scrotum, and urethra in webbed penis

the penile shaft is buried below the surface of the prepubic skin. This happens in children with obesity because the prepubic fat is very abundant and hides the penis. The condition also may derive from poor anchorage of the penile skin to deep fascia or be acquired when the shaft of the penis is entrapped in scarred prepubic skin following an extreme circumcision or other trauma [31].

Management

If the physician performing circumcision does not recognize the condition, the penis may become buried in a tentlike fold of skin. Recircumcision to remove the excess skin makes the situation worse by drawing hair-bearing scrotal skin onto the penis. There are several surgical techniques that can be implemented to correct this condition; one technique involves the fixation of the subcutaneous tissue of the scrotum to the ventral aspect of the base of the penile shaft with nonabsorbable suture. On occasion, this condition may be corrected by incision of the web transversely, separation of the penis from the scrotum, and closure of the skin vertically. In other cases, a circumferential incision is made 1.5 cm proximal to the coronal sulcus, a Byars preputial skin flap is transferred to the ventral surface of the penis, and the redundant foreskin is excised. In rare cases the distal urethra is hypoplastic, necessitating urethral reconstruction. The literature describes numerous techniques for correction. Usually, treatment is based on resection of adherent bands and deep anchorage of the shaft at the basis of the penis. Some also advocate excision of redundant skin,

multiple Z-plasties, liposuction, or preputial island pedicle flap [32].

2.9 Penoscrotal Transposition (PST)

History

Penoscrotal transposition was first reported by Appleby in 1923 [33]. McIlvoy and Harris in 1955 reported the first performed surgery to move the penis into a more cranial position through a subcutaneous tunnel beneath the prepenile scrotum [34].

Nomenclature

Scrotal engulfment, shawl scrotum, prepenile scrotum, daughter scrotum

Incidence

There is no figure about the incidence of PST; complete cases are stated usually as a case report, but I believe minor cases are underestimated.

Definition

Complete penoscrotal transposition is an uncommon condition in which the scrotum is located in a cephalic position with respect to the penis [35] (Fig. 2.26). A less severe form is a bifid scrotum, in which the two halves of the scrotum meet above the penis. It is a heterogeneous anomaly, and detection warrants careful clinical evaluation to rule out other major and life-threatening anomalies, especially of the urinary system.

Etiology

Although most reported cases are sporadic, some suggest a genetic basis for normal penoscrotal relationship. The embryological sequence responsible for this defect remains unclear. Abnormal positioning of the genital tubercle in relation to the scrotal swellings during the critical fourth to fifth week of gestation may affect the inferomedial migration and fusion of the scrotal swellings. If the phallic tubercle also is intrinsically abnormal, development of the corporal bodies and the urethral groove and folds may be

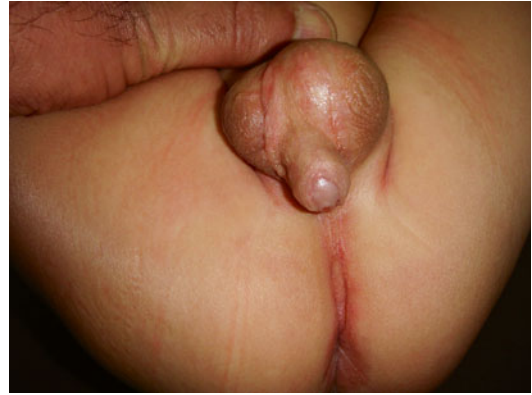

Fig. 2.26 Complete penoscrotal transposition

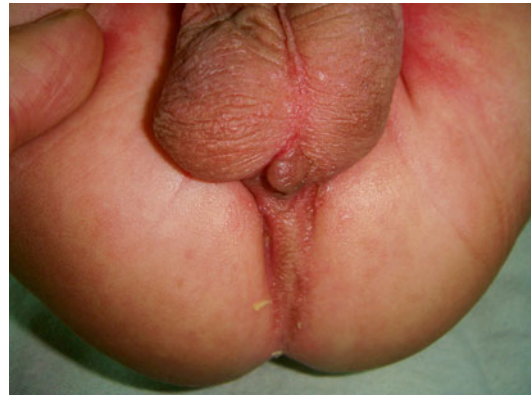

Fig. 2.27 Major incomplete PST with hypospadias

affected; this explains the frequent occurrence of the other genital abnormalities (Fig. 2.27).

At the fourth week of gestation, a genital swelling normally appears at both sides of the inguinal region and gradually forms the labioscrotal swelling at 10–12 weeks of gestation. These swellings migrate to the caudal portions and merge beneath the penis, which remains as the scrotal raphe, the line of fusion. Lamm and Kaplan [36] suggested that scrotal anomalies result from early division and/or abnormal migration of the labioscrotal swelling. Unilateral failure or abnormal migration might result in unilateral penoscrotal transposition or ectopic scrotum, and early division of a labioscrotal swelling with subsequent abnormal migration might result in an accessory scrotum. Takayasu et al. [37] proposed that a teratoid growth of the divided pleuripotential anlage, of

the labioscrotal swelling, is responsible for the accessory scrotum. Perineal lipomas have been described as an associated condition; however, they are very commonly associated with the accessory scrotum in up to 83 % of cases. Sule et al. hypothesized that the accessory labioscrotal fold develops because a perineal lipoma, in the perineum, disrupts the continuity of the developing caudal labioscrotal swelling [38].

Classification

Glenn and Anderson have classified the abnormality into the following categories, according to severity: bifid scrotum, incomplete or partial penoscrotal transposition, complete penoscrotal transposition or prepenile scrotum, and ectopic scrotum [39].

After reviewing of 63 cases, we adopted another classification, taking into consideration the minor cases and whether it is unilateral or bilateral, and a new category of reverse migration of the scrotum away from the penis—caudally it was given the name caudal scrotal migration:

- Major
 - Complete (Fig. 2.26)
 - Incomplete (Fig. 2.27)
- Minor
 - Unilateral (asymmetrical) (Fig. 2.28)
 - Bilateral (symmetrical)
 - Central median penile scrotalization (Fig. 2.29)
- Caudal scrotal regression (wide penoscrotal distance) (Fig. 2.30)

Associated Anomalies

PST is a rare heterogeneous anomaly, the detection of which should warrant careful clinical evaluation to rule out other anomalies, especially of the urinary system, gastrointestinal tract, upper limbs, craniofacial region, and central nervous system. PST may be a localized field defect involving the genitourinary system with major renal anomalies which include complete agenesis of the urinary system, unilateral or bilateral renal agenesis, polycystic or dysplastic kidneys, horseshoe kidney, ectopic pelvic kidney, and obstructive uropathy. Genital abnormalities include a disproportionately long flaccid penis, complete urethral atresia, and hypospadias.

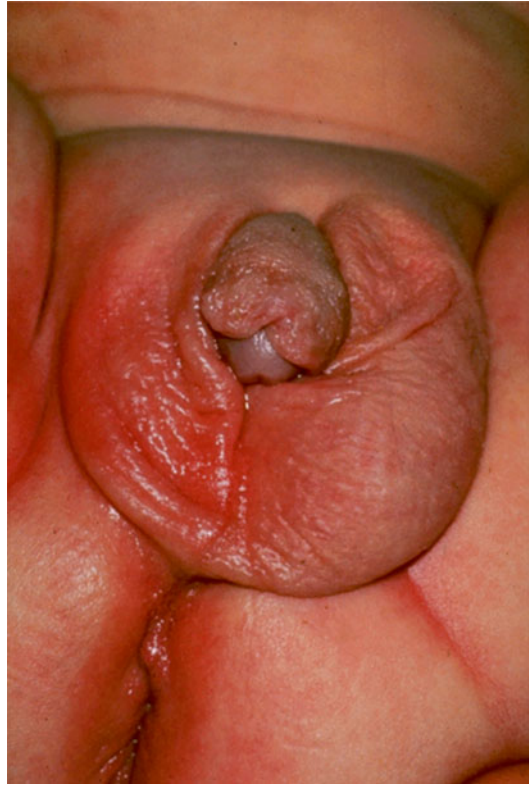

Fig. 2.28 Minor unilateral PST

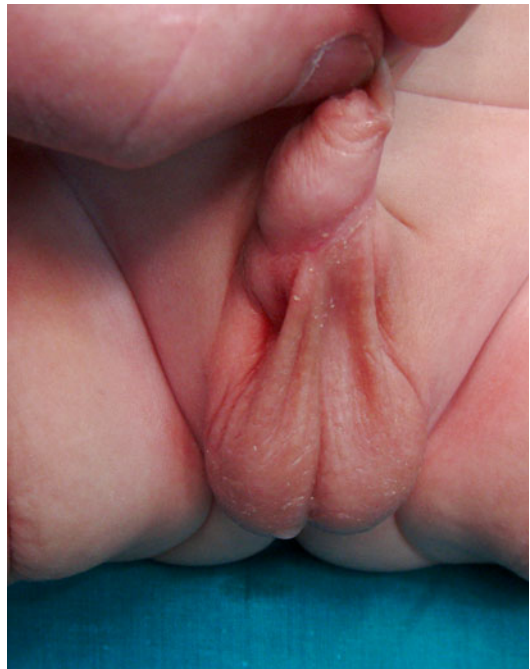

Fig. 2.29 Central penile scrotalization

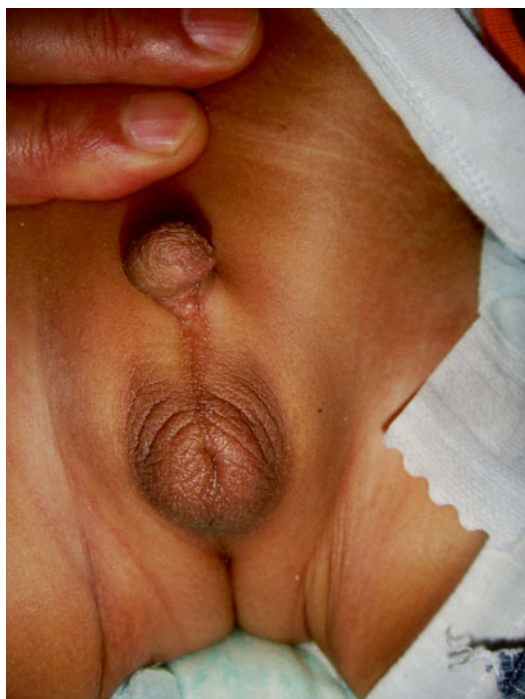

Fig. 2.30 Wide penoscrotal distance (caudal scrotal regression)

Management

Surgical correction is recommended for physiological and psychological reasons. When associated with severe hypospadias, penoscrotal transposition may involve a staged surgical repair. Scrotoplasty is completed with an inverted omega skin incision that is made around the scrotal skin and the base of the penis, bringing the scrotal flaps beneath the penis. Forshall and Rickham [40] used a different technique in two patients in whom the cranially located scrotal flaps were elevated, rotated medially and caudally, and sutured beneath the penis; this method was also used by Glenn and Anderson [39].

2.10 Genital Median Raphe Anomalies (GMR)

Definition

Raphe means the line of union of the two halves of various symmetrical parts, and the term median raphe refers to the perineal raphe, which is also known as the median raphe of the perineum. This

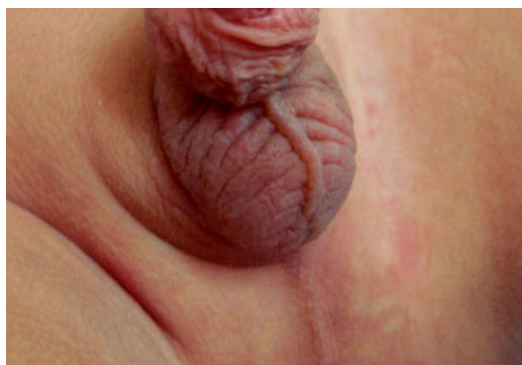

Fig. 2.31 Prominent median raphe

line starts just anterior to the anus and extends through the scrotum, continuing on the ventral surface of the penis; it is usually darker in color than the surrounding skin, generally deep pink or brown. GMR is a result of a fetal developmental phenomenon whereby the scrotum (the developmental equivalent of the labia in females) and penis close toward the midline and fuse, and this could explain the incidence of other genitourinary anomalies, mainly hypospadias.

Incidence

Median raphe anomalies are not so common and rarely taken into consideration by the physicians and could pass unnoticed; the overall incidence is about 2 %, with a wide spectrum ranging from simple anomaly like prominent raphe to a raphe cyst [41].

Prominent Median Raphe

Normally GMR identified by its prominence than the rest of the skin around it, but abnormal prominent raphe looks like a ridge which was detected in other anomalies like hypospadias and imperforate anus, in several cases of Townes–Brocks syndrome (an autosomal dominant disorder with multiple malformations and variable expression, major findings include external ear anomalies, hearing loss, preaxial polydactyly and triphalangeal thumbs, imperforate anus, and renal malformations), it was noted that there was a very prominent midline perineal raphe extending from the site of the anal orifice to the scrotum [42] (Fig. 2.31).

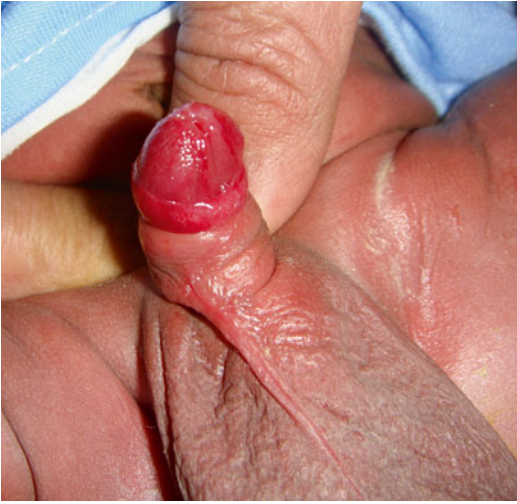

Fig. 2.32 Short contracted median raphe

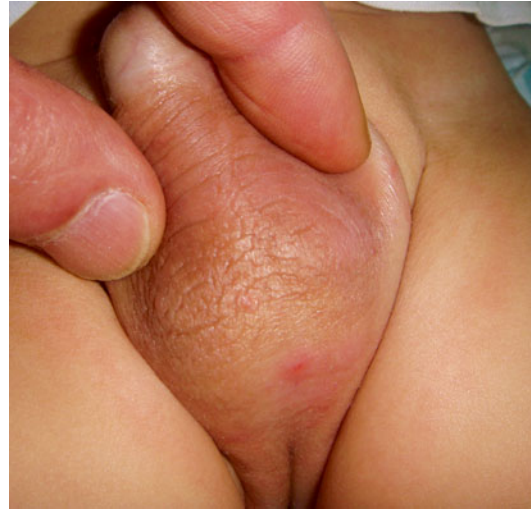

Fig. 2.34 Absent median raphe

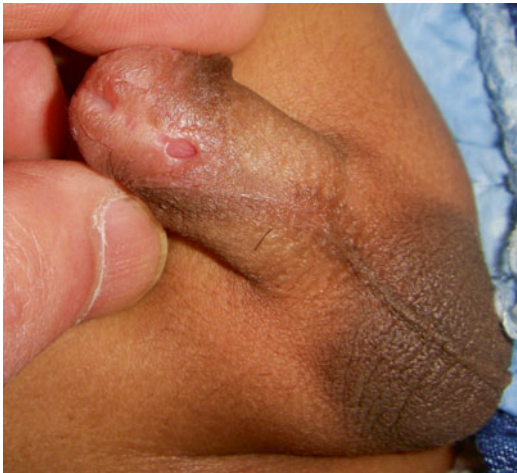

Fig. 2.33 Deviated median raphe with hypospadias

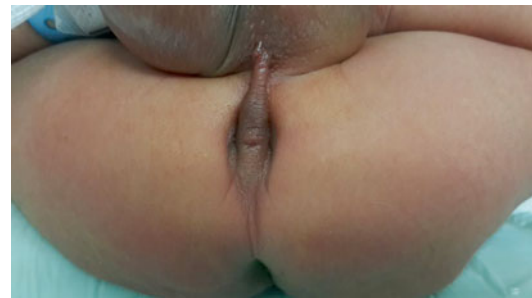

Fig. 2.35 Bucket handle anomaly

Short Contracted Raphe

Short contracted raphe may be associated with webbed penis with deficient ventral skin that necessitated postponing routine circumcision and subsequent penile reconstruction with either removal of preputial skin from the dorsal than the ventral aspect or rotation skin flap (Fig. 2.32).

Deviation of raphe to one side or its bifurcation could hide different grades of associated hypospadias; 32 % of these cases of deviated or bifurcated raphe had hypospadias [41] (Fig. 2.33).

Absent median raphe is a very rare anomaly known to be associated with transverse testicular ectopia [43], but it could be detected either partially or completely in baby with hypospadias (Fig. 2.34).

A bucket handle malformation is a clinical feature seen in perineal fistula as a prominent midline skin bridge or a subepithelial midline raphe fistula that looks like a black ribbon because it is full of meconium. These features are externally visible and help diagnose a perineal fistula [44] (Fig. 2.35).

The split of median raphe was probably due to the defective fusion of the ectoderm; failure of closure occurs because of the failure of maturation of the midline mesodermal components, and it may be presented as a prominent widely separated median raphe (Fig. 2.36),

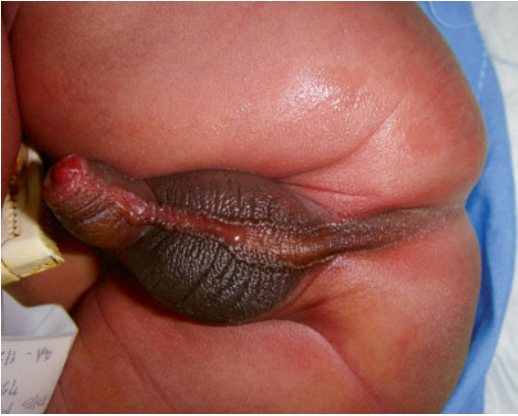

Fig. 2.36 Widely separated median raphe

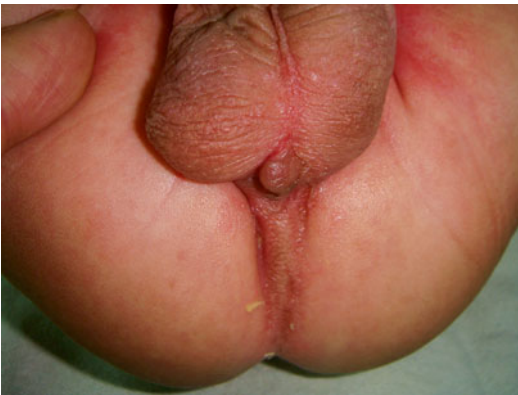

Fig. 2.37 Median raphe cyst

median raphe cyst (Fig. 2.37), beaded median raphe (Fig. 2.38), or pearly penile papules (Fig. 2.39) [41].

2.11 Penile Lymphedema

Nomenclature

Saxophone penis, genital lymphedema, penile elephantiasis

Definition

Penile lymphedema (Fig. 2.40) is an uncomfortable and potentially disfiguring disorder. It may be congenitally inherited (15 %), in either an autosomal dominant form (Milroy's disease), a sporadic form (in 85 % of the cases) that occurs at puberty (Meigs' disease), or

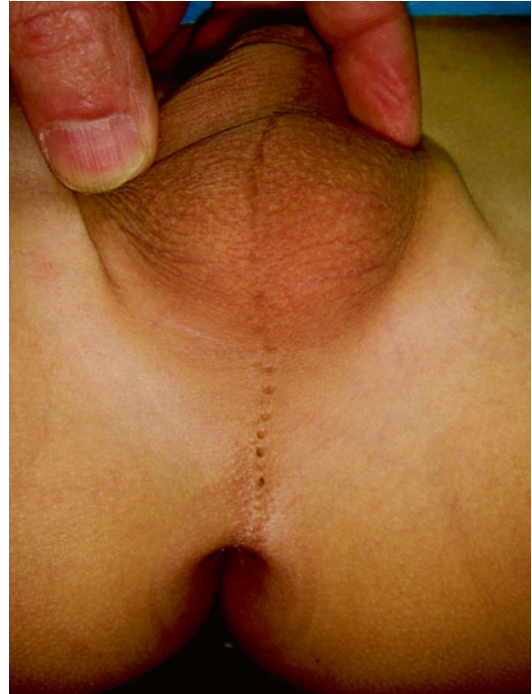

Fig. 2.38 Beaded median raphe

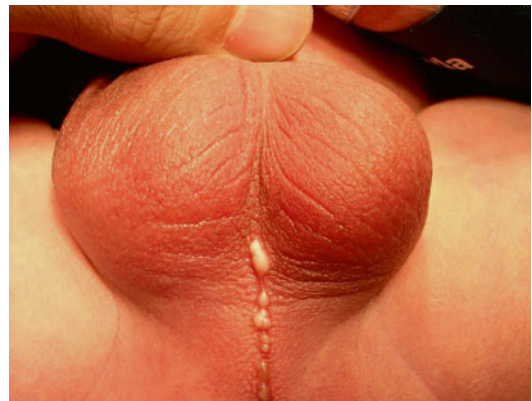

Fig. 2.39 Pearly penile papules in the median raphe

usually caused by acquired infection, e.g., lymphogranuloma venereum or filarial infestation, with *Wuchereria bancrofti*. Scrotal elephantiasis (Fig. 2.41) is extremely rare outside endemic regions in Africa and India [45]. Lymphedema of the genitalia is characterized by impaired lymphatic drainage caused by obstruction, aplasia, or hypoplasia of lymphatic vessels that causes progressive penile and/or scrotal swelling.

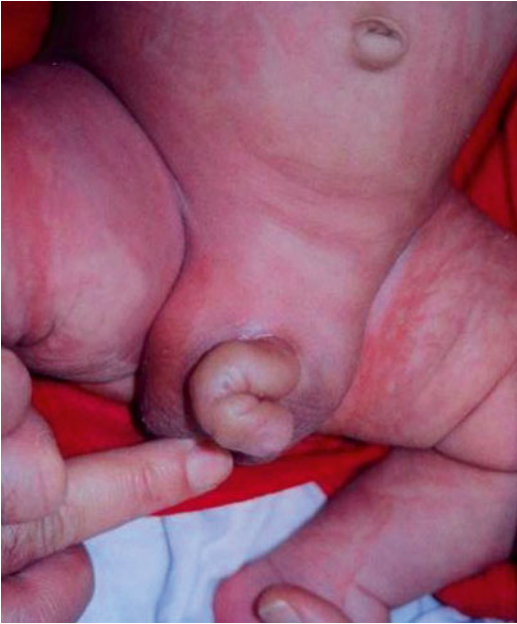

Fig. 2.40 Penile lymphedema

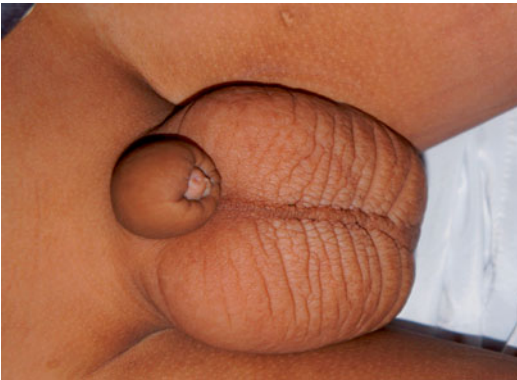

Fig. 2.41 Scrotal lymphedema

Management

Initial management involves observation. If lymphedema remains significant or progresses, then surgical therapy is necessary. The goal of surgical treatment is to remove all involved tissue. On the penile shaft, the penis is degloved and all tissue between Buck's fascia and the skin must be excised, as well as redundant penile skin. If the scrotum is involved, all scrotal tissue, with the exception of the skin, testes, and spermatic cords, must be removed. Usually most of the scrotal skin must be excised, with the exception of the posterior skin. The penis may be covered

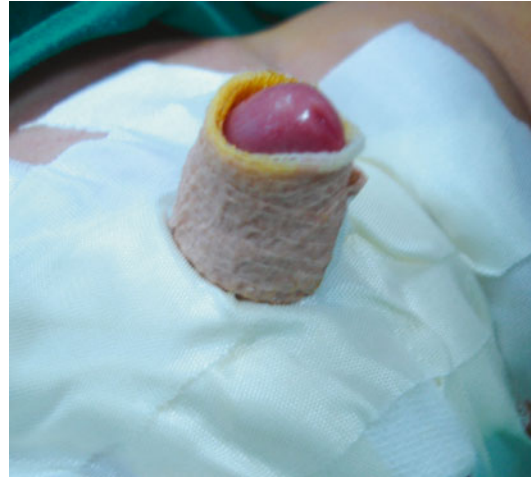

Fig. 2.42 Penile lymphedema responding well after circumcision

with local skin flaps, and the scrotal contents may be covered with uninvolved posterior skin flaps. If inadequate healthy skin is available, the penis and/or scrotum must be covered with split-thickness skin flaps. After definitive surgical therapy, recurrence in adjacent areas may occur [46].

In our experience few cases of penile lymphedema may respond after doing circumcision with application of Elastoplast dressing for 3–4 days (Fig. 2.42).

2.12 Penile Cysts

Incidence

Penile cysts are a very rare congenital anomaly; few cases are recorded and published as a case report.

Congenital epidermal cysts or dermoid cysts occasionally form along the median penile raphe on the ventral aspect of the penile shaft or on the glans; these congenital lesions may result from epithelial rests that become buried during the urethral infolding process. Excision with the use of general anesthesia is recommended unless the cysts are small and asymptomatic (Fig. 2.43).

The most common cystic lesion of the penis is accumulation of epithelial debris, or smegma, under the unretractable foreskin; epidermal inclusion cysts may form after circumcision, hypospadias repair, or other forms of penile surgery and

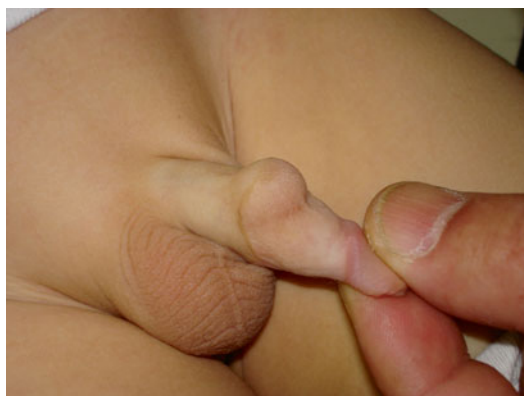

Fig. 2.43 Penile cyst

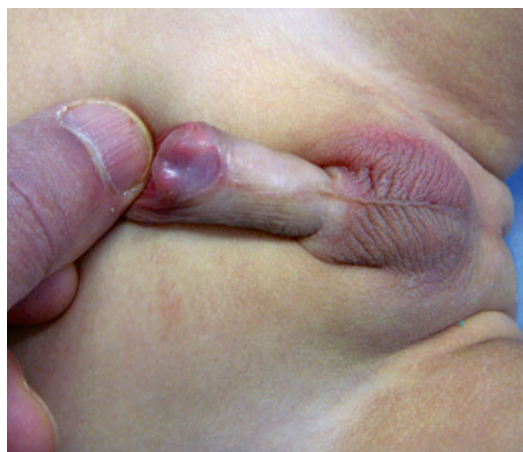

Fig. 2.45 Megameatus in hypospadias

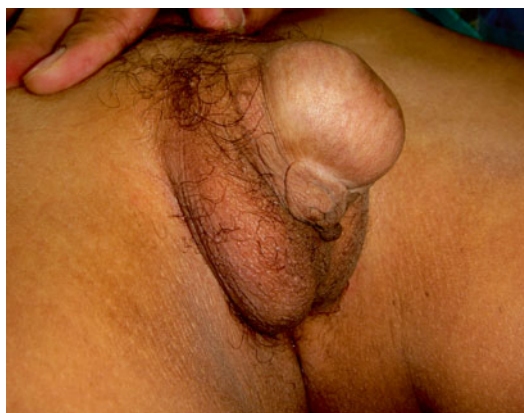

Fig. 2.44 Inclusion cyst of the penis

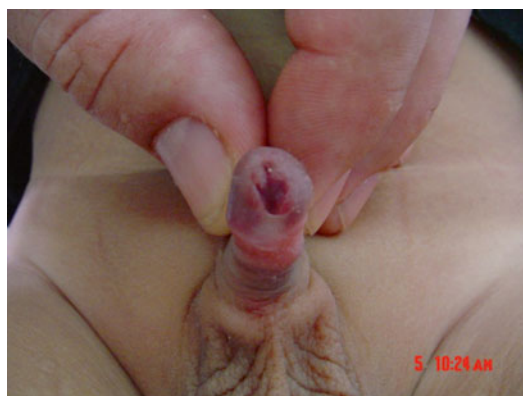

Fig. 2.46 Megameatus intact prepuce

result when islands of epithelium are left behind in the subcutaneous tissue, but these are acquired lesions (Fig. 2.44). These cystic lesions should be treated with simple excision [47].

Parameatal urethral cyst will be discussed with urethral anomalies.

2.13 Megameatus

Definition

It is an abnormal wide urinary meatus usually in its vertical axis, either as an isolated anomaly with deficient preputial skin in the ventral penile shaft, and it could be considered as a variant of hypospadias [48] (Fig. 2.45) or with an intact prepuce, which it is usually known as “megamea-

tus intact prepuce (MIP) anomaly” (Fig. 2.46), and very rarely the wideness of the meatus ensued in the dorsal aspect of the glans creating a variety of minimal epispadias (Fig. 2.47).

Incidence

The overall incidence of the MIP is approximately 3–6 % of anterior hypospadias.

Description

Because there is no external clue to the presence of this variant, the megameatus intact prepuce sometimes comes to light for the first time in a boy who is about to undergo circumcision (Fig. 2.48). Recognition is important, not only because of the uncommon combination of findings, which run

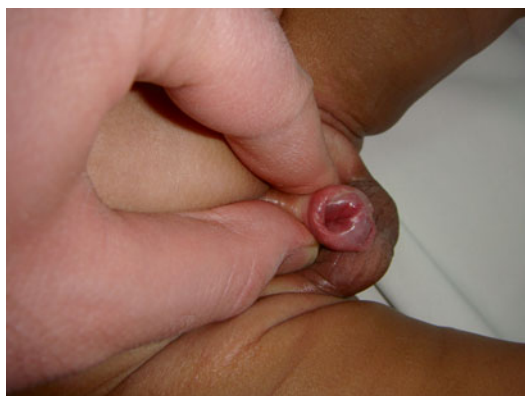

Fig. 2.47 Megameatus occupying the dorsal aspect of the glans

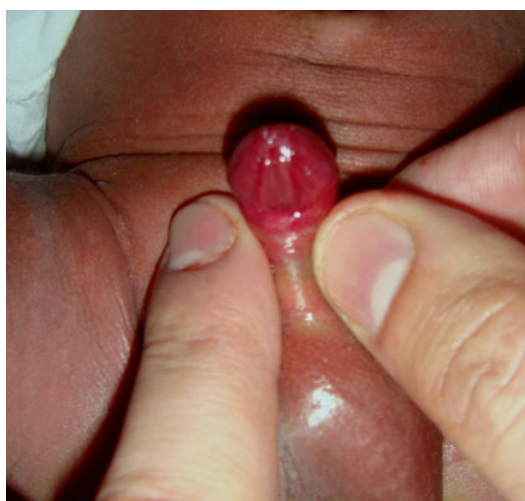

Fig. 2.48 Intact sound prepuce harboring megameatus

contrary to the classical presentation of most hypospadias, but also because of the technical shortcomings that are encountered during repair with standard techniques. There are several differences between MIP and typical distal hypospadias. Obviously, MIP by definition is associated with a completely formed prepuce in contrast to the ventrally deficient foreskin in other cases of hypospadias. Furthermore, the meatus is abundantly large in the MIP variant, whereas many boys with distal hypospadias have a rather small-appearing meatus. Ventral curvature is much less likely to occur in a patient with MIP than in those with other varieties of distal hypospadias.

Management

A suitable technique has been described by Duckett, who also specifically cautioned against the use of the MAGPI repair in view of its high failure rate when used for the attempted repair of this variant.

The pyramid procedure was also described, which allows for an end-on dissection of the distal megameatus–urethra, enabling a reduction in caliber of both while facilitating remodeling of the glans. The procedure has proved to be successful and reliable for this particular hypospadias variant.

Correction basically involves tubularization of the urethral plate to move the meatus to the glans tip. Because the urethral plate is larger than usual in these boys, a relaxing incision is not generally needed as with TIP repair; although when the plate is flat, incision will help “hinge” it to create a vertical and slit meatus. Some patients have a transverse web of skin distal to the meatus, and this should be excised to prevent deflection of the urinary stream.

2.14 Congenital Meatal Stenosis

Meatal stenosis is a condition that almost always is acquired after neonatal circumcision; a significant inflammatory reaction occurs, causing severe meatal inflammation and cicatrix formation, which results in a narrow meatus, a membranous web across the ventral aspect of the meatus, or an eccentric healing process that produces a prominent lip of ventral meatal tissue, and in countries where circumcision is done routinely for almost neonates, meatal stenosis is seen frequently as a complication (Fig. 2.49).

When meatal stenosis is congenital, it occurs primarily in neonates with coronal or subcoronal hypospadias. Obstruction in these cases is unusual, but occasionally UTI occurs or catheterization is necessary during hospitalization, and urgent meatoplasty may need to be performed. In rare cases, a boy with suspected meatal stenosis and obstructive symptoms has an anterior urethral valve in the fossa navicularis [49]. Another form of meatal stenosis that can result in urinary retention is balanitis xerotica obliterans.

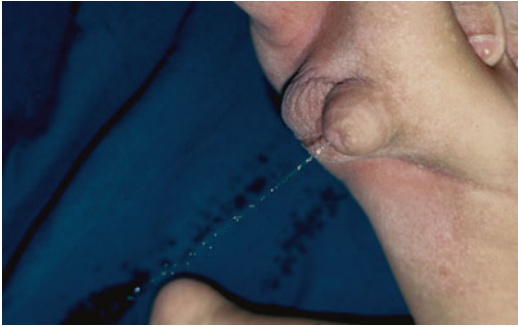

Fig. 2.49 Postcircumcision meatal stenosis

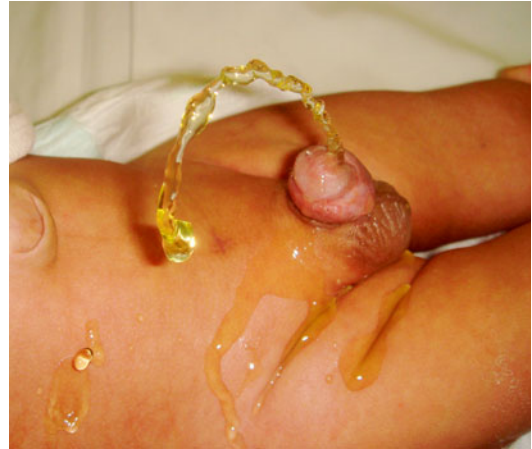

Fig. 2.51 Dorsally diverted stream with meatal stenosis

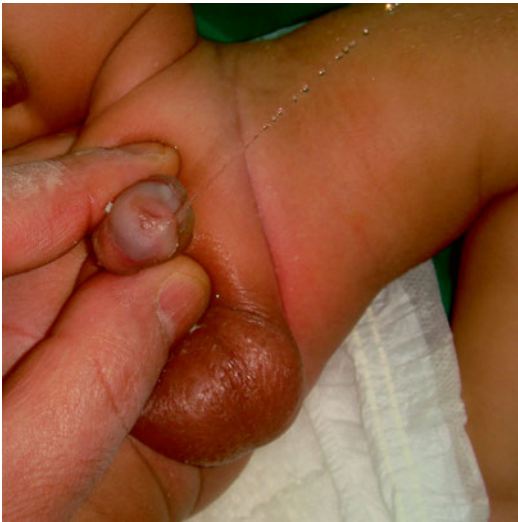

Fig. 2.50 Congenital meatal stenosis with fine stream

Symptoms of meatal stenosis vary with the appearance, in most cases; meatal stenosis does not become apparent until after the child is toilet trained. If the meatus is pinpoint, the boy voids with a forceful, fine stream that has a great casting distance (Fig. 2.50). Some boys have a dorsally deflected stream or a prolonged voiding time (Fig. 2.51). Dysuria, frequency, terminal hematuria, and incontinence are symptoms that may lead to discovery of meatal stenosis but generally are not attributable to this abnormality.

Management

In a boy with suspected meatal stenosis, the meatus should be calibrated with a bougie or assessed with infant sounds. Not infrequently, an

asymptomatic boy with suspected meatal stenosis actually has a compliant meatus of normal caliber. If the meatus is diminished in size or if the child has abnormal voiding symptoms, a renal and bladder ultrasound examination is indicated. If the child has a history of UTIs, a voiding cystourethrogram (VCUG) should be done also. However, meatal stenosis rarely causes obstructive changes in the urinary tract. In boys with UTIs, it is often uncertain whether the infection is the result of meatal stenosis.

In many cases, meatoplasty can be accomplished in the physician's office using EMLA cream for local anesthesia. In addition, 1 % lidocaine with 1:100,000 epinephrine may be infiltrated in the ventral web with a 26 gauge needle for local anesthesia and vasoconstriction. A ventral incision is made toward the frenulum and long enough to provide a meatus of normal caliber, which can be checked with the bougie. The urethral mucosa is sutured to the glans with fine chromic catgut sutures. If the procedure is performed under general anesthesia, the bladder may be filled with saline and compressed manually to be certain that the stream is straight.

Litvak et al. [50] performed a cohort study and demonstrated that a boy younger than 10 years of age should have a meatus of at least 8 French, while boys 11–12 years of age should accommodate at least 10 French (Fig. 2.52). Simple urethral dila-

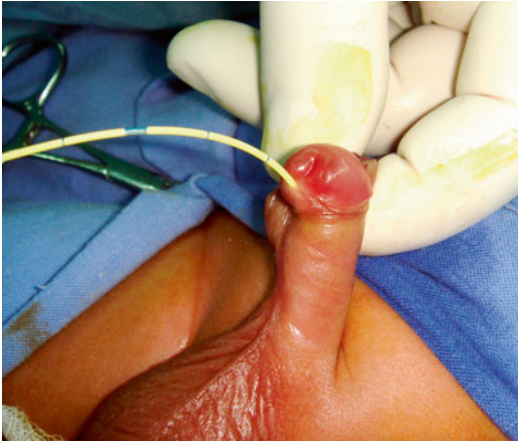

Fig. 2.52 Stenotic meatus admitting only a size 4 French ureteral catheter

tions are not effective in treating meatal stenosis due to high rates of recurrence. Thus, surgical meatotomy is the treatment of choice.

2.15 Congenital Double Meatus

Nomenclature

Accessory meatal dimple, juxtaposed urethral meatus

The normal urinary meatus is a vertical slit-like meatus that commenced at the tip of the penis and ran ventrally.

The position and size of the external urethral meatus in normal boys are consistent, and ventral glans closure is equal to or slightly less than meatal length. These data might be of interest to hypospadiologists in their efforts to reconstruct normal glanular anatomy, and there was an age-dependent increase in meatal length and a similar association was identified for the length of ventral glans closure. There was also a statistically significant proportional relationship between meatal length and length of glans.

Incidence

It is a common finding with different grades of hypospadias (Fig. 2.53), but many cases are reported without any other anomalies; giving more attention to such finding may help more in reporting.

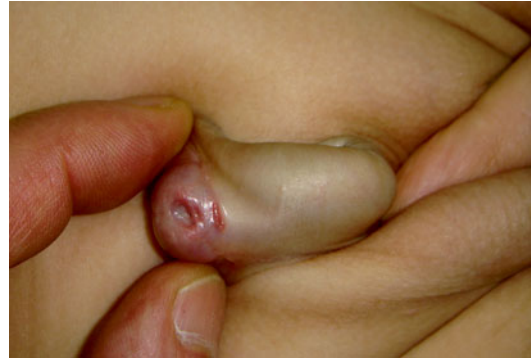

Fig. 2.53 Duplicated meatus with hypospadias

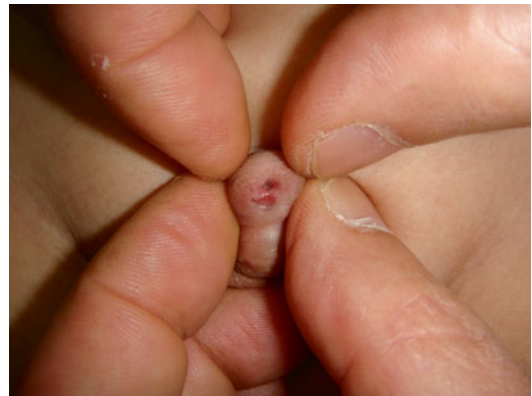

Fig. 2.54 Meatal duplication without hypospadias

Etiology

The distal glanular urethra developed from a solid ectodermal ingrowth of the epidermis which canalizes the glans to fuse urethral folds proximally, so duplicated ectodermal ingrowth and canalization of the glans with one moiety communicate with the proximal urethra, and another one failed to complete the canalization and could stop at the tip of the glans may give rise to the accessory meatus.

Significance

Detection of this anomaly is only important to rule out cases of actual ureteral duplication, so calibration of this dimple will rule out complete extra urethra. As a general rule, the most proximal orifice is the actual urethral orifice connected to the bladder [51] (Fig. 2.54).

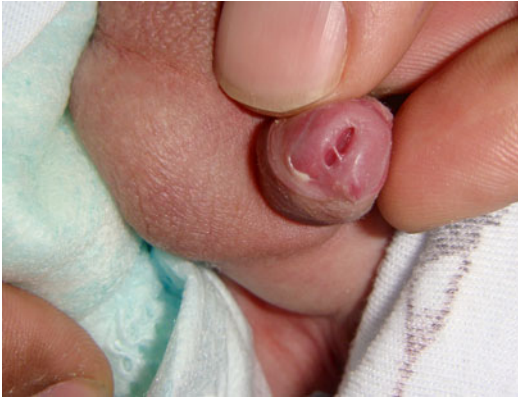

Fig. 2.55 Thin septum between the two meatus

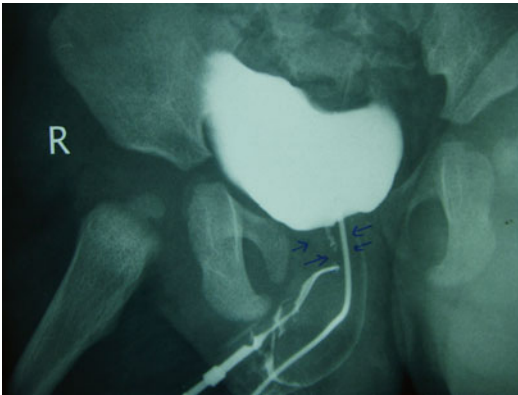


Fig. 2.56 Duplication urethra

In a hypospadiac patient, there may be several meatal openings, which represent openings of paraurethral canals or lacunae of Morgagni. The presence of a distal opening may lead the parents and the inexperienced practitioner to think that the hypospadias is more distal than it really is. In rare cases, the child may have a double meatal opening with a thin septum separating the two openings without any adjuvant urethra (Fig. 2.55), but ascending and micturating cystourethrogram (MCUG) is essential to rule out duplicating urethra, which will be discussed in details in the Chap. 7 (Fig. 2.56).

References

Embryology and Penile Development

1. Yiee JH, Baskin LS. Penile embryology and anatomy. *ScientificWorldJournal*. 2010;10:1174–9.
2. Nelson CP, Park JM, Wan J, et al. The increasing incidence of congenital penile anomalies in the United States. *J Urol*. 2005;174(4 Pt 2):1573–6.

Penile Agenesis (PA)

3. Gautier T, Salient J, Pena S, Imperto-McGinley J, Peterson RE. Testicular function in 2 cases of penile agenesis. *J Urol*. 1981;126:556–7.
4. Kessler WO, McLaughlin 3rd AP. Agenesis of penis. Embryology and management. *Urology*. 1973;1:226–9.
5. Skoog SJ, Belman AB. Aphallia: its classification and management. *J Urol*. 1989;141:589–92.
6. Evans JA, Erdile LB, Greenberg CR. Agenesis of the penis: patterns of associated malformations. *Am J Med Genet*. 1999;84:47–55.
7. Ciftci AO, Senocak ME, Buyukpamukcu N. Male gender assignment in penile agenesis: a case report and review of the literature. *J Pediatr Surg*. 1995;30:1358–60.
8. Caire JT, Ramus RM, Magee KP, Fullington PK, et al. MRI of fetal genitourinary anomalies. *AJR Am J Roentgenol*. 2003;181:1381–5.
9. Hendren WH. The genetic male with absent penis and urethrectal communication: experience with 5 patients. *J Urol*. 1997;157:1469.
10. Tiwari S. Should infants with aphallia be raised as females? *Indian Pediatr*. 2003;40:802–3.

Microphallus

11. Tuladhar R, Davis PG, Batch J, Doyle LW. Establishment of a normal range of penile length in preterm infants. *J Paediatr Child Health*. 1998;34:471.
12. Calderon JS, Zarante I. ANOMALÍAS CONGÉNITAS UROLÓGICAS: Descripción EPIDEMIOLÓGICA Y FACTORES DE RIESGO ASOCIADOS EN COLOMBIA 2001–2004. *Arch Esp Urol*. 2006;59(1):7–14.
13. Sonnenschein C, Soto AM. An updated review of environmental estrogen and androgen mimics and antagonists. *J Steroid Biochem Mol Biol*. 1998;65(1–6):143–50.
14. Williams-Ashman HG, Reddi AH. Differentiation of mesenchymal tissues during phallic morphogenesis with emphasis on the penis: role of androgens and other regulatory agents. *J Steroid Biochem Mol Biol*. 1991;39:873–81.
15. Wisniewski AB, Migeon CJ, Gearhart JP, et al. Congenital micropenis: long-term medical, surgical

and psychosexual follow-up of individuals raised male or female. *Horm Res.* 2001;56(1-2):3-11.

16. Bin-Abbas B, Conte FA, Grumbach MM, Kaplan SL. Congenital hypogonadotropic hypogonadism and micropenis: effect of testosterone treatment on adult penile size. Why sex reversal is not indicated. *J Pediatr.* 1999;134(5):579-83.
17. Husmann DA. The androgen insensitive micropenis: long- term follow-up into adulthood. *J Pediatr Endocrinol Metab.* 2004;17(8):1037-41.
18. Lee PA, Houk CP. Outcome studies among men with micropenis. *J Pediatr Endocrinol Metab.* 2004;17(8):1043-53.

Megalopenis

19. ÜNALPN A, URAN N, GİRAY Ö, ERÇAL D. Inversion of chromosome 15 in a family with benign familial infantile seizures. *J Neurol Sci [Turk].* 2008;25:055-8.
20. Sabry MA, Obenbergerova D, Al-Sawan R, Al Saleh Q, et al. Femoral hypoplasia-unusual facies syndrome with bifid hallux, absent tibia, and macrophallus: a report of a Bedouin baby. *J Med Genet.* 1996;33:165-7.

Penile Duplication (PD)

21. Nesbit RM, Bromme W. Double penis and double bladder with report of case. *Am J Roentgen.* 1933;30:497.
22. Marti-Bonmati L, Menor F, Gomez J, et al. Value of sonography in true complete diphallia. *J Urol.* 1989;142:356.
23. Hollowell Jr JG, Witherington R, Ballagas AJ, et al. Embryological consideration of diphallus and associated anomalies. *J Urol.* 1977;111:728-32.
24. Schneider P: Cited by Lamitter JK, Uson AC, Melicow AC. Chapter 77: The male genital tract. In: Mustard WT, Ravitch MM, Snyder WH, et al., editors. *Pediatric surgery*, vol 2. 2nd ed. Chicago: Year Book Medical Publishers; 1969. p. 1263.

Penile Deviation

25. Verneuil. Torsion congenitale du penis avec hypospadias. *Bullerin de la Socete de Chirurgie de Paris.* 1857;8:68-70.
26. Darewicz B, Kudelski J, Szynaka B, Nowak HF, Darewicz J. Ultrastructure of the tunica albuginea in congenital penile curvature. *J Urol.* 2001;166:1766-8.
27. Kogan BA. Intraoperative pharmacological erection as an aid to pediatric hypospadias repair. *J Urol.* 2000;164:2058.

Penile Chordee

28. Smith CK. Surgical procedures for correction of hypospadias. *J Urol.* 1938;40:239.
29. Caesar RE, Caldamone AA. The use of free grafts for correcting penile chordee. *J Urol.* 2000;164(5):1691-3.

Webbed Penis

30. Rudin IE, Osipova AI. Experience of surgical treatment of webbed penis in children. *Urologiia.* 2003;2:36-41.
31. Brisson P, Patel H, Chan M, Feins N. Penoplasty for buried penis. *J Pediatr Surg.* 2001;36:412.
32. Bergeson PS, Hopkin RJ, Bailey Jr RB, et al. The inconspicuous penis. *Pediatrics.* 1993;92:794.

Penoscrotal Transposition (PST)

33. Appleby LH. An unusual arrangement of the external genitalia. *Can Med Assoc J.* 1923;13:514-6.
34. McIlvoy DB, Harris HS. Transposition of the penis and scrotum: case report. *J Urol.* 1955;73:540-3.
35. Avolio L, Karmarkar SJ, Martucciello G. Complete penoscrotal transposition. *Urology.* 2006;67:1287.
36. Lamm DL, Kaplan GW. Accessory and ectopic scrota. *Urology.* 1977;9:149-53.
37. Takayasu H, Ueno A, Tsukada O. Accessory scrotum: a case report. *J Urol* 1974;112:826-7.
38. Sule JD, Skoog SJ, Tank ES. Perineal lipoma and the accessory labioscrotal fold: an etiological relationship. *J Urol.* 1994;151:475-7.
39. Glenn JF, Anderson EE. Surgical correction of incomplete penoscrotal transposition. *J Urol.* 1973;110:603-5.
40. Forshall I, Rickham P. Transposition of the penis and scrotum. *Br J Urol.* 1956;38:250-2.

Genital Median Raphe Anomalies (GMR)

41. Fahmy MA. The spectrum of genital median raphe anomalies among infants undergoing ritual circumcision. *J Pediatr Urol.* 2013;9:872-7.
42. O'Callaghan M, Young ID. The Townes-Brocks syndrome. *J Med Genet.* 1990;27:13.
43. Gutt AA, Pendharka PS. Transverse testicular ectopia associated with persistent Mullerian duct syndrome. *Br J Radiol.* 2008;81:176-8, 457-61.
44. Levitt MA, Peña A. Anorectal malformations. *Orphanet J Rare Dis.* 2007;2:33.1-13.

Penile Lymphedema

45. Hilliard RI, McKendry JBJ, Phillips MJ. Congenital abnormalities of the lymphatic system: a new clinical classification. *Pediatrics*. 1990;86:988.
46. Dandapat MC, Mohapatro SK, Patro SK. Elephantiasis of the penis and scrotum. A review of 350 cases. *Am J Surg*. 1985;149:686–90.

Penile Cysts

47. LaNasa JA. Epidermal cyst of median raphe. *Urology*. 1976;8(4):401–2.

Megameatus

48. Hadidi AT. Classification of hypospadias. In: Hadidi AT, Azmy AF, editors. *Hypospadias surgery: an illustrated guide*. 1st ed. Berlin: Springer; 2004. p. 80.

Congenital Meatal Stenosis

49. Scherz HC, Kaplan GW, Packer MG. Anterior urethral valves in the fossa navicularis. *J Urol*. 1987;138:1211–3.

50. Litvak AS, Morris JA, McRoberts JW. Normal size of the urethral meatus in boys. *J Urol*. 1976;115:736–7.

Congenital Double Meatus

51. Hadidi AT. Classification of hypospadias. In: Hadidi AT, Azmy AF, editors. *Hypospadias surgery: an illustrated guide*. 1st ed. Berlin: Springer; 2004. p. 80.

Suggested Reading

- Aaronson IA. Micropenis: medical and surgical implications. *J Urol*. 1994;152:4–14.
- Baskin LS, Erol A, Li YW, Liu WH. Anatomy of the neurovascular bundle: is safe mobilization possible? *J Urol*. 2000;164:977–80.
- Casale AJ, Beck SD, Cain MP, et al. Concealed penis in childhood: a spectrum of etiology and treatment. *J Urol*. 1999;162:1165–8.
- Husmann DA. The androgen insensitive micropenis: long-term follow-up into adulthood. *J Pediatr Endocrinol Metab*. 2004;17(8):1037–41.
- Walsh PC, Wilson JD, Allen TD et al. Clinical and endocrinological evaluation of patients with congenital micropallus. *J Urol*. 1978; 120:90-5.

<http://www.springer.com/978-3-662-43679-0>

Rare Congenital Genitourinary Anomalies

An Illustrated Reference Guide

Baky Fahmy, M.A.

2015, XVI, 235 p. 346 illus., 283 illus. in color.,

Hardcover

ISBN: 978-3-662-43679-0