

Ciro Imbimbo and Davide Arcaniolo

## Contents

2.1	<b>Introduction</b> .....	15
2.2	<b>Epidemiology</b> .....	16
2.3	<b>Diagnosis</b> .....	16
2.4	<b>Treatment</b> .....	16
2.4.1	Psychotherapy .....	16
2.4.2	Hormonal Therapy .....	17
2.4.3	Real-Life Experience .....	17
2.5	<b>Vaginoplasty</b> .....	18
2.6	<b>Simple Penile Skin Inversion</b> .....	18
2.7	<b>Penoscrotal Flap</b> .....	19
2.8	<b>Vaginoplasty According to Perovic's Technique</b> .....	23
2.9	<b>Enterovaginoplasty</b> .....	25
2.9.1	Ileal Vaginoplasty .....	25
2.9.2	Rectosigmoidal Vaginoplasty .....	26
2.10	<b>Neovaginal Expanding Devices</b> .....	26
2.11	<b>Complications</b> .....	27
	<b>References</b> .....	27

## 2.1 Introduction

The *Diagnostic and Statistical Manual of Mental Disorders*, fourth edition, text revision [DSM-IV-TR], defines gender identity disorder (GID) as a “strong and persistent cross-gender identification and a patient’s persistent discomfort with his or her sex and sense of inappropriateness in the gender role of that sex.” The current edition of the *Diagnostic and Statistical Manual of Mental Disorders* has five criteria that must be met before a diagnosis of gender identity disorder can be given:

1. There must be evidence of a strong and persistent cross-gender identification.
2. This cross-gender identification must not merely be a desire for any perceived cultural advantages of being the other sex.
3. There must also be evidence of persistent discomfort about one’s assigned sex or a sense of inappropriateness in the gender role of that sex.
4. The individual must not have a concurrent physical intersex condition (e.g., androgen insensitivity syndrome or congenital adrenal hyperplasia).
5. There must be evidence of clinically significant distress or impairment in social, occupational, or other important areas of functioning.

This biological sexual orientation does not correspond to the patient’s inner perception of him or herself, which, in turn, causes a strong desire to alter his or her natural-born anatomical appearance. The trained mental health professional is obligated to determine if a patient meets the above-stated criteria

C. Imbimbo (✉) • D. Arcaniolo  
Department of Urology, Policlinico University  
Federico II of Naples, Naples, Italy  
e-mail: [ciro.imbimbo@unina.it](mailto:ciro.imbimbo@unina.it);  
[davide\\_arcaniolo@yahoo.it](mailto:davide_arcaniolo@yahoo.it)

for an irreversible gender transposition and if he or she will benefit from sex-reassignment treatment (Cohen-Kettenis and Gooren 1999).

---

## 2.2 Epidemiology

When gender identity disorder first came to the attention of professionals, clinical perspectives were largely focused on how to identify candidates for sex reassignment surgery. As the field matured, professionals recognized that some people with bona fide gender identity disorder neither desired nor were to be considered candidates for sex-reassignment surgery. This became problematic in epidemiologic studies. The *Diagnostic and Statistical Manual of Mental Disorders*, 4th edition, regrouped different results from different investigations and reported an average prevalence of 1 in 12,000 biological men and 1 in 100,000 biological women. The difference between men and women varied depending on the time period, the country, and the study. In the majority of the studies, there were more men than women among the sex-change applicants, with an average ratio being 1:3 (women to men) (Ravenna 1998).

---

## 2.3 Diagnosis

Transsexualism is not a homogeneous phenomenon. Diagnosing transsexualism is quite difficult because the results of psychological testing are not conclusive. Standards of care of the International Harry Benjamin Gender Dysphoria Association have established a diagnostic process divided into two phases for patients seeking SRS treatment. In the first phase a formal diagnosis is made using DSM or International Classification of Diseases (ICD) criteria. Risk factors are estimated to ensure that the individual can tolerate the life changes that SRS will bring. In the second diagnostic phase, the patient has to live permanently in the role of the desired sex. The clinicians have to inform the family members, and the patient must choose a new first name. In this phase the patient can start hormonal therapy with different times and modalities depending

upon the treatment center. A certain number of psychotherapy sessions are also required by some clinicians; however, psychotherapy is not mandatory.

The differential diagnosis should include non-conformity to stereotypical sex role behavior, transvestic fetishism, gender identity disorder not otherwise specified (with a concurrent congenital intersex condition), and schizophrenia (Belgrano et al. 1999).

---

## 2.4 Treatment

### 2.4.1 Psychotherapy

Psychotherapy is a series of highly refined interactive communications between a professional who is knowledgeable about how people suffer emotionally and how the suffering may be alleviated and one who is experiencing gender distress. The psychotherapeutic sessions initiate a developmental process by enabling a person's history to be appreciated, current dilemmas understood, and unrealistic expectations and self-destructive behavior identified. The usual objectives of psychotherapy are the enabling of a long-term, stable lifestyle with realistic chances for success in relationships, education, work, and healthy gender and role identification. Gender distress often impedes relationships, work, and educational goals. Typically psychotherapy consists of regularly held 50 min sessions. The therapist should make it clear that it is the patient's right to choose psychotherapy among many therapeutic options. Ideally, psychotherapy is a collaborative effort. The therapist must be certain that the patient understands the concepts of eligibility and readiness because they must cooperate in defining the patient's problems and in monitoring progress in dealing with them. Benefits from psychotherapy may be attained at every stage of gender evolution. This includes the postsurgical period when the anatomic obstacles to gender comfort have been removed and the transsexual continues to feel a lack of genuine comfort and skill in living in the new gender role. Psychotherapy can be beneficial to people who are merely gender confused as well as for those desiring sex reassignment

**Table 2.1** Absolute and relative contraindications for hormone therapy in M-to-F transsexuals

Absolute contraindications	Severe diastolic hypertension Thrombophlebitis or thromboembolic disease Severe hepatic dysfunction Cerebrovascular disease
Relative contraindications	Heavy cigarette consumption Family history of breast cancer Hyperprolactinaemia Marked obesity (WHR 0.95)

surgery. In these cases psychotherapeutic intervention may help people to better understand and cope with gender issues and to arrive at alternative options to solving their problems. Treatment in psychiatric hospitals may be needed for those suffering from severe psychiatric conditions (American Psychiatric Association 2000; Michel et al. 2001).

### 2.4.2 Hormonal Therapy

Before administering hormonal therapy, the endocrinologist should perform a careful anamnesis, a complete clinical examination, and a basal hormonal checkup in order to detect possible contraindications. Relative and absolute contraindications for hormone therapy are summarized in Table 2.1. The desired effects of hormonal treatment are decrease in blood testosterone, increase in blood estradiol, mammary gland hyperplasia, a decrease in erections, reduction of facial hair, modification of speech, and gynoid fat deposit. Patients must be carefully advised about possible undesirable side effects of hormonal treatment such as thromboembolic disorders, depression, decreased libido, hyperprolactinemia, and an increase in the bilirubin blood levels which are the most prevalent. Guidelines on hormonal treatment are summarized in Table 2.2.

### 2.4.3 Real-Life Experience

The act of fully adopting a new or evolving gender role for the events and processes of everyday life is known as the real-life experience. The

**Table 2.2** Guidelines on hormone therapy

Phase	
<i>Presurgical A.1.:</i> Suppression of the original sex characteristics (optional)	LHRH superagonists (i.m. monthly?) and/or spironolactone ( $100 \pm 200$ mg/day) or cyproterone acetate ( $50 \pm 100$ mg/day)
<i>Presurgical A.2.:</i> Induction of designated sex characteristics	Ethinyl estradiol ( $50 \pm 100$ mg/day) or conjugated estrogen ( $1.25 \pm 2.50$ mg/day) or estradiol benzoate, estradiol phenylpropionate (25 mg/2 weeks) <i>Optional</i> Spironolactone ( $100 \pm 200$ mg/day) or cyproterone acetate ( $50 \pm 100$ mg/day)
<i>Postsurgical B.:</i> Post-castration	Estrogens (see A.2.) or transdermal form ( $50 \pm 100$ mg/day) <i>Optional</i> Progesterone (100 mg/day for 2 weeks/month) or classic postmenopausal hormone therapy

real-life experience is essential in the transition process to the gender role that conforms with personal gender identity. Since changing one's gender role has immediate profound personal and social consequences, the decision to do so should be preceded by a full awareness of what the familial, vocational, interpersonal, educational, economic, and legal consequences are likely to be. Professionals have a responsibility to discuss these predictable consequences which represent external reality issues that must be confronted in order to successfully assume the new gender role. These factors can be quite different from the personal happiness stemming from the new gender role that is envisioned prior to the real-life experience. When clinicians assess the quality of a person's real-life experience in the new gender role, the following abilities are estimated:

1. The ability to maintain full- or part-time employment
2. The ability to thrive as a student
3. The ability to function in community-based volunteer activities
4. The ability to undertake any combination of items 1–3
5. The ability to acquire a new (legal) first or last name
6. The ability to provide documentation that people other than the therapist can predict that the patient will function in the new gender role.

Surgical treatment for a person with a gender identity disorder is not merely another elective procedure. Typical elective procedures traditionally involve only a private mutually consenting contract between a suffering person and a technically competent surgeon. Surgeries for GID can be undertaken only after a comprehensive evaluation by a qualified mental health professional has been conducted. Surgery may then be performed once written documentation testifies that a comprehensive evaluation has been made and that the person has met the eligibility and readiness criteria. By following this procedure the mental health professional, the physician prescribing hormones, the surgeon, and the patient all share in the responsibility of taking the decision to make irreversible changes to the body. The patient who has decided to undergo genital or breast surgery, however, tends to view the surgery as the most important and effective treatment for correcting the underlying problem. Surgical procedures may include orchiectomy, penectomy, vaginoplasty, and augmenting mammoplasty. Vaginoplasty requires both skilled surgical procedure and competent postoperative treatment. Additive mastoplasty may be performed prior to vaginoplasty if the physician prescribing hormones and the surgeon have both attested that breast enlargement after undergoing hormonal treatment for 2 years is not sufficient for comfort in the social gender role. Other surgeries that may be performed to assist in feminization include: reduction thyroid chondroplasty, suction-assisted lipoplasty of the waist, rhinoplasty, facial bone reduction, face-lift, and blepharoplasty. Unlike genital reconstruction therapy, these surgeries do not require letters of recommendation from mental health

professionals. Patients who elect this procedure should wait until all other surgeries requiring general anesthesia with intubation are completed in order to protect their vocal cords.

---

## 2.5 Vaginoplasty

A male-to-female gender surgical reconversion can be performed using several different techniques; however, all of them share a few basic common surgical steps:

1. Bilateral orchidectomy
2. Penile disassembling leading to separation of urethral corpus spongiosum, corpora cavernosa, glands, and dorsal neurovascular bundle
3. Excision of corpora cavernosa and distal urethra
4. Preparation of a urethral stump and urethrocutaneous anastomosis
5. Creation of a prostaticorectal space which allows to allocate the neovagina
6. Vulvoplasty

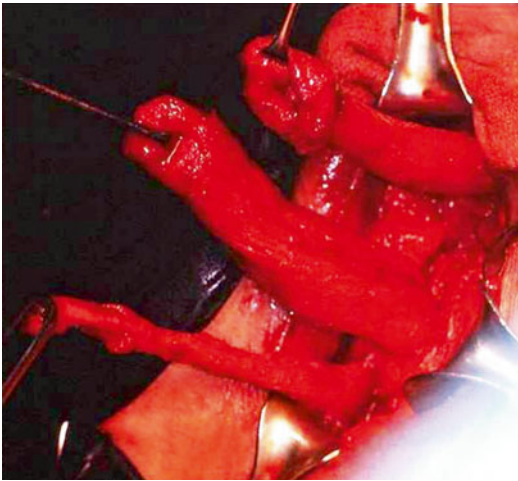
At present, the most widely used surgical techniques are:

1. Simple penile skin inversion
2. Penoscrotal flap
3. Onlay urethral flap (Perovic's technique)
4. Enterovaginoplasty

---

## 2.6 Simple Penile Skin Inversion

After anesthesia is induced, the patient is placed in the lithotomy position. A vertical perineal incision is made from the base of the penis to the midline of the scrotum to a point situated 1 cm above the anal verge. The incision is extended through the subcutaneous tissue in order to expose the urethral corpus spongiosum and corpora cavernosa bilaterally. A bilateral orchidectomy is performed by dissecting and suturing both spermatic cords at the level of external inguinal rings. Once this is done, the proximal ends of these structures will then retract into the inguinal canal. Once this happens, the external inguinal ring is closed bilaterally so as to avoid future weakness that can lead to inguinal hernia. The next step is the penile degloving where the



**Fig. 2.1** Penile disassembling. The penile skin is severed from the corpus spongiosum and the corpora cavernosa. The glans remains with the penile skin tube

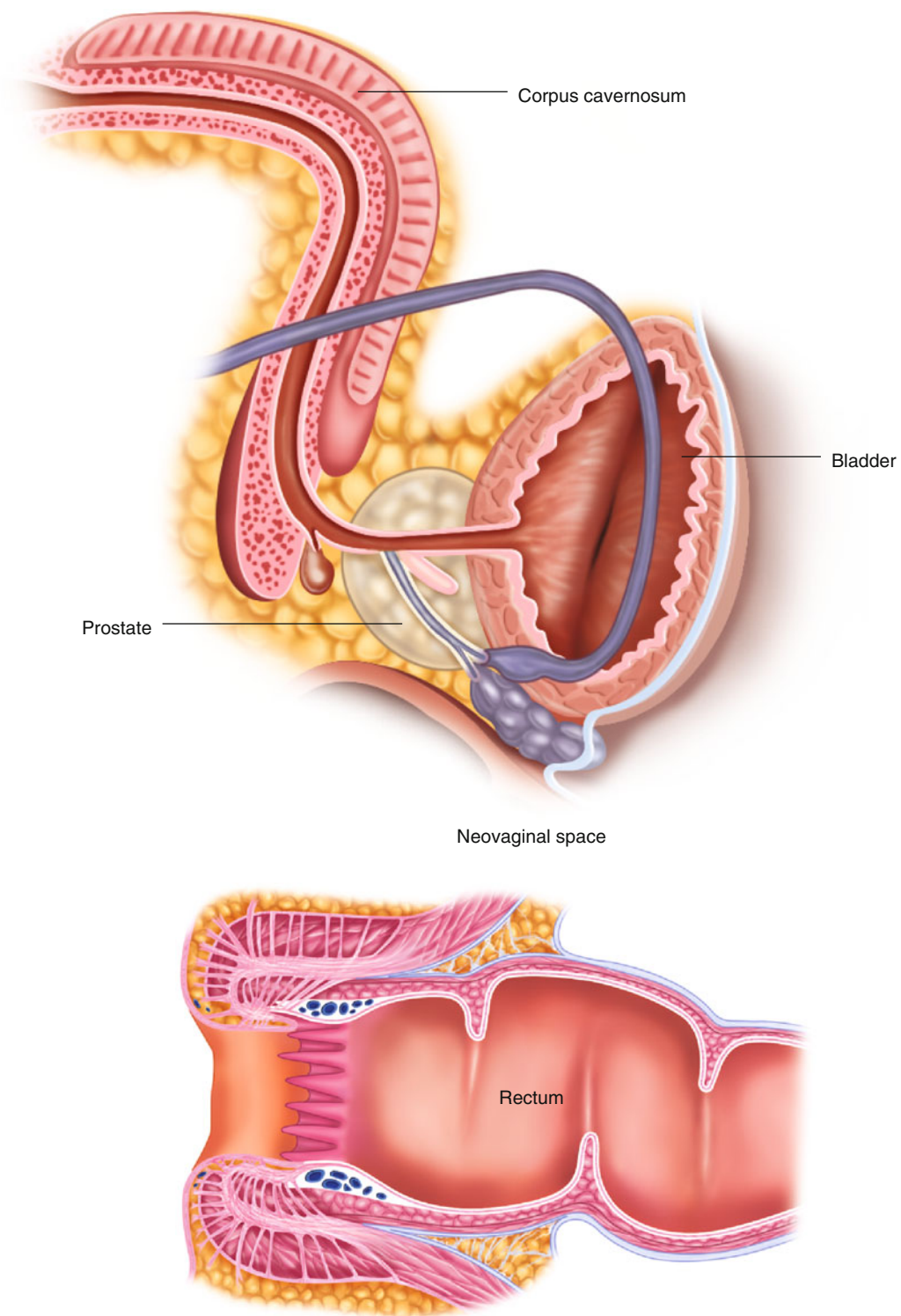
penis is stretched and two circumferential incisions through the penile skin are made; one at the base of the penis and the other distally immediately under the glans. The penile skin with the glans penis is severed from the corpus spongiosum and the corpora cavernosa. The glans remains with the penile skin tube (Fig. 2.1). Through sharp dissection the penile skin is then isolated from the shaft and then reverted and placed around a silicone vaginal mold. At the tip of the mold, the penile skin is closed with a running absorbable suture. This sutured end will become the apex of the neovagina. Following this step the corpus spongiosum is separated from the corpora cavernosa. The corpora cavernosa are cut in the midline, and hemostatic sutures are placed through the proximal base under the pubic ramus.

The section of each corpus cavernosum should be made as proximal as possible, and a limited amount of tissue should remain. A running absorbable suture is routinely performed on the residual erectile tissue in order to avoid painful erection during sexual arousal. The bulbospongiosus muscle is then severed, and the corpus spongiosum is mobilized. The central tendon of the perineum is incised, and a careful, blunt dissection is performed in order to create a wide space between the rectum and prostate where the neovagina will be placed (Fig. 2.2). The Denonvilliers

fascia is then identified, and the blunt dissection continues through this avascular plane, transecting the medial fibers of the levator ani muscles in order to obtain an optimal depth. The inverted penile skin tube distended with the vaginal mold is placed in the perineal neocavity. When the patient wishes to have external sensitivity with the creation of a neoclitoris, only a quarter of the glans is left uncovered in order to form the clitoris, while three-quarters are de-epithelialized and placed subcutaneously to ensure a deep internal sensitivity. The base of the penile cylinder is fixed to the periosteum of the pubis by heavy nonabsorbable traction sutures. An elliptical 1.5 cm incision is then performed on the anterior wall of the neovagina by passing the adequately shortened urethra through this incision and suturing it with 4-0 absorbable sutures to the skin. The most posterior aspect of the skin tube is sutured to the posterior aspect of the initial incision. The sutures are continued laterally and frontally in order to form the labia majora. Finally, if necessary, cosmetic refinements can be made such as the reduction of excessive skin of the labia majora and the creation of a labia minora. At the conclusion of the procedure, a Foley catheter is inserted and a compressive dressing applied. The Foley catheter is removed after 5–7 days (Glenn 1980).

## 2.7 Penoscrotal Flap

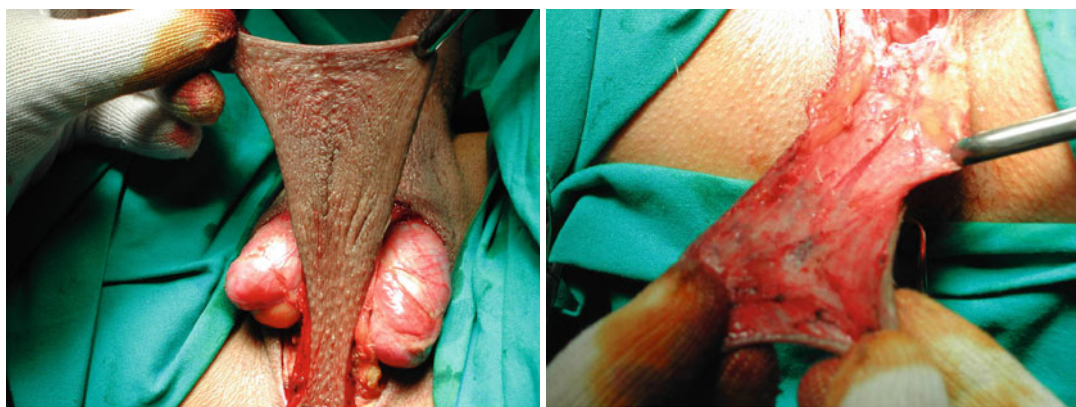
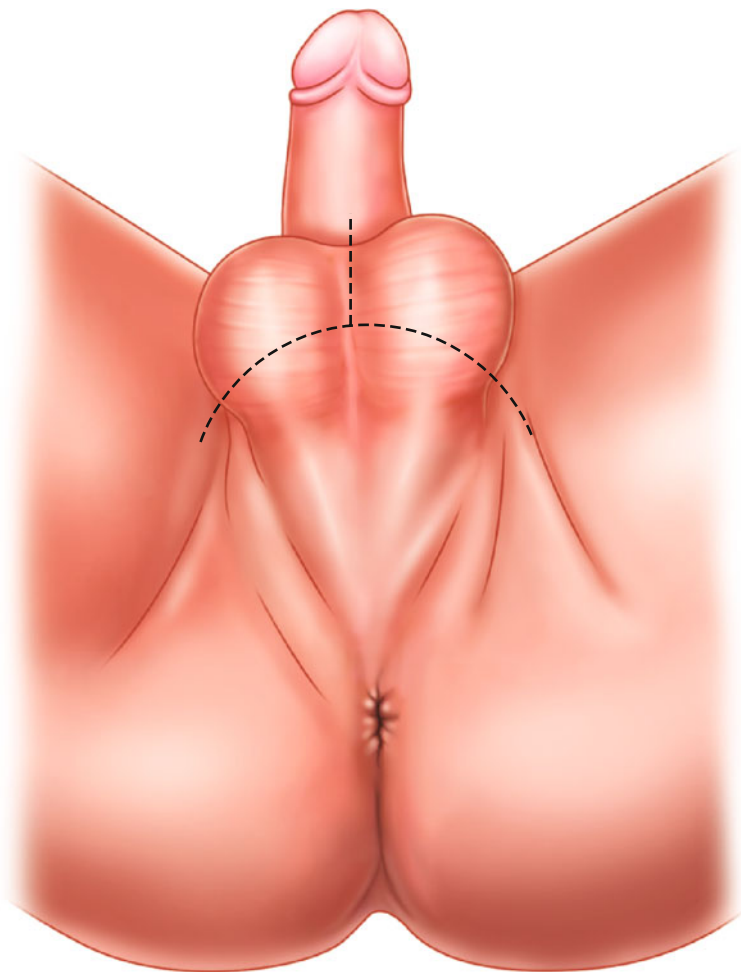
The penoscrotal flap is the most widely used vaginoplasty technique in male-to-female transsexualism. This technique is particularly advisable when a penis of a small dimension does not permit the penile skin inversion technique. With the patient under general anesthesia placed in a lithotomic position, an inverted U-shape incision on the posterior aspect of the scrotum is performed (Fig. 2.3). A pedicle scrotal flap is then created taking care to carefully preserve the subcutaneous vascularization (Figs. 2.4 and 2.5). An ensuing penile degloving is conducted by both distal and proximal dissections. The penile and scrotal flap will constitute the anterior and posterior wall of the neovagina, respectively. The corpus spongiosum is then isolated starting from the crura up to



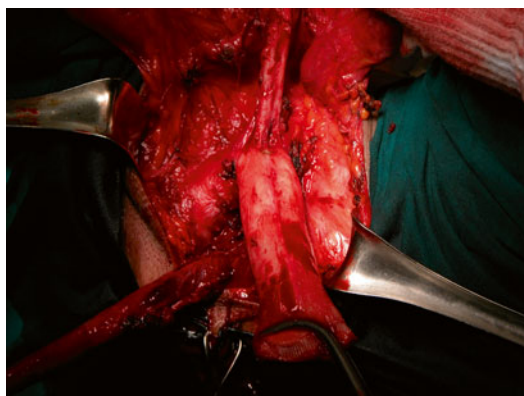
**Fig. 2.2** Creation of the neovaginal space. *B* bladder, *R* rectum, *P* prostate, *CC* corpus cavernosum



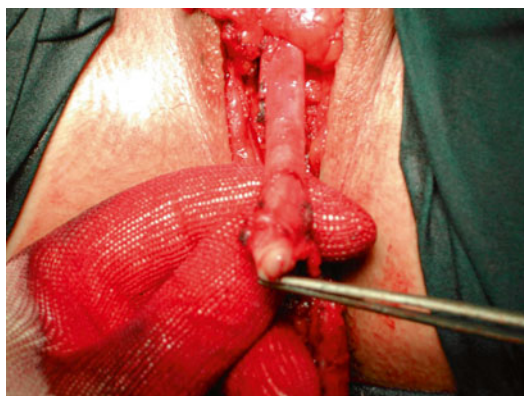**Fig. 2.3** Inverted U-shape incision of the scrotum



**Figs. 2.4 and 2.5** Pedicle scrotal flap with subcutaneous vascularization carefully preserved

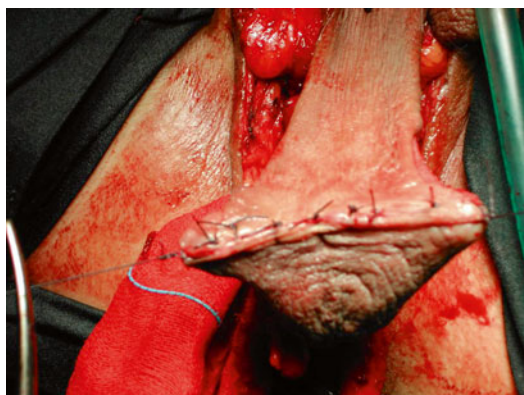

**Fig. 2.6** Penile disassembling. Corpora cavernosa are separated from penile skin and glans with neurovascular bundle



**Fig. 2.7** Reconstruction of neoclitoris from penis glans

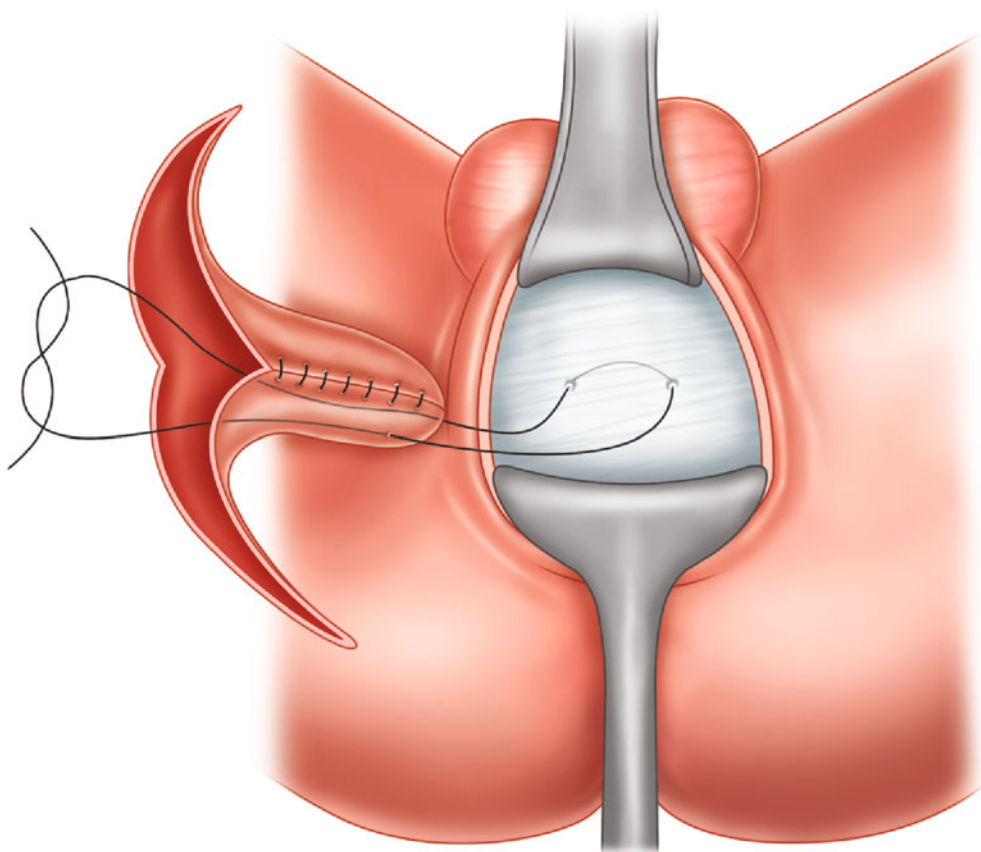
the penile glans. Through a bilateral incision of the Buck's fascia, a plane is created between the tunica albuginea and the dorsal neurovascular bundle whose connection to the glans is carefully preserved. The plane is initially developed at the level of the distal part of the penis. The glans can now be safely detached from the corpora cavernosa, and neurovascular bundle isolation can be carried out in a retrograde fashion. At this point all the anatomical components involved are now disassembled (Fig. 2.6). A double hemostatic stitch is passed through the crura of each corpus cavernosum. The corpora are then excised as proximally as possible, erectile tissue is cauterized, and residual bleeding controlled with a running suture. Before proceeding with the steps that follow, a bilateral orchidectomy is performed. A V-shape incision is performed on the glans, and a cuneus of glandular tissue is used for neoclitoris reconstruction (Fig. 2.7). In order to prevent inhes-tetism and uncomfortable bulging in the anterior vaginal wall, a reduction of the urethral bulb is performed with a nonabsorbable suture, taking care not to cause bladder outlet obstruction. After incision of the central tendon of the perineum, a plane is developed between the prostate and the rectum in order to expose the Denonvilliers fascia. The penile skin is then detubularized to obtain a pedicle flap, taking care to preserve vascularization. The penile and scrotal flaps are assembled together through an interrupted absorbable suture to constitute the neovagina (Fig. 2.8). The fixation



**Fig. 2.8** The penile and scrotal flaps are assembled together through an interrupted absorbable suture to constitute the neovagina

of the cul-de-sac in the retroprostatic space is crucial to prevent the neovagina from prolapsing. A Prolene stitch is passed through the Denonvilliers fascia, and both ends of the suture are passed through the penoscrotal flap at the level of the cul-de-sac. The suture is then tied while a vaginal valve keeps the neovagina in position, obtaining optimal fixation (Fig. 2.9). A small incision on the anterior vaginal wall is performed to allocate the neoclitoris. The urethra is conveniently reduced and then is passed through a second incision which is performed more ventrally. The urethra is then spatulated. Possible bleedings can be controlled with a LigaSure device. The





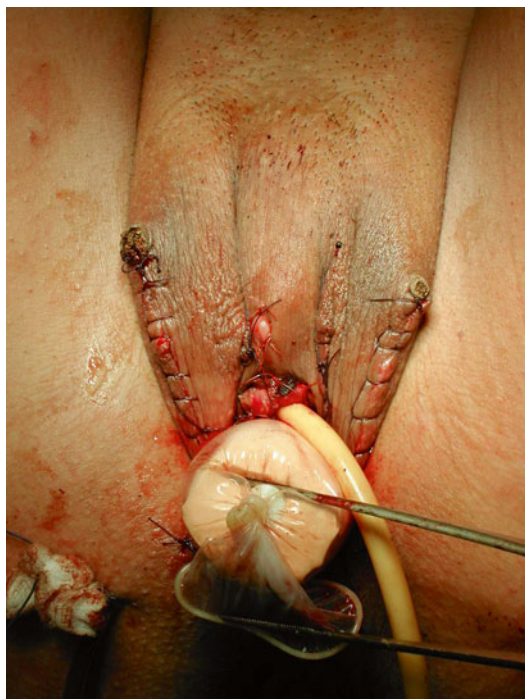**Fig. 2.9** A Prolene stitch is passed through the Denonvilliers fascia, and both ends of the suture are passed through the penoscrotal flap in order to obtain the fixation of the cul-de-sac in the retroprostatic space

urethrocutaneous anastomosis is then carried out with interrupted absorbable sutures. A hemostatic sponge is wrapped around the neomeatus to control residual bleeding. After reconstruction of the labia from the scrotal skin, a vaginal tutor is left in position (Fig. 2.10). The catheter is removed 5 days after surgery, and the patient is discharged after 7 days (Glenn 1980; Meyer et al. 2001; Small 1987).

## 2.8 Vaginoplasty According to Perovic's Technique

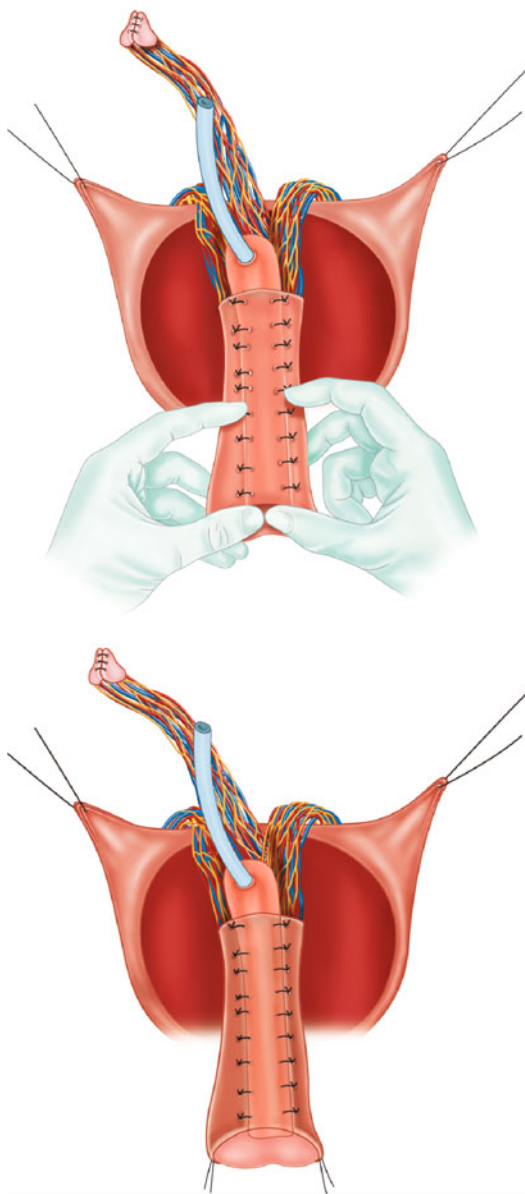
In the Perovic's vaginoplasty technique, the neovagina is created from an inverted pedicled island penile skin flap and a vascularized urethral

flap. After a bilateral orchidectomy, as has been described for other techniques, the penis is disassembled into its anatomical components (corpora cavernosa, the glans cap with the urethra and its neurovascular bundle, and the vascularized penile skin). The corpora cavernosa are excised as proximally as possible, the erectile tissue is destroyed, and the tunica albuginea is sutured with 2-0 absorbable sutures. The glans is divided into two parts, ventral and dorsal, as the dorsal part of the glans will form the neoclititoris. To achieve this, the glans is reduced by severing the central ventral tissue and leaving the sides of the glans intact in order to avoid possible injuries to the neurovascular bundle. The sides of the dorsal half of the glans are then de-epithelialized and sutured to obtain a conical shape which is necessary for the construction



**Fig. 2.10** At the end of operation, a vaginal tutor and a Foley catheter are placed

of the neoclitoris. The ventral part of the glans which is still connected to the urethra will become the neocervix at the base of the neovagina. The bulbospongiosus muscle must be carefully separated from the bulbar urethra to preserve the fascial sheath. The urethra is then spatulated and used to create the mucosal part of the neovagina. Any bleeding in the bulbar urethra during this phase can be controlled with hemostatic sutures without using electrocautery so as to preserve the vascularization of the urethral flap. The urethra is then shortened, and the neoclitoris is placed above the new urethral meatus. When reconstructing the neovagina, a vascularized island tube flap is molded from the skin of the penile body and prepuce. The incision is performed circa 2 cm above the base of the mobilized penile skin in order to obtain an extended vascularized pedicle for the tube. A hole is then made at the base of the pedicle to transpose the urethral flap. On the dorsal side of the skin tube flap, only the skin is incised, whereas the vascularized subcutaneous tissue remains intact. The urethral flap, which is transposed through



**Fig. 2.11** Perovic's technique. The urethral flap is embedded into the skin tube and sutured

the pedicle hole, is embedded into the skin tube and sutured (Fig. 2.11). The bottom of the tube is closed with the distal part of the urethra and/or the remaining ventral half of the glans cap after the de-epithelialization of its inner side, as previously described. The tube, consisting of the skin and urethral flap, is then inverted thereby forming the

neovagina. If there is insufficient penile skin, the short skin tube and long urethral flap will not be in proportion. The vagina can then be formed in two ways. The proximal part at the base of the vagina is formed only by the urethral flap, which initiates secondary epithelialization. If the tube pedicle is too short to place the tube into the perineal cavity, the neovagina is created using the vascularized urethral flap and free penile skin grafts. In this case the vascularized urethral flap plays a key role in creating the new vagina. The space for the allocation of the neovagina is created in the perineum as has been described for the other techniques. The modified Stamey procedure is used to fix the neovagina within the perineal cavity. Two 15° angled Stamey needles penetrate through the rectus to the left and right of the midline at the upper border of the pubic symphysis. The needles then enter laterally into the neocavity from the bladder neck. In the empty bladder the Foley catheter balloon, which is easily palpable, enables the determination of the exact location of the bladder neck. A polypropylene U suture (0-0) in the middle lateral part of the neovagina is threaded through the eye of the needle, and the needle is withdrawn suprapubically. Both ends of the suture are pulled out of the skin of the prepubic area and knotted over bolsters under mild tension, so as to avoid necrosis of the penile flap where the sutures penetrate its wall. At this point the neovagina is placed deep in the perineal cavity. The next step consists of a vulvoplasty. The labia minora are formed by the remaining parts of the base of the penile skin which are sutured to the de-epithelialized area of the neoclitoris. The labia majora are created by the refinement of the original scrotal skin. A perivaginal Jackson-Pratt drain is left for 3 days. The urethral catheter and vaginal packing (a condom filled with soft material) are removed 7 days after surgery (Perovic et al. 2000).

## 2.9 Enterovaginoplasty

Enterovaginoplasty is a widely used technique in patients affected with vaginal aplasia caused by Mayer-Rokitansky-Kuster-Hauser syndrome but which can also be used in transsexual patients.

The advantages of using this technique is the possibility of creating a neovagina of sufficient length and appearance that is similar to a natural vagina. Additionally, it is the only method that provides a vaginal lining with natural lubrication. This technique is the best choice for transsexual patients who had previously undergone a penectomy and orchidectomy as well as for patients with dissatisfactory vaginoplasty results.

### 2.9.1 Ileal Vaginoplasty

To create a neovagina from the ileum, the patient is put under general anesthesia and positioned in a supine lithotomic position in order to achieve a good intra-abdominal exposure as well as gain wide access to the perineum and introitus. A simultaneous abdominal perineal approach is used. A midline or Pfannenstiel approach is then performed, and the pouch of Douglas is accessed. A Hegar sound is inserted into the distal vaginal segment, and the peritoneal reflection is opened. The vaginal vault is then isolated and completely mobilized. When performed after prior surgery, this step of the operation is generally very difficult due to scars and fibrosis that obliterate the natural tissue planes. By way of a blunt dissection, a surgical plane is developed between the urethra and rectum. Careful attention must be paid to prevent damage to the surface of the rectum and the urethra. It is important to create a large enough space for the bowel segment to fit easily and to enable mobilization of the vaginal vault to allow a capacious, well-vascularized and tension-free anastomosis. The ileum is then extracted, and an ileal loop which more easily reaches the pelvis is formed at about 20 cm from the ileocecal valve. Vascularization of the loop is preserved using the standard transillumination technique. In most patients there is a normal distal vaginal segment that can be used for anastomosis to the bowel segment. In these cases a 12 cm segment is isolated, and intestinal transit is reestablished. The isolated segment is detubularized and transversally retubularized in order to configure the roof of the neovagina. The proximal end of the

conduit is closed with two layers of absorbable suture material. In patients with an inadequate distal vagina, the bowel segment must be longer in order to be anastomosed directly to the perineum. In such cases, two adjacent segments of 12 cm long ileum are isolated. Each segment is detubularized, and the resulting flaps are attached and retubularized transversally. In this way a 10–12 cm length tube with two long branches separated by two insertions of mesentery is created. The ileal segment is brought to the perineum with as little tension as possible in order to allow for a tension-free anastomosis. Ileo-cutaneous anastomoses with interrupted absorbable sutures (Monocryl 3-0) are then performed using a perineal approach. The laparoscopically assisted techniques are successfully used for isolation and mobilization of the vaginal vault, mobilization of the ileal segment, and to assist the vaginal anastomosis. An inflatable silicon vaginal tutor is then introduced into the vaginal cavity and is maintained all day long for 7 days. The catheter is removed after 5 days. It is important to avoid washing the neovagina with substances that can damage or irritate the ileum, and therefore sterile saline solution is recommended in the first postoperative month.

### 2.9.2 Rectosigmoidal Vaginoplasty

This operation can be performed with the help of a general surgeon. The general surgery team isolates the rectosigmoid intestinal flap, while the urologists create the vaginal cavity by dissecting the area between the penis and rectum. The blood supply of the rectosigmoid intestinal flap emanates from the superior hemorrhoidal artery from the inferior mesenteric artery. Innervation of the flap was from the autonomic system, with sympathetic (inferior mesenteric and hypogastric nerve) and parasympathetic components (hypogastric plexus). When isolating the rectosigmoid intestinal flap, an 8–12 cm length of rectosigmoid is resected, keeping the superior hemorrhoidal artery and then performing an end-to-side anastomosis

between the remaining sigmoid colon and rectum using an intraluminal stapler. The proximal portion of the rectosigmoid flap was closed with 3-0 Vicryl sutures. In patients with the penis and scrotum intact, a penectomy and orchiectomy is executed, and a urethral opening is constructed at the proper site. A clitoroplasty using the penile glans is performed in patients who desire a clitoris; however, for patients who do not want a constructed clitoris as it is usually unsatisfactory due to its deformity, the remaining distal penile crura are sutured to each other and then attached to the anterior portion of the urethral orifice in substitution of a clitoris. This procedure offers patients excellent sexual sensitivity. The bulbospongiosus muscle is stripped of the bulky urethral portion and is used to augment the new labia majora. In the orchiectomy, the testes and epididymis are removed but the spermatic cord and surrounding tissue are preserved to provide sufficient volume in the labia majora. For the penectomy patients, a vaginal cavity is made by incising the transversus perinei superficialis muscle and fibrous connections. Bundles of puborectalis and rectovesical muscles must be cut to create a cavity of sufficient size. After complete blunt dissection of the Denonvilliers fascia (septum rectovesicale), the prepared rectosigmoid flap is transferred to the new vaginal cavity through the peritoneal opening of the peritoneal reflex region. The end of the rectosigmoid flap is then sutured to the skin of the new vaginal orifice. One or two Silastic drains are placed inside the new vaginal wall through the vaginal orifice, and a suction drain is inserted in the abdominal cavity. A sponge packing is inserted into the new vaginal cavity for a tight approximation of the rectosigmoid flap and the surrounding tissue (Trombetta et al. 2005).

---

### 2.10 Neovaginal Expanding Devices

The neocavity which is created in the perineal space among the rectum, the membranous urethra, and the anterior section of the prostate



**Fig. 2.12** Expanding device constituted of a polyurethane foam body wrapped with an expanding silicone cylinder which may expand under atmospheric pressure

should be dilated and sustained by the introduction of an expanding device which often remains in place for many months after the operation. Usually these devices are constituted of a polyurethane foam body wrapped with an expanding silicone cylinder which may expand under atmospheric pressure (Fig. 2.12). A cylindrical shape with round edges is needed in order to avoid excessive compression in specific points and to ensure a uniform distribution of the forces. The volume of the device is regulated by an opening valve which ensures enough constant pressure to avoid contractions or stenosis. It is possible to drain eventual secretions and conduct washings through the central tube with sterile solutions in the postoperative care. The size of the device can vary from 3 to 5 cm in diameter and from 9.5 to 16 cm in length. The choice of a suitable size of the expanding device is crucial in allowing easy insertion and avoiding difficult removal.

## 2.11 Complications

Vaginoplasty surgical complications are common in all the techniques described above. All potential complications can be divided into intraoperative complications, short-term postoperative complications, long-term postoperative complications, and inhesterism (Table 2.3).

**Table 2.3** Complications of vaginoplasty

Intraoperative complications	Rectal injuries Neurovascular bundle injuries
Short-term postoperative complications	Urethral perimeatal bleeding Neovagina-rectal fistula Penile or scrotal cutaneous cylinder necrosis Neoclitoris necrosis Vaginal abscess Wound infection
Long-term postoperative complications	Neovaginal stenosis Aditus Deep Neovaginal prolapse Urethral meatus stenosis Type 3 stress incontinence
Inhesterisms	Scrotiform aspect of main labia Neoclitoris hypertrophy Persistence of an exuberant fragment of corpus cavernosum Maintenance of bulbar urethra Superior or posterior neolabial commissural inhesterisms

## References

- Belgrano E, Fabris B, Trombetta C (1999) *Il Transsessualismo. Identificazione di un percorso diagnostico e terapeutico*. Editrice Kurtis, Milano
- Cohen-Kettenis PT, Gooren LJG (1999) Transsexualism: a review of etiology, diagnosis and treatment. *J Psychosom Res* 46(4):315–333
- American Psychiatric Association (2000) *Diagnostic and statistical manual of mental disorders*, 4th edn, text rev. doi: [10.1176/appi.books.9780890423349](https://doi.org/10.1176/appi.books.9780890423349)
- Glenn JF (1980) One stage operation for male transsexuals. *J Urol* 123:396–398
- Meyer WIII, Bockting W, Cohen-Kettenis PT, Coleman E, Di Ceglie D, Devor H et al (2001) The standards of care for gender identity disorders – sixth version. [http://www.symposium.com/ijt/soc\\_2001/index.htm](http://www.symposium.com/ijt/soc_2001/index.htm). Feb 2001
- Michel A, Mormont C, Legros JJ (2001) A psychoendocrinological overview of transsexualism. *Eur J Endocrinol* 145:365–376



- Perovic SV, Stanojevic DS, Djordjevic MLJ (2000) Vaginoplasty in male transsexuals using penile skin and a urethral flap. *BJU Int* 86:843–850
- Ravenna AR (1998) Gender identity disorder (DSM IV 302.85) ratified by the “Osservatorio Nazionale sull’Identità di Genere – ONIG” in June 1998. *IJT* 2,4. <http://www.symposion.com/ijt/ijtc0602.htm>
- Small MP (1987) Penile and scrotal inversion vaginoplasty for male to female transsexuals. *Urology* 22(6):593–597
- Trombetta C, Liguoria G, Siracusano S, Bortul M, Belgrano E (2005) Transverse retubularized ileal vaginoplasty: a new application of the Monti principle – preliminary report. *Eur Urol* 48:1018–1024

Clinical Uro-Andrology

Mirone, V. (Ed.)

2015, VI, 291 p. 38 illus., 32 illus. in color., Hardcover

ISBN: 978-3-662-45017-8