

# HER2 testing

Mary Falzon, Michael Gandy

## Introduction

The human epidermal growth factor receptor 2 (HER2) *ERBB2* gene has been at the forefront of the therapeutic management of breast cancer since 1998, following the US Food and Drug Administration (FDA) approval of trastuzumab. This drug was initially introduced into clinical practice for patients with metastatic breast cancer, and then subsequently used in patients with early-stage primary disease [1]. Positive confirmation of HER2 status, in conjunction with the wider clinicopathologic characteristics of the patient and their disease, now determines eligibility for treatment with a range of HER2-targeted therapies.

The HER2 protein, a receptor tyrosine kinase molecule, spans the cell membrane with an N-terminus extracellular domain, transmembrane region, and nuclear carboxy-terminal fragments [2]. It is encoded for by the *HER2* gene located on the long arm of chromosome 17 at position 17q21 [3]. The normal function of HER2 is associated with cellular processes of differentiation, growth, development, and apoptosis via activation of tyrosine kinase activity through dimerization of HER2, with itself and other members of the epidermal growth factor receptor family [2]. Approximately 15% of patients with breast cancer overexpress the HER2 protein or show amplification of the gene [4]. It is this constituent link between gene amplification and protein overexpression, and the availability of the HER2 extracellular domain as a target for humanized monoclonal antibody-based therapies, which has driven the HER2 therapeutic and testing rationale.

The assessment of HER2 in clinical practice commonly takes place within a histopathology laboratory, and both the histopathology processes

and the specialist area of HER2 testing are governed by regional regulatory bodies (eg, US College of American Pathologists HER2 proficiency programs; UK National External Quality Assessment Scheme for HER2). In 2007, the American Society of Clinical Oncology (ASCO) and the College of American Pathologists (CAP) defined the histologic phases which span the HER2 testing process as pre-analytic (sample handling [fixation and tissue processing]), analytic (testing), and post-analytic (interpretation) [1]. Of note, the ASCO/CAP recommendations for HER2 testing guidelines were updated in 2014 [5,6].

## Pre-analytic phase: sample handling

HER2 assessment in breast cancer can be made using a variety of sample types, including primary core biopsies, resection specimens, and metastatic biopsies. On the rare occasion when no histological material is available, cytology cell blocks may be utilized. The HER2 protein in each of these sample types is subject to the stresses associated with histopathologic processing. The critical steps in the process include:

- *Cold ischemic time*: time taken from removal of the sample from the patient to fixing of the sample in an appropriate fixative (10% neutral buffered formalin) [1,7, 8]. Prolonged cold ischemic times can result in degradation of the HER2 protein and other cellular structures [9].
- *Fixation*: stabilization of tissue structures and genetic material in preparation for tissue processing [10]. A fixation time of 6–72 hours is recommended for breast cancer samples, depending on size and type of the sample [1,5].
- *Tissue processing*: complete dehydration, clearing, and paraffin embedding of the tissue sample in preparation for sectioning [1,8].
- *Slide preparation*: tissue sectioning at 3–4  $\mu\text{m}$  and adherence on to charged microscope slides via incubation of the slide at 37°C overnight (or 60°C for 1 hour) in preparation for staining [8]. Prolonged storage of cut paraffin sections can result in antigen degradation [1].

Since the introduction of guidance in the pre-analytic phase for clinical practice, there has been a concerted development towards a more standardized approach to assessment of HER2 status across testing [1,6,11,12].

## Analytic phase: HER2 testing methodologies

### Pathologic assessment

Breast cancer is not one disease, but many different diseases. Even when tumors are classified together based on their morphology, they can act differently because of different genetic makeups. HER2-positive breast cancer is one form and is characterized by aggressive growth and a poor prognosis; it is caused by the overexpression or amplification of the HER2 gene in tumor cells [1]. In approximately 15% of women with breast cancer, there is a genetic alteration in the HER2 gene that produces an increased amount of the growth factor receptor protein on the tumor cell surface [4]. A recent study also found a 14.9% rate of HER2 overexpression in men with breast cancer [13]; however, due to the low incidence of male breast cancer and variability of HER2 testing clinically in this demographic, further and wider studies to determine HER2 positivity rates in this setting are required.

In the UK, routine testing for HER2 is recommended for all patients diagnosed with invasive breast cancer because the results may affect treatment recommendations and care plan decisions [6,11]. All types of epithelial-derived invasive primary breast cancers should be tested at diagnosis for HER2 status by immunohistochemistry (IHC) in the first instance [14]. HER2 testing is not currently performed routinely for ductal carcinoma in situ [6,11].

Whenever breast cancer recurs or metastasizes, the tumor should be retested for HER2 as well as for hormone receptor (ie, estrogen receptor [ER] and progesterone receptor [PR]) status, as these change from the original primary cancer in up to 20–30% of cases [15]. In patients with metastatic breast cancer, accurate determination of HER2 status is critical for guiding treatment decisions. The National Comprehensive Cancer Network (NCCN) guidelines recommend HER2 testing at relapse, particularly if HER2 expression was originally unknown or negative [14].

### Clinical testing methodologies

In the UK, laboratories undertaking HER2 testing should have Clinical Pathology Accreditation, participate in the recognized national external quality assessment scheme, and carry out a formal annual audit of its testing services [6,11,12]. It is recommended that testing is restricted to laboratories undertaking

a minimum of 250 tests per annum for IHC and 100 tests per annum for in situ hybridization (ISH) techniques [6,11]. A similar level of accreditation and safety audits should be adhered to in all regions where possible.

Within the analytic phase, a number of testing methods have been developed. However, IHC and ISH remain the predominant methods used to assess HER2 status in the clinical setting [6,11]. These target the HER2 protein and gene, respectively, and are clinically validated, commercially available, and subject to regional regulatory clearance and control (eg, FDA) [1,16,17]. It has been shown via external quality assessment that the introduction of standardized and validated companion diagnostic assays have improved the quality of clinical HER2 testing. Examples of these include the Dako HercepTest (Dako Denmark A/S, Glostrup, Denmark) and Abbott PathVysion assays, co-approved on first approval of trastuzumab, and the widely used Ventana Pathway HER2 4B5 and DDISH assays (Ventana Medical Systems, Inc, Tucson, Arizona, USA), which have helped standardize HER2 testing in conjunction with fully automated laboratory instrumentation [1,2,16–18].

Within the laboratory, irrespective of which assay is used, testing is controlled by a mix of analyte control standards, which often come in the form of commercially available breast cancer cell lines or xenografts [1]. These are a constituent part of the diagnostic assays and, via locally prepared laboratory-specific tissue control slides, demonstrate each of the four HER2 pathologic scoring criteria (described below) on the individual laboratories' own prepared histologic material. Where possible, the use of a same-slide “control + test” is now seen as the gold standard in slide-based biomarker testing, controlling for individual slide positions on fully automated staining platforms. Internal structural controls with the test sample can also help guide assessment, with benign breast ducts showing little or no overexpression with IHC and expressing normal HER2:CEP17 gene ratios with ISH [1].

## **Post-analytic phase: screening and interpretation**

### **Immunohistochemistry**

The use of IHC in HER2 assessment requires input and governance by a specialist breast pathologist. The first stage of all HER2 assessments is to ensure that invasive breast carcinoma is being screened for, rather than carcinoma in situ. The sample is then tested for HER2. All regulatory-cleared IHC assays target the intercellular domain of the HER2 protein. Although extracellular or

external domain monoclonal antibodies exist and are readily available for use in IHC assays, none have been officially approved for use in clinical practice.

The scoring of HER2 IHC utilizes 4 distinct grades: 0, 1+, 2+ and 3+ (Figure 2.1). Screening is based on percentage of invasive tumor cell staining, the completeness of the circumferential staining, and the intensity of the stain [19]. It is recognized that each tumor when viewed microscopically is a single ‘snapshot in time’ of its activity and is representative of a much larger three-dimensional biologically active structure.

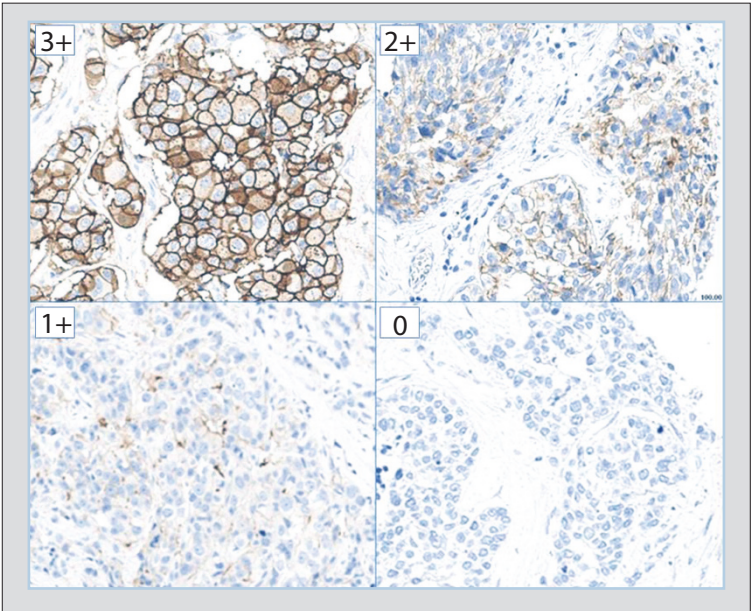
Immunohistochemistry interpretation determines if patients are suitable for HER2-targeted therapy (positive, 3+) or not (negative, 0–1+). There is also an equivocal category (2+) to identify patients who require further confirmatory testing and analysis (Table 2.1) [5,6,11]. This second-line testing component of the clinical HER2 testing algorithm utilizes ISH methods to examine the HER2 gene and classifies patients for treatment purposes. When samples are handled correctly in the pre-analytic phase and IHC testing is performed correctly, HER2 IHC staining can be localized to the cell membrane and can be accurately interpreted, as illustrated in Figure 2.1.

Reported variations in IHC screening results may be due to subtle differences between different assays (eg, epitope binding site, detection system sensitivity, sample heterogeneity, laboratory protocol, and pathologist/screener interobserver variation). Also, compromising the pre-analytic processes can often result in diffuse or granular IHC staining, which can be difficult to interpret. Despite all of these factors, IHC has proven to be an accurate, robust, and cost-effective method for assessing patients’ HER2 status.

In recent times, difficult-to-interpret cases, or those that are suspected of having undergone suboptimal pre-analytic factors, are also referred for ISH testing. This may be to help clarify unique expression patterns as a result of heterogeneity or cases where tissue protein is damaged.

## **In situ hybridization screening**

In situ hybridization screening methods (eg, fluorescence, chromogenic, or silver-based techniques) are all variations based on the same core ISH technology [1]. Utilizing either fluorophore- or hapten-labeled probes that are complementary to regions of the HER2 gene and chromosome 17, ISH screening tests microscopically visualize HER2 and chromosome 17 [6,11]. Standard



**Figure 2.1 Immunohistochemical staining for HER2-positive breast cancer.** This figure illustrates the 4 distinct immunohistochemical grades: 0, 1+, 2+, 3+.

Score to report	HER2 protein overexpression in assessment	Staining pattern
0	Negative	No staining observed or membrane staining that is incomplete and is faint/barely perceptible and within 10% of the invasive tumor cells
1+	Negative	Incomplete membrane staining that is faint/barely perceptible and within >10% of the invasive tumor cells
2+	Weakly positive* (equivocal)	Circumferential membrane staining that is incomplete and/or weak/moderate and within >10% of the invasive tumor cells or complete and circumferential membrane staining that is intense and within ≤10% of the invasive tumor cells
3+	Strongly positive**	Circumferential membrane staining that is complete, intense and within >10% of tumor cells

**Table 2.1 Recommended immunohistochemical scoring method.** \*Weakly positive cases (2+): may be considered equivocal and reflexed to ISH testing. \*\*Strongly positive cases (3+): based on recent testing guidelines, a 10% cut-off is recommended. FDA-approved scoring guidelines recommend a 10% cut-off for reporting positivity. Adapted with permission from Wolff et al [5] ©College of American Pathologists.

practice includes assessing the HER2 and centromeric probe for chromosome 17 (CEP17) signals in 20–60 tumor nuclei to determine the average HER2 and CEP17 copy numbers per cell, followed by calculating the HER2:CEP17 gene ratio. Cases are then reported as [6,11]:

- non-amplified negative ( $<1.80$ );
- borderline non-amplified negative ( $1.80$ – $1.99$ );
- borderline amplified positive ( $2.00$ – $2.20$ );
- amplified positive ( $>2.20$ ); or
- HER2 gene copy number  $\geq 6$  may be considered positive if a single HER2 gene assessment method is employed.

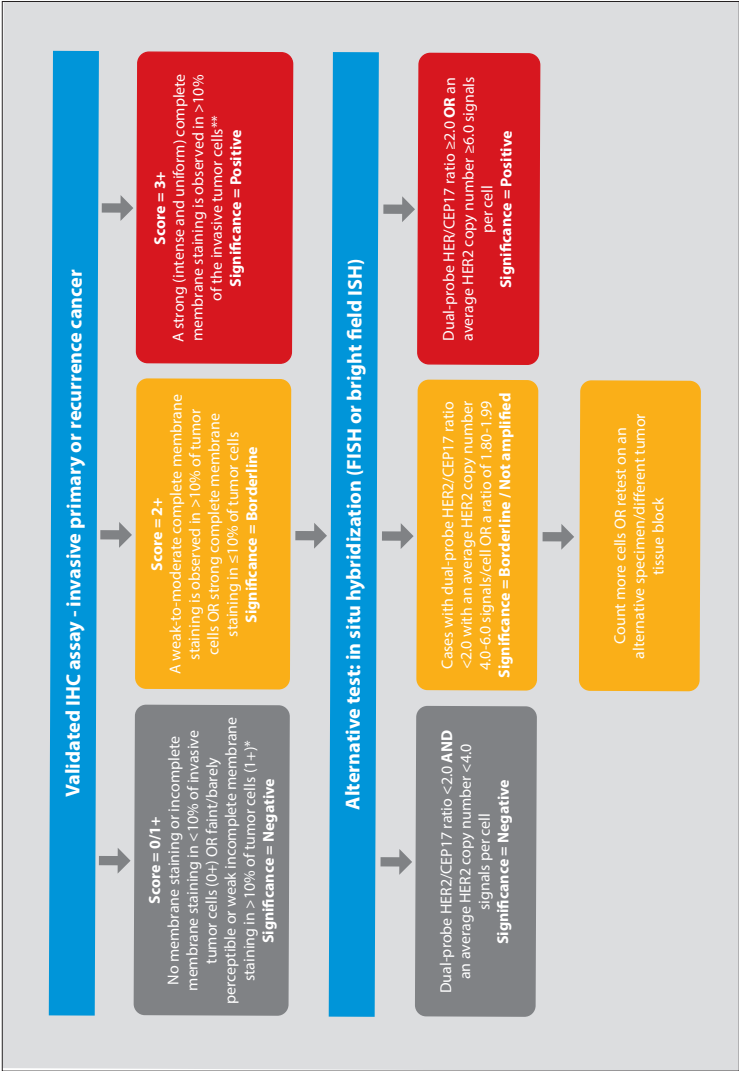
For cases which fall in the borderline region, a second review with additional cells (20–40) is performed. An overall result is then reported, with the definitive HER2:CEP17 gene ratio cut-off defined as  $\geq 2.00$  (Figure 2.2) [1,6,11].

## Testing in context

The review of HER2 expression, alongside ER and PR status, can aid in the treatment decision-making process due to the (broadly speaking) inverse relationship between HER2 and ER/PR expression. For cases where distinguishing in situ from invasive breast cancer is necessary, additional stains and markers such as cytokeratin 5 can be invaluable [1]. To facilitate accurate quantification, it is useful if these markers are available for review at the time of HER2 protein and gene expression testing. The availability of the HER2 IHC-stained slide for ISH screening provides reviewers with the ability to define genuine areas of amplification associated with focal overexpression and report it accordingly.

## Heterogeneity

Although it is not the predominant biologic pattern, intratumoral heterogeneity of the HER2 gene and its encoded protein may be observed. Intratumoral heterogeneity can be genuine and related specifically to clonal tumor cell populations within the mass, or it may have been introduced as an artifact through suboptimal sample handling at the pre-analytic stage [20]. Cases which present with bilateral carcinoma, if morphologically different, should be considered as individual tumor entities and tested and reported as such using standard HER2 reporting criteria.



**Figure 2.2 Recommended HER2 scoring algorithm for immunohistochemistry (IHC) and in situ hybridization (ISH).** \*Insufficient data are available to comment on moderate complete membrane staining in ≤10% of tumor cells or strong incomplete membrane staining in >10% of tumor cells. A repeat on another specimen/tissue block is advisable. \*\*Membrane staining must be intense and uniform and resemble chicken-wire. Ignore incomplete or pale membrane staining in the percentage estimation. Reproduced with permission from Rakha et al [6] ©BMJ.



Intratumoral heterogeneity should be formerly documented on the report including any potential correlations between morphological, immunohistochemical, and in situ patterns. Cases involving both simple and complex heterogeneity patterns should be discussed within the context of multidisciplinary team meetings with the aim of correlating heterogeneous findings. Where possible, retesting on an alternate tissue block may prove useful.

### **Polysomy and co-amplification**

Polysomy of CEP17 is when there is, on average,  $\geq 3$  signals or copies of the CEP17 probe per cell [1]. Cases which have high levels of both HER2 and CEP17 have been traditionally classified as negative for treatment purposes based on a resultant negative HER2:CEP17 gene ratio ( $<2.00$ ) [6,11]. This topic remains an area of interest for researchers and clinicians, with ongoing investigations into the clinical significance of gene ratio versus single copy number, with a recent suggestion that cases with HER2 gene copy number  $\geq 6$  should be considered for treatment [5–7].

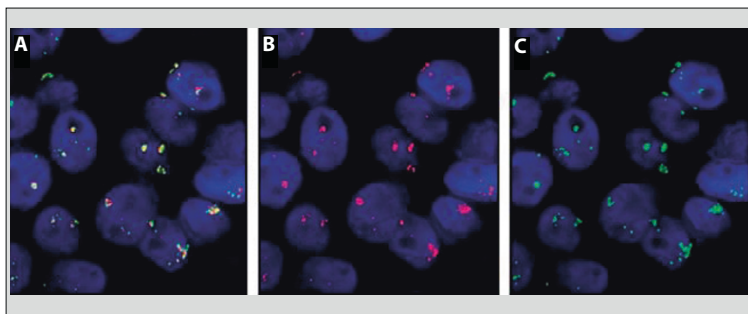
Distinctly different from polysomy, signal co-localization or co-amplification is described when the HER2 and CEP17 probes microscopically co-occupy spatially close regions on the chromosome, leading to an increase in the copy number of both HER2 and CEP17 signals. It is suggested that this observation may be due to the extension of the HER2 amplicon into the pericentromeric region of chromosome 17; in co-amplification, both the HER2 gene and this extension into the centromere visibly co-amplify [21]. This genotype has a distinct profile under fluorescence examination, producing an intense yellow ‘fusion-like’ color as a result of a color-merging of HER2 (red) and CEP17 (green) signals [21]; this pattern is more difficult to detect using chromogenic ISH methods due to lack of fluorescent color merging. Research recommendations suggest that these unusual and rare cases should be interpreted with caution, but patients may still be considered eligible for trastuzumab treatment (Figure 2.3) [21].

In order to help further accurately categorize gene amplification status, a number of models have been presented, such as those developed by Tse et al [22] and Mansfield et al [23] which utilize alternative markers to assess chromosome 17. Although in clinical practice there are few cases of gene co-amplification,

the Mansfield dual ISH model utilizes an alternative noncentromeric CEP (D17S122 locus [17p12]) in conjunction with the HER2 probe to provide a way of determining if co-amplification is due to specific pericentromeric extension of HER2 and not polysomy of chromosome 17 [23].

Alternatively, methods such as multiplex ligation-dependent probe amplification may prove useful [24]. However, as with other nonmorphologic-based methods, there is an inherent risk of viewing the result out of its pathologic context. A consensus on how these cases are handled clinically has not yet been defined. Both local and international breast cancer guidelines should be periodically reviewed, as they provide direction as to test interpretation based on current scientific and clinical data.

Recent research recommendations from the UK National External Quality Assessment Service for these challenging and infrequently seen cases suggest that they should be reported as amplified, with co-amplification of the centromere based on the HER2 copy number and associated balanced CEP17 copy number. Co-localization of the HER2 and CEP17 signals should also be indicated, with further genetic investigations performed to clarify the genetic profile [21]. The alternative chromosome 17 marker may be useful in defining the observations of both polysomy and co-amplification, both of which are currently reported and interpreted with an element of uncertainty.



**Figure 2.3 Co-localization of HER2 and CEP17 signals.** (A) Co-localization of HER2 and CEP17 signals is represented in this figure by a yellow fusion signal. This differs from the independent (B) HER2 and (C) CEP17 signals. Reproduced with permission from Starczynski et al [21]

©American Society for Clinical Pathology.

## Alternate HER2 testing methodologies

Although IHC and ISH methods are by far the most widely used methods in clinical practice, others can be used to augment clinical testing and for research investigations.

### Serum HER2 monitoring

The monitoring of serum HER2 relies on the detection of the soluble shed HER2 p95 extracellular domain (ECD) [25]. The cleavage of the ECD to produce shed HER2 p95 occurs through interactions of the HER2 molecule with biologically active proteolytic enzymes present in the extracellular matrix [25,26]. Using an enzyme-linked immunosorbant assay, this method has mostly been used in research and trial settings in an attempt to monitor patient performance with HER2-targeted therapies (via association with concentration of shed extracellular domain). However, a recent comprehensive review by Leyland-Jones and Smith looked at over 60 independent investigations and concluded that, based on inconsistent data, HER2 ECD analysis should not be used for patient management purposes and clinicians should instead follow standard clinical parameters and national guidelines [25].

### Quantitative reverse transcription polymerase chain reaction methods

Quantitative reverse transcription polymerase chain reaction (PCR) methods for determining amplification of the HER2 gene have been shown to produce results similar to those seen with ISH [27]. However, the main area of concern which has prevented these assays from widespread adoption in clinical practice is that they rely on either micro- or macro-dissection of the tumor and normalization of background HER2 [28]. This can prove difficult in cases with mixed in situ and invasive components, or impossible when assessing areas of microinvasion which cannot be dissected. Thus, various PCR-based methods have shown discordant results [29]. The ability to review amplification or overexpression in a morphologic context still remains a key element to accurately assessing HER2 status.

## HER2 somatic mutation analysis

As previously discussed, clinical analysis of the HER2 gene and its resultant protein has focused primarily on the genetic abnormalities of gene amplification, copy number variation, and resultant protein overexpression. The completion of the human genome project and the evolution of sequencing technology to accurately characterize mutations in the HER2 gene has led to HER2 genetic alterations as a rapidly developing area of interest. Current research suggests the need to include analyses of somatic HER2 mutations in clinical trials of HER2-targeted compounds [30], as well as for compounds which affect pathways that HER2 is a constituent part of.

## References

- 1 Wolff AC, Hammond MEH, Schwartz JN, et al. American Society of Clinical Oncology/College of American Pathologists guideline recommendations for human epidermal growth factor receptor 2 testing in breast cancer. *J Clin Oncol*. 2007;25:118-145.
- 2 Pedersen K, Angelini P-D, Laos S, et al. A naturally occurring HER2 carboxy-terminal fragment promotes mammary tumor growth and metastasis. *Mol Cell Biol*. 2009;29:3319-3331.
- 3 Negri T, Tarantino E, Orsenigo M, et al. Chromosome band 17q21 in breast cancer: significant association between *beclin 1* loss and *HER2/NEU* amplification. *Genes Chromosomes Cancer*. 2010;49:901-909.
- 4 Pinhel I, Hills M, Drury S, et al; for the NCRI Adjuvant Breast Cancer Trial Management Group. ER and HER2 expression are positively correlated in HER2 non-overexpressing breast cancer. *Breast Cancer Res*. 2012;14:R46.
- 5 Wolff AC, Hammond ME, Hicks DG, et al. Recommendations for human epidermal growth factor receptor 2 testing in breast cancer: American Society of Clinical Oncology/College of American Pathologists clinical practice guideline update. *J Clin Oncol*. 2013;31:3997-4013.
- 6 Rahka EA, Pinder SE, Bartlett JMS, et al. Updated UK recommendations for HER2 assessment in breast cancer. *J Clin Pathol*. 2014;0:1-7.
- 7 Hammond MEH, Hayes DF, Dowsett M, et al. American Society of Clinical Oncology/College of American Pathologists guideline recommendations for immunohistochemical testing of estrogen and progesterone receptors in breast cancer (unabridged version). *Arch Pathol Lab Med*. 2010;134:e48-e72.
- 8 Müller S, Matthiesen SH, Nielsen KV. Preparation of FFPE tissue slides for solid tumor FISH analysis. In: Kumar GL, Rudbeck L, eds. *Education Guide: Immunohistochemical Staining Methods*. 5th edition. Carpinteria, CA: Dako North America; 2009:67-73.
- 9 Yildiz-Aktas IZ, Dabbs DJ, Bhargava R. The effect of cold ischemic time on the immunohistochemical evaluation of estrogen receptor, progesterone receptor, and HER2 expression in invasive breast carcinoma. *Mod Pathol*. 2012;25:1098-1105.
- 10 Farmilo AJ, Stead RH. Fixation and processing. In: Kumar GL, Rudbeck L, eds. *Education Guide: Immunohistochemical Staining Methods*. 5th edition. Carpinteria, CA: Dako North America; 2009:29-33.
- 11 Walker RA, Bartlett JMS, Dowsett M, et al. HER2 testing in the UK: further update to recommendations. *J Clin Pathol*. 2008;61:818-824.

- 12 Bartlett JMS, Starczynski J, Atkey N, et al. HER2 testing in the UK: recommendations for breast and gastric in-situ hybridisation methods. *J Clin Pathol*. 2011;64:649-653.
- 13 Chavez-MacGregor M, Clarke CA, Lichtensztajn D, Hortobagyi GN, Giordano SH. Male breast cancer according to tumor subtype and race: a population-based study. *Cancer*. 2013;119:1611-1617.
- 14 National Comprehensive Cancer Network (NCCN) Clinical Practice Guidelines in Oncology. Breast Cancer. Version 3.2013. NCCN website. [www.nccn.org/professionals/physician\\_gls/pdf/breast.pdf](http://www.nccn.org/professionals/physician_gls/pdf/breast.pdf). Accessed November 3, 2015.
- 15 Lindström LS, Karlsson E, Wilking UM, et al. Clinically used breast cancer markers such as estrogen receptor, progesterone receptor, and human epidermal growth factor receptor 2 are unstable throughout tumor progression. *J Clin Oncol*. 2012;30:2601-2608.
- 16 Guidelines for Scoring Herceptest. Dako website. [www.dako.com/38602\\_19feb10\\_herceptest\\_scoring\\_guidelines-breast\\_ihc.pdf](http://www.dako.com/38602_19feb10_herceptest_scoring_guidelines-breast_ihc.pdf). Accessed November 3, 2015.
- 17 PathVysion Product Probe Description. Abbott Molecular website. [www.abbottmolecular.com/us/products/oncology/fish/breast-cancer-pathvysion-her2.html](http://www.abbottmolecular.com/us/products/oncology/fish/breast-cancer-pathvysion-her2.html). Accessed November 3, 2015.
- 18 Herceptin (trastuzumab) development timeline. Genentech website. [www.gene.com/media/product-information/herceptin-development-timeline](http://www.gene.com/media/product-information/herceptin-development-timeline). Accessed November 3, 2015.
- 19 Leong AS-Y, Formby M, Haffajee Z, Clarke M, Morey A. Refinement of immunohistologic parameters for Her2/neu scoring validation by FISH and CISH. *Appl Immunohistochem Mol Morphol*. 2006;14:384-389.
- 20 Seol H, Lee HJ, Choi Y, et al. Intratumoral heterogeneity of *HER2* gene amplification in breast cancer: its clinicopathological significance. *Mod Pathol*. 2012;25:938-948.
- 21 Starczynski J, Atkey N, Connelly Y, et al. *HER2* gene amplification in breast cancer: a rogues' gallery of challenging diagnostic cases: UKNEQAS interpretation guidelines and research recommendations. *Am J Clin Pathol*. 2012;137:595-605.
- 22 Tse CH, Hwang HC, Goldstein LC, et al. Determining true *HER2* gene status in breast cancers with polysomy by using alternative chromosome 17 reference genes: implications for anti-*HER2* targeted therapy. *J Clin Oncol*. 2011;29:4168-4174.
- 23 Mansfield AS, Sukov WR, Eckel-Passow JE, et al. Comparison of fluorescence in situ hybridization (FISH) and dual-ISH (DISH) in the determination of *HER2* status in breast cancer. *Am J Clin Pathol*. 2013;139:144-150.
- 24 Bravaccini S, Rengucci C, Medri L, Zoli W, Silvestrini R, Amadori D. Detection of *HER2* and *Topo 2* in breast cancers: comparison between MLPA and FISH approaches. *J Clin Pathol*. 2012;65:183-185.
- 25 Leyland-Jones B, Smith BR. Serum *HER2* testing in patients with *HER2*-positive breast cancer: the death knell tolls. *Lancet Oncol*. 2011;12:286-295.
- 26 Molina MA, Codony-Servat J, Albanell J, Rojo F, Arribas J, Baselga J. Trastuzumab (Herceptin), a humanized anti-*HER2* receptor monoclonal antibody, inhibits basal and activated *HER2* ectodomain cleavage in breast cancer cells. *Cancer Res*. 2001;61:4744-4749.
- 27 Jacquemier J, Spyrtas F, Esterni B, et al. SISH/CISH or qPCR as alternative techniques to FISH for determination of *HER2* amplification status on breast tumors core needle biopsies: a multicenter experience based on 840 cases. *BMC Cancer*. 2013;13:351.
- 28 Millson A, Suli A, Hartung L, et al. Comparison of two quantitative polymerase chain reaction methods for detecting *HER2/neu* amplification. *J Mol Diagn*. 2003;5:184-190.
- 29 Dabbs DJ, Klein ME, Mohsin SK, Tubbs RR, Shuai Y, Bhargava R. High false-negative rate of *HER2* quantitative reverse transcription polymerase chain reaction of the Oncotype DX test: an independent quality assurance study. *J Clin Oncol*. 2011;29:4279-4285.
- 30 Bose R, Kavuri SM, Searleman AC, et al. Activating *HER2* mutations in *HER2* gene amplification negative breast cancer. *Cancer Discov*. 2013;3:224-237.

Handbook of HER2-Targeted Agents in Breast Cancer

Alvarez, R.H.; Cortés, J.; Falzon, M.; Gandy, M.; Gianni, L.;  
Harbeck, N.; Piccart, M.

2016, XI, 110 p. 17 illus., 16 illus. in color., Softcover

ISBN: 978-3-319-28214-5