

Chapter 2

Evolution of Operative Methods in Japan

Tadashi Ikeda

2.1 Evolution of Operative Methods in Japan

The first operation for a breast cancer patient was performed in the early nineteenth century in Wakayama (1804.11.14), Japan. This operation was performed by Seishu Hanaoka, a Japanese doctor, using general anesthesia [1]. The general anesthetic agent used was called Tsusen-san, which was an extract of *Datura metel*. This might have been the first breast cancer operation under general anesthesia in the world. After that, no further descriptions of the operative method for breast cancer patients were given in Japan.

The trends in the operative method for breast cancer in the modern era are about the same in Japan as in Western countries, but in Japan, the changes tend to occur more slowly. Notably, however, Shimada et al. reported the 5-year results of total mastectomy with axillary dissection compared to Halsted's mastectomy as early as 1964 [2]. Their comparison showed no difference between the two methods; however, this method did not become popular in Japan at that time.

According to the breast cancer registry of the Japanese Breast Cancer Society (JBCS) (Fig. 2.1) [3], standard radical mastectomy (Halsted's mastectomy), which consisted of total mastectomy with major and minor pectoral muscle resection and axillary dissection, was the most popular operative method until 1980. About 90 % of the cases underwent standard radical mastectomy. Then, modified radical mastectomy, which consisted of total mastectomy with/without minor pectoral muscle resection and axillary dissection, became the most popular operative method during the 1990s. There were several variations of the modified radical mastectomy, including Patey's modified radical mastectomy, Auchincloss' modified radical

T. Ikeda (✉)

Department of Surgery, Teikyo University School of Medicine, 2-11-1 Kaga, Itabashi-ku, Tokyo 160-8582, Japan

e-mail: ikedat@med.teikyo-u.ac.jp

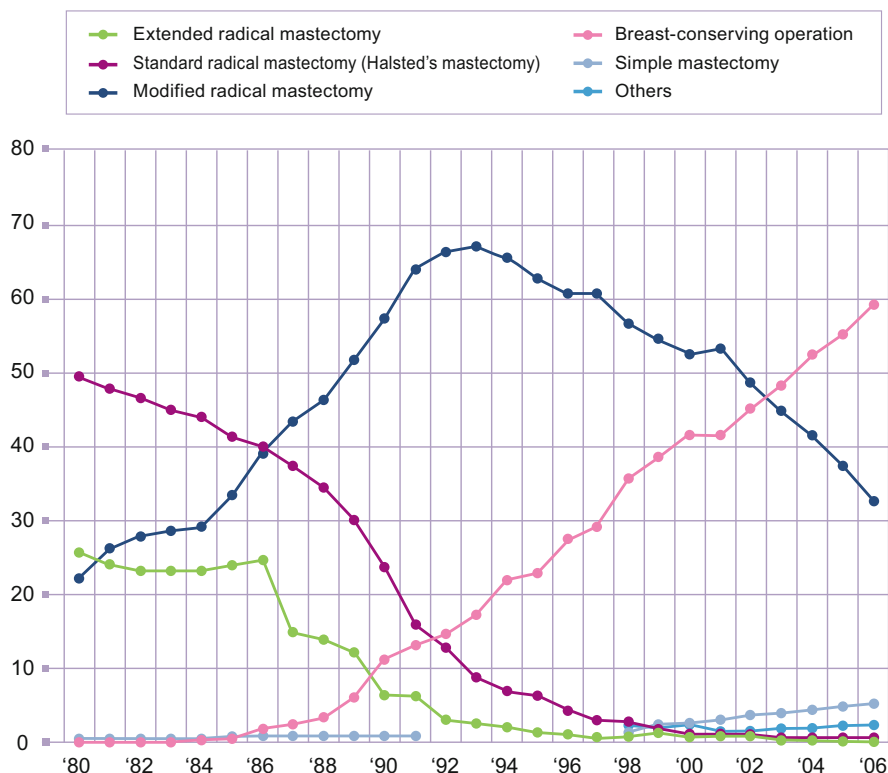


Fig. 2.1 Changing trends in surgical procedures for breast cancer in Japan between 1980 and 2006 (Ref. [3])

mastectomy, and Kodama's method. Patey's modified radical mastectomy was the most popular modified radical mastectomy approach at first, but Auchincloss' method became the most popular during the 1990s. Kodama's method is one type of modified radical mastectomy. High axillary dissection was performed by widening the interpectoral sulcus. With this method, level III axillary lymph nodes could be dissected under direct vision, and the prognosis was comparable to that of radical mastectomy [4].

Breast-conserving operations were initiated around 1986 in Japan. They rapidly increased after the reports of prospective, randomized trials from Western countries [5, 6], and over 60 % of the cases underwent breast-conserving operations in 2006. However, the incidence of breast-conserving operations plateaued at about 70 % in 2011 (Fig. 2.2) [7]. Initially, segmental resection was the most popular breast-conserving operation. At first, the breast-conserving operation was performed without postoperative radiation. With this method, ipsilateral intrabreast tumor recurrence (IBTR) developed in 5.5 % of the 1351 patients treated with breast-conserving operation during a mean follow-up period of 6.5 years [8], which is comparable to the results from Western countries. However, it should be noted that, according to the guideline in Japan for treating breast cancer at that time,

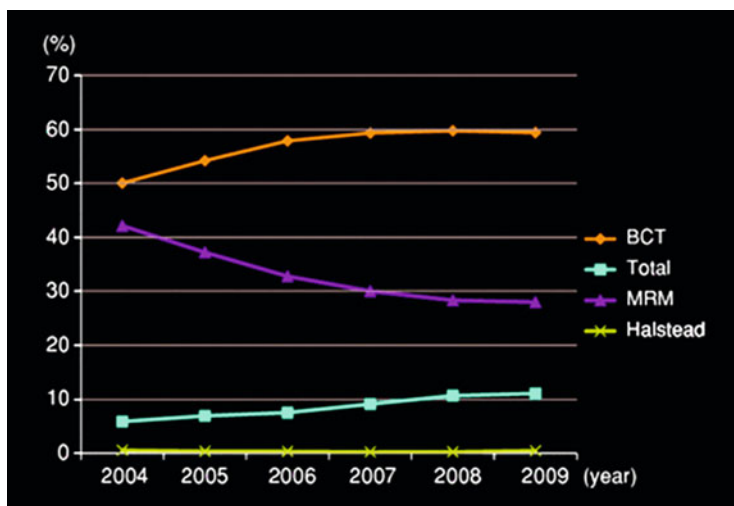


Fig. 2.2 Trends in surgical procedures for breast cancer in Japan from 2004 to 2009 (Ref. [7])

the definition of negative surgical margin was no cancer cells within 5 mm from the cut margin [9], while the definition in Western countries was no cancer cell exposure on the cut surface or within 1 mm [10].

Postoperative radiotherapy is an important component of breast-conserving therapy, and it reduces local recurrence by one-third [11]. Because of this evidence, as well as the operative trend from quadrantectomy (segmental mastectomy) to lumpectomy, lumpectomy with postoperative radiotherapy became the standard procedure for breast-conserving therapy in Japan. The rate of postoperative radiotherapy gradually increased from 60 % in 1992 to 72 % in 2004 and 79 % in 2009 [3, 7].

Because surgical margin status is an important predictive factor for local recurrence, patients with a positive surgical margin for cancer cells are candidates for re-excision. To reduce the reoperation rate, intraoperative frozen section diagnosis and/or print cytology of the surgical margin has been introduced [12]. Since about 27 % of the cases showed pathologically positive surgical margins at the cut end during breast-conserving operations, the evaluation of cut margin status during operation is now commonly performed in Japan.

Preoperative chemotherapy has become more common in Japan, as well as in Western countries, to increase the number of patients eligible for breast-conserving operation. According to the results from the NSABP-B18 trial, the breast-conserving rate increased from 60 % to 68 % after neoadjuvant therapy, while the in-breast recurrence rate increased from 7.6 % to 10.7 % [13]. The surgical margin should be carefully evaluated when performing breast-conserving operations after neoadjuvant chemotherapy, because the intraductal component may be more resistant to chemotherapy and it remains after neoadjuvant chemotherapy. It is important to know the tumor shrinkage pattern, including the concentric, honeycomb pattern, to achieve the appropriate surgical margin. Evaluation of the tumor shrinkage pattern after neoadjuvant chemotherapy by MRI is now commonly performed in Japan [14].

2.2 Surgical Procedures in Axillary Region

With respect to lymph node dissection, axillary dissection was the standard procedure for a lengthy period of time. Parasternal lymph node dissection and/or supraclavicular lymph node sampling were also performed concomitantly with axillary dissection. Level III dissection was also done in the early days, but it was soon abandoned based on the results of a randomized trial. The randomized trial compared level II dissection without minor pectoral muscle resection to level III dissection with minor pectoral muscle resection and showed no difference in terms of both overall and disease-free survival [15]. One other prospective, randomized trial that compared level I dissection to level III dissection also showed no difference in terms of overall survival [16]. Thus, the breast-conserving operation with level I/II dissection became the standard procedure.

However, after the first successful report of sentinel lymph node biopsy (SLNB) [17, 18], this technique was rapidly introduced to clinical settings. As the results of the sentinel node trials revealed no difference in terms of prognosis between SLNB and that of axillary dissection [19], SLNB has been accepted as a standard procedure for early breast cancer with no nodal involvement clinically [20]. According to the breast cancer registry under the auspices of JBCS, SLNB started in 1996, and about 40 % and 60 % of registered institutions began SLNB in 2006 and 2008, respectively. The most used method for SLNB is the blue dye method, followed by a combination method involving the radioisotope (RI) method and the blue dye method. The RI method alone was seldom performed [21]. Only Tc^{99m} -tin colloid and Tc^{99m} -stannous phytate are permitted as radioisotopes, and indocyanine green (ICG) and indigo carmine are permitted as dyes for SLNB by government health insurance. ICG and indigo carmine are proven to be safe, with grade 1 adverse effects occurring in only 0.06 % of patients [22]. Japanese government health insurance approved SLNB for patients with no clinical nodal involvement for reimbursement in 2012. SLNB has not only been accepted as a standard procedure in early breast cancer patients; it has also been accepted in various situations, including large breast cancer, after neoadjuvant chemotherapy, and in-breast cancer recurrence [23].

Given the results of ACOSOG Z-0011 [24], whether backup axillary dissection is needed in patients with 1–2 positive sentinel nodes remains controversial. There is considered to be insufficient evidence to not perform backup dissection, so omitting backup dissection in a patient with macrometastasis is not considered standard procedure in Japan [25]. However, omitting backup dissection has already begun in carefully selected patients at the time of 2013.

In recent years, molecular diagnosis of sentinel nodal metastases has been developed and is currently entering into clinical use [26, 27]. It is now validated to be as accurate as pathological diagnosis for the diagnosis of sentinel node metastasis.

2.3 Reconstruction

Though breast reconstruction after mastectomy has not been commonly performed in Japan, the rate of postmastectomy reconstruction is increasing. According to a questionnaire survey in 2007, about 60 % of the institutions belonging to JBCS did not perform reconstruction [28]. Reconstruction using a latissimus dorsi flap was the most used method, followed by a rectus abdominis flap, and tissue expander immediately after mastectomy. Because government health insurance started to cover breast reconstruction including tissue expander for patients who underwent mastectomy since 2006 and implants this year (2013), the rate of postmastectomy reconstruction is expected to increase. There are no exact statistics concerning secondary reconstruction, but the number of actual cases is considered small [28].

The number of reconstructions after breast-conserving operations is also not large. But among them, many patients who have undergone breast-conserving operations are looking for breast reconstruction due to deformity. Fat grafting is one of the promising methods to reform the deformed breast [29].

Many breast surgeons have noticed the need for oncoplastic surgical procedures during breast-conserving operations. However, there is as yet no established way to perform such procedures, because no method of evaluating the esthetic outcome has been established. One evaluation method that evaluated several issues, including volume, shape, scar, and firmness of the breasts and size, shape, color, and deviation of the nipples, was proposed by a working group of the JBCS [30]. In addition, the Japanese Society of Breast Oncoplastic Surgery was established in 2012.

2.4 Nonsurgical Ablation

The history and procedures for nonsurgical ablation are presented elsewhere in this book, so only the outline of the evolution of these procedures is presented here.

Radiofrequency (RF) ablation for the treatment of hepatocellular carcinoma (HCC) began in the early 1990s. HCC develops with a background of hepatitis B or C infection; therefore, multicentric development occurs. This means that another HCC could develop after resection of one HCC. With this in mind, less invasive methods have been investigated. One less invasive method is RF ablation, which has been covered by government health insurance since 2004. It has become a common treatment for HCC.

In the field of breast cancer treatment, as the concept that breast cancer is a generalized disease from the beginning has been widely accepted, the operative procedure has become less invasive. In addition, core needle biopsy (CNB) has become popular. By performing CNB, one can easily obtain information about hormone receptor status, Her2 overexpression, and other pathological features, which are essential pieces of information needed to plan the treatment of breast cancer patients in the modern era.


Keeping the above in mind, nonsurgical ablation has been tried in Japan. While most patients treated with nonsurgical ablation are treated by the RF method, a few patients are treated by cryoablation or high-intensity focused ultrasonic surgery (HIFU). Details of these methods are described elsewhere in this book. The merit of nonsurgical ablation is obviously a good cosmetic result. On the other hand, the criticisms of nonsurgical ablation include the following: its limited applicability for treating intraductal spreading beyond the main tumor; the completeness of ablation is not guaranteed unless pathological specimens are obtained; the location of the tumor should be apart from the skin and/or muscle; and there are no mature data in terms of prognosis. Due to these reasons, nonsurgical ablation has not been presently accepted as a standard procedure to treat breast cancer patients [31] and has mainly been performed in only a clinical trial setting.

References

1. Matsuki A. A study on Seishu Hanaoka's "Nyugan Seimei Roku": a name list of breast cancer patients. (in Japanese). *Nippon Ishigaku Zasshi*. 2002;1:53–65.
2. Shimada N, Matsuda H, Amaaki T. Carcinoma of the breast. Comparative 5-year survival rates of Halsted's mastectomy and Shimada's mastectomy. *Keio J Med*. 1964;13:67–75.
3. Sonoo H, Noguchi S. Academic committee of the Japanese Breast Cancer Society: results of questionnaire survey on breast cancer surgery in Japan 2004–2006. *Breast Cancer*. 2008;15:3–4.
4. Kodama H. Modification of muscle-preserving radical mastectomy. *Cancer*. 1979;44:1517–22.
5. Veronesi U, Saccozzi R, Del Vecchio M, Banfi A, Clemente C, De Lena M, et al. Comparing radical mastectomy with quadrantectomy, axillary dissection, and radiotherapy in patients with small cancers of the breast. *N Engl J Med*. 1981;305:6–11.
6. Fisher B, Redmond C, Poisson R, Margolese R, Wolmark N, Wickerham L, et al. Eight-year of a randomized clinical trial comparing total mastectomy and lumpectomy with or without irradiation in the treatment of breast cancer. *N Engl J Med*. 1989;320:822–8.
7. Saji S, Hiraoka M, Tokuda Y, Fukui N, Ikeda T. Trends in local therapy application for early breast cancer patients in the Japanese Breast Cancer Society breast cancer registry during 2004–2009. *Breast Cancer*. 2012;19:1–3.
8. Kasumi F, Takahashi K, Nishimura S, Iijima K, Miyagi U, Tada K, et al. CIH-Tokyo experience with breast-conserving surgery without radiotherapy: 6.5 year follow-up results of 1462 patients. *Breast J*. 2006;12:S181–90.
9. Working group for establishing standardized breast conserving therapy under the auspices of Japanese Ministry of Health and Welfare. Guideline of breast conserving therapy for the medical staffs (in Japanese). Tokyo: Kanehara Shuppan; 2005. p. 21–25.
10. Grobmyer SR, Cowher MS, Crowe JP. Optimizing clinical management of surgical margins in breast-conserving therapy for breast cancer. In: ASCO educational book. 2013.
11. Early Breast Cancer Trialists' Collaborative Group (EBCTCG), Darby S, McGale P, Correa C, Taylor C, Arriagada R, Clarke M, et al. Effect of radiotherapy after breast-conserving surgery on 10-year recurrence and 15-year breast cancer death: meta-analysis of individual patient data for 10,801 women in 17 randomised trials. *Lancet*. 2011;378:1707–16.
12. Ikeda T, Enomoto K, Wada K, Takeshima K, Yoneyama K, Furukawa J, et al. Frozen-section-guided breast conserving operation, implications of frozen section diagnosis as a guide to the extent of resection. *Surg Today*. 1997;27:207–12.

13. Wolmark N, Wang J, Mamounas E, Bryant J, Fisher B. Preoperative chemotherapy in patients with operable breast cancer: nine-year results from national surgical adjuvant breast and bowel project B-18. *J Natl Cancer Inst Monogr.* 2001;30:96–102.
14. Nakamura S, Kenjo H, Nishio T, Kazama T, Doi O, Suzuki K. Efficacy of 3D-MR mammography for breast conserving surgery after neoadjuvant chemotherapy. *Breast Cancer.* 2002;9:15–9.
15. Tominaga T, Takashima S, Danno M. Randomized clinical trial comparing level II and level III axillary node dissection in addition to mastectomy for breast cancer. *Br J Surg.* 2004;91:38–43.
16. Kodama H, Nio Y, Iguchi C, Kan N. Ten-year follow-up results of a randomised controlled study comparing level-I vs level-III axillary lymph node dissection for primary breast cancer. *Br J Cancer.* 2006;95:811–16.
17. Krag DN, Weaver DL, Alex JC, Fairbank JT. Surgical resection and radiolocalization of the sentinel lymph node in breast cancer using a gamma probe. *Surg Oncol.* 1993;2:335–9.
18. Giuliano AI, Kirgan DM, Guenther JM, Morton DL. Lymphatic mapping and sentinel lymphadenectomy for breast cancer. *Ann Surg.* 1994;220:391–8.
19. Krag DN, Anderson SJ, Julian TB, Brown AM, Harlow SP, Costantino JP, et al. Sentinel-lymph-node resection compared with conventional axillary-lymph-node dissection in clinically node-negative patients with breast cancer: overall survival findings from the NSABP B-32 randomised phase 3 trial. *Lancet Oncol.* 2010;11:927–33.
20. Evidence based guidelines to treat patients with breast cancer (in Japanese), ed by Japanese Breast Cancer Society, 2013. p. 208–11.
21. Tsugawa K, Nakamura S. The results of a questionnaire survey on sentinel lymph node biopsy for breast cancer patients in Japan (in Japanese). *Nyu-gan no Rinsho (Jpn J Breast Cancer).* 2009;24:265–70.
22. Nakamura S. Current status of sentinel node biopsy for breast cancer in Japan. In: Toi M, Winer EP, editors. *Local and systemic management of primary breast cancers.* Kyoto: Kyoto University Press; 2010. p. 54–60.
23. Yorozuya K, Ikeda T. Sentinel node biopsy under specific conditions. In: Sonoo H, Fukuda M, Ikeda T, Saeki H, Shikama N, editors. *Korekarano Nyuuganshinryou 2013–2014 (breast cancer management in the future) (in Japanese).* Tokyo: Kanehara Shuppan; 2013. p. 43–50.
24. Giuliano AE, Hunt KK, Ballman KV, Beitsch PD, Whitworth PW, Blumencranz PW, et al. Axillary dissection vs no axillary dissection in women with invasive breast cancer and sentinel node metastasis. A randomized clinical trial ACOSOGZ0011. *JAMA.* 2011;305:569–75.
25. Evidence based guidelines to treat patients with breast cancer (in Japanese), ed by Japanese Breast Cancer Society, 2013. p. 216–8.
26. Iinuma H, Tamura J, Omoto D, Kamo N, Ohnaka S, Mitoma Y, et al. Accurate and rapid novel genetic diagnosis for detection of sentinel lymph node metastasis in breast cancer patients. *Br J Cancer.* 2012;107:724–31.
27. Tamaki Y, Akiyama F, Iwase T, Kaneko T, Tsuda H, Sato K, et al. Molecular detection of lymph node metastases in breast cancer patients: results of a multicenter trial using the one-step nucleic acid amplification assay. *Clin Cancer Res.* 2009;15:2879–84.
28. Yano K, Tamaki Y. Results of questionnaire survey on the actual medical status of breast reconstruction (in Japanese). *Nyuugan-no Rinsho (Clin Breast Cancer).* 2007;22:509–14.
29. Asano Y. Cell-assisted lipotransfection to the deformity after breast conserving operation. In: Sonoo H, Fukuda M, Ikeda T, Saeki H, Shikama N, editors. *Korekarano Nyuugan Shinryo 2011–2012 (breast cancer management in the future).* Tokyo: Kanehara Shuppan; 2011. p. 25–30.
30. Sawai K, Nakajima H, Ishihara S, Yano K, Watanabe O, Kitamura K, et al. Study on the evaluation of deformity after breast conserving operation in relation to resected volume (in Japanese). *Proceedings of the 12nd congress of the Japanese Breast Cancer Society;* 2004. p. 107.

31. Evidence based guidelines to treat patients with breast cancer (in Japanese), ed by Japanese Breast Cancer Society, 2013 p. 236–7.



Tadashi Ikeda

Non-surgical Ablation Therapy for Early-stage Breast
Cancer

Kinoshita, T. (Ed.)

2016, VI, 224 p. 124 illus., 81 illus. in color., Hardcover

ISBN: 978-4-431-54462-3