

---

## Introduction

The cornea represents the anterior part of the outer tunic of the eye. It is clear in health and functions as a major refractive component of the eye as well as a protective surface for the anterior segment along with its extension, the sclera. The cornea is multilayered in dimension, and from anterior to posterior is composed of an epithelium, Bowman's layer (anterior condensation of stroma), the corneal stroma, Descemet's Membrane, and an endothelial layer responsible for keeping the cornea in a deturgescenced state by virtue of its pump mechanism. In normal eyes, the central cornea is approximately 550 microns in thickness, and its overall diameter is between 11–12 mm. The cornea is a common site for traumatic eye injury, and in this chapter, we will look at the more common types of injury seen in the emergency setting.

---

L. Rafailov · D.R. Lazzaro (✉)  
Department of Ophthalmology, The State University  
of New York (SUNY) Downstate Medical Center,  
450 Clarkson Avenue, New York, NY 11203, USA  
e-mail: douglas.lazzaro@downstate.edu

D.R. Lazzaro  
Kings County Hospital Center, 541 Clarkson  
Avenue, New York, NY 11203, USA

D.R. Lazzaro  
NYU Medical Center, 550 First Avenue,  
New York, NY 10016, USA

---

## Burns of the Cornea

### Thermal and UV Injury

Thermal injury can occur to the cornea when it comes into direct contact with a flame or with a hot object or liquid that is often projectile in nature. Thermal injuries from fires often happen in the context of other distracting large-scale burns to the rest of the body. Approximately 11% of patients admitted to burn units require ophthalmic consultation [1]. Prompt recognition of thermal injury to the eye is a key to successful management. Fortunately, burn injuries from flames are often limited by the ability of the eyelids to quickly close and provide insulation as well as a Bell's phenomenon if present. These burns often occur when there is an explosive thermal source or one that is projectile in nature when the patient does not have enough time to initiate a blink reflex [2]. In these cases, ruling out further injury from mechanical forces and foreign body is of utmost importance.

The etiology of contact burns to the cornea is either industrial in origin with use of soldering and hot iron particulates, or from home through cooking, curling irons and fireworks. These injuries are often unilateral. In a large study from New Delhi, 42% of patients with thermal burns had boiling fluids as a source [3]. In both this study and others, long-term sequelae were rare and seen in only 3% of patients with corneal burns, most often being symblepharon [4]. Amongst children, the sources of thermal injury are similar but with a greater incidence from

fireworks and superheated foods and liquids from microwaving, with eggs in particular being a common source [5]. Common household thermal items such as curling irons tend to disproportionately affect children as well [6]. These cases tend to be self-limiting with resolution of symptoms 48 h after onset with the use of debridement, topical antibiotics, cycloplegia, and pressure patching [7]. Limbal involvement is a key determinate of prognosis. Treatment for severe burns such as those with fireworks may require limbal stem cell transplantation combined with amniotic membrane transplantation [8]. A recent study by Sharifipour et al. demonstrated that using oxygen via face mask for one hour a day may speed up and improve recovery by improving limbal ischemia, accelerating epithelialization, increasing corneal transparency, and decreasing corneal vascularization [9]. Those patients with severe defects to the eyelids and at risk for exposure keratopathy may benefit from the use of a gas permeable scleral contact lens such as a Boston Ocular Surface Prosthesis [10].

UV light may also be a source of trauma and insult to the cornea, though the damage to the cornea is usually minor with rapid resolution. These injuries are often bilateral and occur from sunlight, tanning lamps, and welding arcs. Acute UV damage results in punctate keratitis and conjunctival chemosis usually 6–12 h after exposure. The de-epithelialization results in patients having pain, tearing, and blepharospasm, but is usually self-limited with re-epithelialization happening sooner than strict thermal or chemical injuries [11]. Patients may be treated symptomatically with lubricants and patching. A common comorbidity with this would be solar retinopathy, which can often have more severe consequences especially in cases of solar eclipse [12].

---

## Chemical Injury

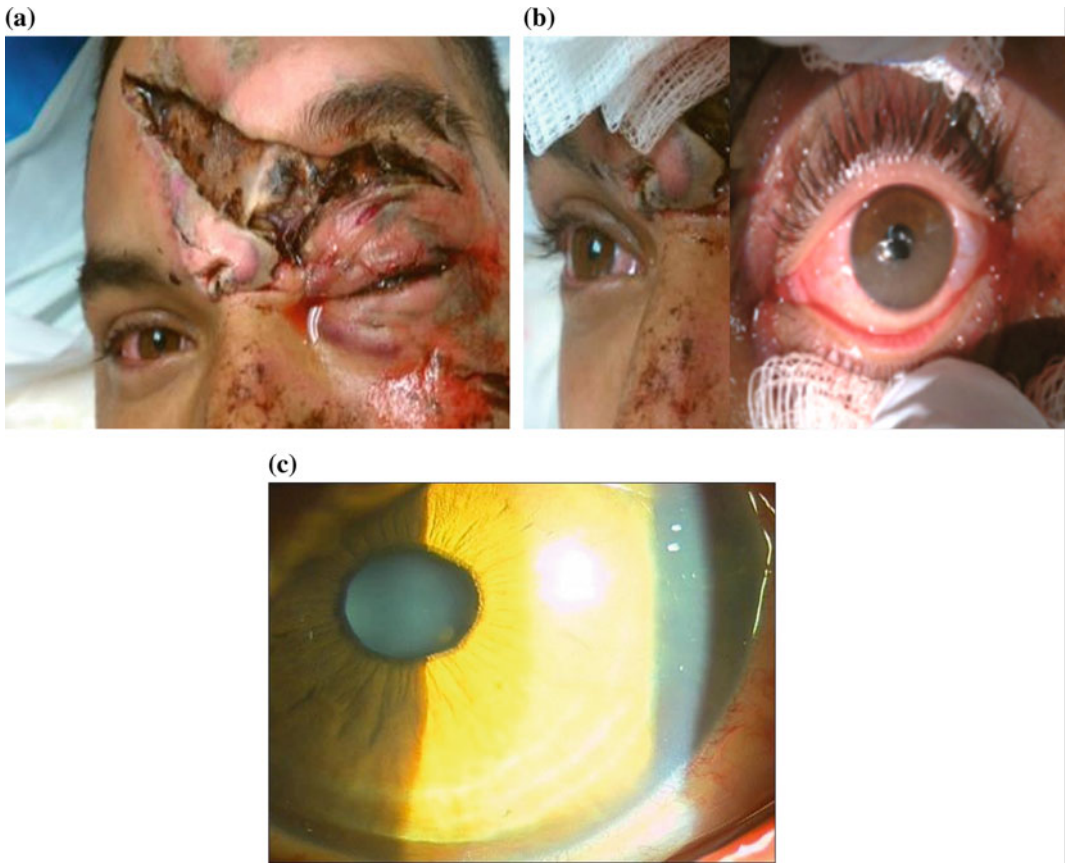
Chemical injury to the eye is a common source of acquired blindness. This type of injury affects men more often than women at a ratio of almost 5:1, often due to the fact that these injuries happen in an industrial setting [13]. These injuries tend to affect

younger patients, such as ages 21–30, those who usually are inexperienced with using chemicals and do not use proper protective equipment. Given the young age of most of these patients, minimizing long-term disability is of paramount importance. Assaults, which represent approximately 11% of cases, tend to result in more severe injuries that have a poorer prognosis [14]. In all cases, immediate treatment with irrigation should precede any efforts to attain a history and complete physical exam. Studies indicate that 42% of injuries are bilateral so prompt treatment of the other eye should also be instituted if there is even minor suspicion of bilateral involvement [13]. Alkali injuries tend to be more severe than acid injuries because alkalis are hydrophilic and lipophilic, causing them to rapidly bind and penetrate through the ocular surface, as well as remain in the periocular area.

## Acid Injury

Acid injury tends to occur in three major settings: laboratories, industry, and the home. The most common acids involved in injury in order of prevalence are sulphuric, nitric, hydrochloric, and oxalic acid [13]. The most severe of these acids is hydrofluoric acid due to its ability to penetrate the stroma and from additional damage of the fluoride ion [15]. Explosive car batteries are a large source of sulfuric acid injury in the population [14]. These explosive injuries tend to afflict those with increased exposure such as mechanics and engineers and can be complicated by blunt or penetrating trauma (See Fig. 2.1 below); these accidents are generally avoidable with use of proper safety precautions [16].

When acid comes in contact with the corneal surface, penetration is slowed in the stroma because the acid tends to bind the proteins of the corneal epithelium and collagen of the stroma causing protein precipitation and denaturation [17]. Experimental models in rabbits have demonstrated that this binding of collagen can cause shrinkage of the outer cornea and transiently increase intraocular pressure [18]. Further damage to the limbus and anterior chamber yields a worse prognosis. Damage that is severe



**Fig. 2.1** Patient carrying a box with a car battery which exploded into his forehead. A mechanical and chemical acid injury resulted. In Fig. 2.1a, the extent of injury is noted. Figure 2.1b shows hazy inferior cornea which was flushed extensively and had an amniotic membrane (Prokera) placed. Figure 2.1c shows cornea after healing takes place

enough in nature to penetrate the cornea can result in secondary glaucoma and cataract [19]. Damage to the limbal stem cells does not allow the cornea to re-epithelialize and results in corneal conjunctivalization, vascularization, chronic inflammation, and epithelial defects [20].

### Alkali Injury

Alkali injuries tend to be much more severe than acid injuries because of their lipophilic nature and their ability to penetrate through the eye. A saponification process also occurs when the dissociated hydroxyl ion acts on the cell membranes causing cellular destruction [21]. Alkalis tend to be a more common source of injury

compared to acids. Among alkalis, sodium hydroxide, calcium hydroxide, and ammonium hydroxide are the most common in order of prevalence of injury [13]. Alkali injuries tend to come from plaster, lye, lime, cement, ammonia, and cleaning agents [14]. Magnesium hydroxide, which is the active ingredient in sparkler fireworks can cause both a thermal and alkali injury. Because these agents tend to be dry, using a cotton tip to initially brush the dry product out of the eye is preferred before irrigation.

### Treatment

Treatment following chemical burns is similar in alkali and acid burns. Immediate management

following chemical burns is of utmost importance and should theoretically start in the field of injury; variability in time before treatment can greatly determine the extent of damage [22]. Patients can become quickly disoriented due to the resultant blepharospasm, and often need assistance in guidance [23]. The patient should be made to lie down for irrigation of the affected eyes. Irrigant solutions differ in quality when comparing patient comfort and effectiveness in normalizing the pH. Water is not a preferred agent for flushing the eye in these injuries because it is hypotonic and may therefore diffuse across the cornea trapping or pushing the toxins instead of irrigating them [23]. That being said, water should be used in the absence of other irrigating solutions. Buffering capacity solutions when available are preferred; Previn, Diphoterine, or Cederroth Eye Wash solution are far superior in balancing intraocular pH based on testing with experimental models with rabbits eyes [24]. Irrigation should last at least 15 min with use of at least 1000 mls of irrigation solution with confirmation of normalization of pH with litmus strip. A Morgan lens can help direct the irrigation. Topical anesthesia can be very helpful if instilled prior to irrigation. Providers should irrigate the fornices, above and below the eyelids, as well as have the patient look in all directions during irrigation to make sure areas still containing or trapping the chemical are not missed. One should note that the use of ointments is not ideal after a chemical injury as this could potentially trap and prolong the noxious stimulus.

Following irrigation and immediate management the goals in the acute phase are to foster reepithelialization, decrease inflammation, prevent infection, reduce sequela, and prevent further damage [25]. There are different classification systems for chemical injury: Bagley, Dua [26], and Roper-Hall [27]. The median number of days for reepithelialization for patients with grade III–V injuries tends to be approximately 30 days using standard therapy [28]. During this time the cornea may be at risk for desiccation, increased friction from blinking, and exposure keratopathy from eyelid closure defects. While the cornea is rebuilding its epithelial layer, the provider must anticipate the functional deficits of this layer and treat proactively. Treatment in the early phase would

include frequent preservative free artificial tears to prevent further erosion of the stroma. Mild chemical burns to the eye can be further managed with topical antibiotic.

Extensive damage, such as with Grade III–V chemical burns, require more substantial treatment and most likely require admission for intensive treatment and monitoring. Use of systemic ascorbic acid and ascorbate drops for chemical burns to the eye has been suggested for over 30 years because of their ability to help collagen production, but few studies exist to fully advocate its use for chemical burns to the eye [29]. Topical citrate has also been recommended as a means to reduce inflammation of the cornea by inhibiting polymorphonuclear leukocytes [30]. An 11-year retrospective review led by Brodovsky found that use of ascorbic acid, ascorbate drops, and citrate led to no benefit for Grade I–II burns, clinical benefit in patients with Grade III burns, and unclear effect for Grade IV burns [31]. Because chemical burns may cause shrinkage of the collagen fibers in the cornea, intraocular pressure must also be monitored in the early stages of treatment as 22% of patients with chemical burns develop secondary glaucoma, often requiring oral carbonic anhydrase inhibitors [19]. A study by Panda et al. found that using topical autologous platelet-rich plasma in the form of eyedrops for patients soon after injury can safely reduce the number of days needed for re-epithelialization due to the presence of growth factors in plasma [28].

Topical steroids are also used in the early stages of treatment to reduce inflammation and the release of collagenases and proteases. Steroids may be beneficial particularly in the early stages of treatment, though there is concern that prolonged and extensive use may prevent sufficient collagen production that can lead to cornea/scleral melting; concomitant use with topical vitamin C can help prevent this [32]. Cycloplegics such as homatropine are also indicated for moderate-to-severe chemical burns, though cycloplegics with vasoconstrictive properties should be avoided. Cycloplegics will reduce pain and the risk of iris lens synechiae [33]. One experimental form of treatment not fully tested in humans is the use of oral tetracyclines during the recovery period due to their

ability to inhibit metalloproteinases and collagenase activity [34].

Surgical management if required usually follows in the weeks following the insult. There are many relatively newer therapies available for treatment including amniotic membrane transplantation, limbal stem cell transplantation, corneal transplantation, and keratoprosthesis. Immediate therapy in the acute phase can include tenonplasty if warranted in severe burns. This is done by first removing necrotic conjunctiva and advancing Tenon's tissue from the orbital region to the limbus and securing it to the sclera to provide vascularization to the damaged region to help prevent perforation [35]. Amniotic membrane transplantation (AMT) for corneal chemical burns, first studied by Meller et al., found that the use of AMT within 2 weeks of injury for mild-to-moderate burns can rapidly restore corneal and conjunctival surfaces [36]. For severe burns, AMT was able to reduce limbal stromal inflammation and restore the conjunctival surface, and prevent symblepharon formation, it could not fully prevent limbal stem cell deficiency [36]. In these cases of severe burns, a limbal stem cell transplant may be necessary [37]. A recent study has shown that autologous limbal stem cells can be harvested from the contralateral eye and grown ex vivo on fibrin media, allowing transplantation that results in transparent self-renewing epithelium of the damaged eye in 76.6% of patients [38]. Usually these two modalities of treatment can be used together with superior results for severe burns when limbal stem cell deficiencies can be anticipated [39].

If the aforementioned therapies do not produce results allowing for meaningful recovery of vision, there are two options left for last resort, corneal transplantation and keratoprosthesis. Corneal transplantation has a higher rate of rejection in chemical burns and requires large diameter transplants for limbal stem cell transfer [40]. If patients do not qualify for transplant or have repeatedly failed transplant, a Boston Type 1 keratoprosthesis may ultimately be an option for therapy. A recent 7-year retrospective study shows that visual acuity of  $\geq 20/200$  using the

prosthesis is achieved in 50% of patients and total device retention after 7 years is 67% [41]. The most common complications in order of prevalence were Retro-prosthetic membrane formation, glaucoma surgery, retinal detachment, and endophthalmitis [41] following keratoprosthesis. Further design and technological revisions may help reduce these complications in the years to come.

---

## Corneal Abrasion

Corneal abrasion is one of the more common complaints of patients, representing approximately 24.3% of patients who present to the emergency room for ophthalmological complaints [42]. It occurs when the corneal epithelium is disrupted from a variety of injuries. As with other ocular injuries, these injuries tend to happen more often in the workplace or during sports activities. Common etiologies of corneal abrasions include fingernails, sports equipment, make-up brushes, and airbags. Children represent the most common source of fingernail injury, as patients are often parents who become injured while holding a small child [43]. Airbag deployment presents a particular challenge because it may also be associated with a high-energy blunt force as well as alkali injury [44]. In the hospital setting, corneal abrasion can happen more often in unconscious patients in the ICU or patients receiving non-ocular surgery as a complication of accidental injury during the surgery [45]. Patients often present with pain, tearing, blurred vision, photophobia, red eye, and foreign body sensation. Often times these injuries are associated with corneal lacerations and foreign bodies; and as with any mechanical injury, careful attention must be paid to the risk of an open globe. Prognosis is largely dependent on the size of the defect and depth of injury and involvement of Bowman's layer.

Work-up for such injuries includes careful investigation regarding the mechanism of the injury. High-energy forces such as with airbags, projectiles, and punches should alert the physician in seeking other sequelae of injury both



ocular and non-ocular. Because of the severe pain and photophobia associated with abrasions, work-up must often begin with the use of anesthetic eye drops such as tetracaine or proparacaine. Topical anesthetics should never be given for outpatient use. Abrasions may be immediately visible to the naked eye as they may present with a haze due to the reduced light reflex. Using fluorescein dye will allow the examiner to see a more enhanced demarcation of the abrasion. All patients should have a full ophthalmologic exam to rule out other injuries, particularly to the anterior chamber and retina. A Seidel test can be used to determine if there is a leak from the anterior chamber indicating an open globe.

## Treatment

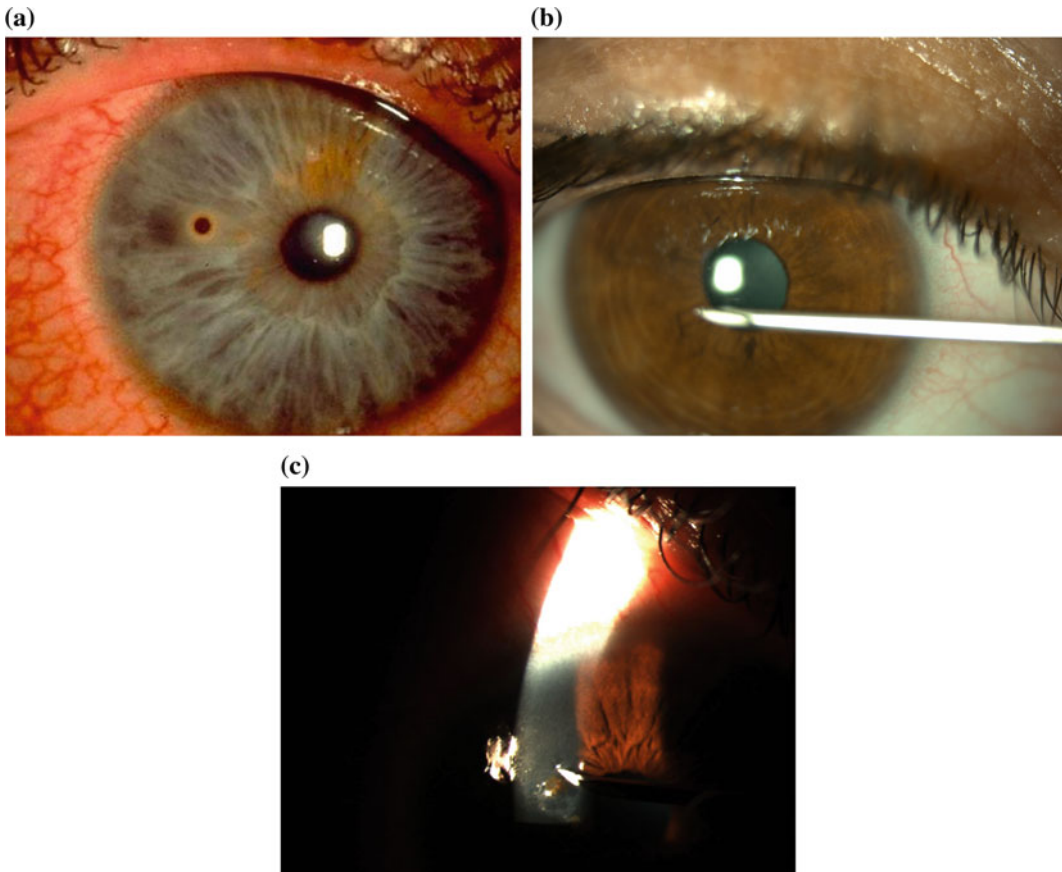
Most patients with corneal abrasions require antimicrobial therapy to reduce the risk of microbial keratitis. Topical antibiotics, such as fluoroquinolones, should be broad-spectrum and anti-pseudomonal and should be initiated as soon as possible. Patching for corneal abrasions, once a standard of treatment, has been challenged as a practice in the 1990s. A meta-analysis review concluded that small abrasions do not need patching in the first day, and that patching may not reduce pain levels or speed healing [46]. Patching also causes monocular vision, which may become a cause of further injury and discomfort for the patient. A reasonable alternative may be the use of soft contact lenses. Topical NSAIDs such as diclofenac have been proven to be safe and effective in managing pain without slowing the healing process [47]. Topical NSAIDs may also help avoid the need for oral analgesics and narcotics. Cycloplegics may also be used for pain control, though should be reserved for larger defects. Most defects usually heal in 24 h while all defects are usually healed by 48 h. Recurrent corneal erosion can be an unfortunate consequence of corneal abrasion. Approximately 40% of recurrent corneal erosions are caused by trauma [48]. This can happen

despite adequate initial treatment and can give the patient ocular pain upon awakening, tearing, discomfort, and foreign body sensation long after the initial injury [49].

---

## Corneal Foreign Bodies

Corneal foreign bodies usually occur when the cornea comes in contact with a high-speed small projectile. These injuries therefore often occur in the workplace with metal workers and with patients who use power tools. Patients tend to be overwhelmingly male and often have a history of not using eye protection. Interestingly, a study from Australia found that 45% of patients presenting with metallic foreign bodies actually did use eye protection, but it is unclear if mechanism of injury occurred due to failure of the eye protector apparatus, or operator failure in using the proper eye protection needed for the job [50]. Broadly, foreign bodies can be divided into two classes, organic and inorganic. Prevalence between the two categories often depends on the location of the hospital or clinic in relation to the industry but foreign bodies tend to overwhelmingly be metal in nature [51]. Organic foreign bodies carry the increased risk of infection as they typically carry with them more bacteria and fungi. Inorganic foreign bodies such as glass, stone, plastic, and certain metals are frequently benign as they often do not induce inflammation. Of the metals, iron and copper tend to be the most troublesome due to their staining and ability to induce inflammation. Metal foreign bodies tend to have lower rates of infection as they are often heated when they become projectile. Overall, most foreign body injuries tend to be benign and not associated with significant morbidity. In a study of 288 patients with superficial corneal metallic foreign bodies, only 1 patient had concomitant corneal laceration [52]. Regardless, careful attention must be paid to the history and physical in determining the force of the projectile involved and the risk of an open globe (Fig. 2.2).



**Fig. 2.2** Patient presented with corneal foreign body after metal grinding accident (Fig. 2.2a). It is important to view depth of foreign body at slit lamp before using sharp object to remove. It is the authors' preference to bend a 25 gauge needle so the needle is actually almost perpendicular to the cornea to avoid inadvertent damage to cornea (Fig. 2.2b, c). Some prefer to remove the rust ring with a rotating brush. Alternatively, the needle can be used to remove both the foreign body and rust. It is imperative to have patient seated at the slit lamp with the forehead pressed against band to avoid iatrogenic corneal perforation. If the foreign body is deep and against Descemet's membrane/endothelium, the removal should occur in the operating room

Patients with a corneal foreign body typically present with pain, foreign body sensation, tearing, red eye, and sometimes photophobia. Whether a patient presents with blurred vision is largely dependent on whether the foreign body is along the visual axis. The physical exam must focus on eliminating the possibility of intraocular injury and further ocular damage. If imaging is required, one should not use MRI if a metallic foreign body is suspected. As with corneal abrasions, fluorescein can help define the borders of the injury. A Seidel test can be used to determine if there is a leak from the anterior chamber. Topical anesthetics may have to be

used early in the exam in order to increase patient comfort and compliance with the exam as well as to facilitate removal.

## Treatment

Treatment should focus on removing the foreign body without damaging the surrounding structures. Oftentimes, certain inorganic foreign bodies may be safely left in if they are difficult to extract and do not cause visual disturbance and have low risk of inflammation and infection. Ferrous foreign bodies often need to be removed as soon as possible

due to their ability to create rust rings. Choice of intervention depends on the type of foreign body and depth of extension. Cotton applicators can be used to sweep foreign bodies if they are very superficial, though this may cause further corneal abrasion if not done carefully. Small gauge hypodermic needles can be bent at the bevel and used to dislodge and scoop foreign bodies. If a bent needle tip is preferred, it must be prepared in a sterile fashion; one method is by inserting a smaller gauge needle into the designated needle and bending the two at a 90° angle [53]. When using a needle, both the patient and the practitioner need to be optimally positioned in order to enhance stability through hand bracing and to reduce the risk of further injury. Rust rings can be treated as foreign bodies as well and can be removed using a powered burr or a needle, and care must be given to avoid creating a subsequent larger epithelial defect than what is necessary.

Patients should also receive antimicrobial therapy, approximately 14% of foreign bodies have been found to have positive culture results, with coagulase-negative *Staphylococcus* being the most common pathogen [51]. Antimicrobial therapy should be broad spectrum, such as fluoroquinolones. Fungal keratitis, though uncommon with foreign bodies, must be considered in cases where infection continues to occur despite antibacterial therapy, particularly with organic foreign bodies [54]. There is no current evidence to support the use of routine tetanus prophylaxis in nonpenetrating ocular injury [55]. As with corneal abrasions, the use of eye patches have been called into question as they have failed to demonstrate any advantage in healing [56]. In a study examining noncomplicated foreign body injury, defined as patients who are noncontact lens wearers and had foreign bodies outside the visual axis, the average length of time for resolution of the epithelial defect was approximately 4 days [57].

---

## Corneal Laceration

A corneal laceration occurs when the cornea is cut, often with a sharp object, leaving a defect that can be partial or full thickness. Among

corneal injuries, corneal laceration can often represent one of the more severe injuries due to comorbidities associated with further intraocular injury. For children, they represent a common cause of amblyopia and ocular morbidity. Approximately 86% of penetrating wounds to the eye occur in males [58]. Full thickness wounds present a particular challenge because of the increased risk of intraocular infection and often require early surgical repair.

A key part of the work-up for corneal lacerations includes determining whether the wound is partial or full thickness as well as determining the extent of other injuries. Depth of the anterior chamber can help determine whether there is a leak. A positive Seidel test can help rule in a full thickness laceration but a negative test cannot definitively rule it out due to the ability of full thickness wounds to self-seal. Once a full thickness laceration is discovered, CT of the orbits should be considered in order to rule out a retained intraocular foreign body. Full thickness injuries to the eye can be difficult to appreciate when the anatomy becomes significantly deformed [59].

## Treatment

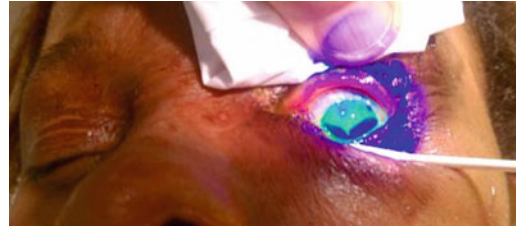
Patients often require thorough local and systemic pain control as well as an antiemetic in order to prevent vomiting and inadvertently increasing intraocular pressure. Nonpenetrating corneal lacerations can be treated the same way as a foreign body would. Topical antibiotics should be broad spectrum. Nonpenetrating lacerations also require thorough washout of the wound. Lacerations that are nonpenetrating and have some degree of avulsion should be re-approximated and fibrin glue can be placed on top to stabilize the defect. If this cannot be done without causing corneal deformity, then the wound should be closed surgically. Typically most smaller wounds, those 1–2 mm, can be closed with fibrin glue, as use of sutures can introduce further injury and points of infection [60, 61]. Typically if glue is used the patient can have a soft bandage contact lens applied after the



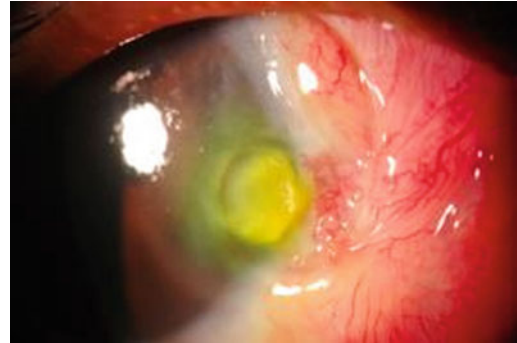
glue is dried. If suturing is necessary, 10-0 nylon sutures are preferred and require very meticulous re-approximations of the cornea with attention to depth of layer sutured so as to avoid over-riding of the cornea and repeat leaks [62]. Patients who develop astigmatism from corneal deformity may eventually require rigid gas permeable contact lenses to correct astigmatism or a corneal transplant [63].

Corneal lacerations that are full thickness should be treated like an open globe (see section on ruptured globe for further detail). Careful inspection of the eye should focus on determining further intraocular injury including second points of extraocular communication that may cause further outflow or sources of infection. All interventions that put pressure on the eye such as applanation and B-scans should be minimized to avoid further spilling of intraocular contents. Patients with ruptured globes require admission and systemic and local broad-spectrum antibiotics with tetanus prophylaxis.

Surgical repair depends on the extent of damage. Studies have shown that laceration repair, traumatic cataract removal, and posterior chamber intraocular lens implantation can be attempted simultaneously with primary repair for those patients with stable injuries [64, 65]. Methods for repairing the corneal defect include use of amniotic membrane transplantation, lamellar transplantation, and use of autografts [66]. For children, particularly those under 7 years of age, focus should be on aggressive treatment to avoid amblyopia [67]. Treatments found to help prevent amblyopia include prompt traumatic cataract extraction with either primary or secondary IOL implantation, opening of a posterior capsular opacification with YAG laser, correction of refractive errors, and patching [68]. Initial visual acuity of 20/200 or better is usually a predictor of excellent outcome with 95% of patients having final visual acuity of 20/60 or better [58].



**Corneal Case 1:** A woman burned her cornea with hot oil while cooking



**Corneal Case 2:** Patient post pterygium surgery with large non-healing dellen

## References

1. Bouchard CS, Morno K, Perkins J, et al. Ocular complications of thermal injury: a 3-year retrospective. *J Trauma*. 2001;50(1):79–82.
2. Boone KD, Boone DE, Lewis RW 2nd, Kealey GP. A retrospective study of the incidence and prevalence of thermal corneal injury in patients with burns. *J Burn Care Rehabil*. 1998;19(3):216–8.
3. Vajpayee RB, Gupta NK, Angra SK, et al. Contact thermal burns of the cornea. *Can J Ophthalmol*. 1991;26(4):215–8.
4. Boone KD, Boone DE, Lewis RW 2nd, Kealey GP. A retrospective study of the incidence and prevalence of thermal corneal injury in patients with burns. *J Burn Care Rehabil*. 1998;19(3):216–8.
5. Ratnapalan S, Das L. Causes of eye burns in children. *Pediatr Emerg Care*. 2011;27(2):151–6.
6. Qazi K, Gerson LW, Christopher NC, et al. Curling iron-related injuries presenting to U.S. emergency departments. *Acad Emerg Med*. 2001;8(4):395–7.

7. Mannis MJ, Miller RB, Krachmer JH. Contact thermal burns of the cornea from electric curling irons. *Am J Ophthalmol*. 1984;98(3):336–9.
8. Shimazaki J, Konomi K, Shimmura S, Tsubota K. Ocular surface reconstruction for thermal burns caused by fireworks. *Cornea*. 2006;25(2):139–45.
9. Sharifipour F, Baradaran-Rafii A, Idani E, et al. Oxygen therapy for acute ocular chemical or thermal burns: a pilot study. *Am J Ophthalmol*. 2011;151(5):823–8.
10. Kalwerisky K, Davies B, Mihora L, et al. Use of the boston ocular surface prosthesis in the management of severe periorbital thermal injuries: a case series of 10 patients. *Ophthalmology*. 2012;119(3):516–21.
11. Schein OD. Phototoxicity and the cornea. *J Natl Med Assoc*. 1992;84(7):579–83.
12. MacFaul PA. Visual prognosis after solar retinopathy. *Br J Ophthalmol*. 1969;53(8):534–41.
13. Saini JS, Sharma A. Ocular chemical burns—clinical and demographic profile. *Burns*. 1993;19(1):67–9.
14. Morgan SJ. Chemical burns of the eye: causes and management. *Br J Ophthalmol*. 1987;71(11):854–7.
15. McCulley JP. Ocular hydrofluoric acid burns: animal model, mechanism of injury and therapy. *Trans Am Ophthalmol Soc*. 1990;88:649–84.
16. Moore AT, Cheng H, Boase DL. Eye injuries from car battery explosions. *Br J Ophthalmol*. 1982;66(2):141–4.
17. Dua HS, King AJ, Joseph A. A new classification of ocular surface burns. *Br J Ophthalmol*. 2001;85(11):1379–83.
18. Paterson CA, Eakins KE, Paterson E, et al. The ocular hypertensive response following experimental acid burns in the rabbit eye. *Invest Ophthalmol Vis Sci*. 1979;18(1):67–74.
19. Kuckelkorn R, Kottek A, Reim M. Intraocular complications after severe chemical burns—incidence and surgical treatment. *Klin Monbl Augenheilkd*. 1994;205(2):86–92.
20. Arora R, Mehta D, Jain V. Amniotic membrane transplantation in acute chemical burns. *Eye (Lond)*. 2005;19(3):273–8.
21. Wagoner MD. Chemical injuries of the eye: current concepts in pathophysiology and therapy. *Surv Ophthalmol*. 1997;41(4):275–313.
22. Schrage NF, Langefeld S, Zschocke J, et al. Eye burns: an emergency and continuing problem. *Burns*. 2000;26(8):689–99.
23. Kuckelkorn R, Schrage N, Keller G, Redbrake C. Emergency treatment of chemical and thermal eye burns. *Acta Ophthalmol Scand*. 2002;80(1):4–10.
24. Rihawi S, Frentz M, Schrage NF. Emergency treatment of eye burns: which rinsing solution should we choose? *Graefes Arch Clin Exp Ophthalmol*. 2006;244(7):845–54.
25. Eslani M, Baradaran-Rafii A, Movahedan A, Djalilian AR. The ocular surface chemical burns. *J Ophthalmol*. 2014;2014:196827.
26. Dua HS, King AJ, Joseph A. A new classification of ocular surface burns. *Br J Ophthalmol*. 2001;85(11):1379–83.
27. Gupta N, Kalaivani M, Tandon R. Comparison of prognostic value of Roper Hall and Dua classification systems in acute ocular burns. *Br J Ophthalmol*. 2011;95(2):194–8.
28. Panda A, Jain M, Vanathi M, et al. Topical autologous platelet-rich plasma eyedrops for acute corneal chemical injury. *Cornea*. 2012;31(9):989–93.
29. Pfister RR, Paterson CA. Ascorbic acid in the treatment of alkali burns of the eye. *Ophthalmology*. 1980;87:1050–7.
30. Pfister RR, Haddox JL, Paterson CA. The efficacy of sodium citrate in the treatment of severe alkali burns of the eye is influenced by the route of administration. *Cornea*. 1982;1:205–11.
31. Brodovsky SC, McCarty CA, Snibson G, et al. Management of alkali burns: an 11-year retrospective review. *Ophthalmology*. 2000;107(10):1829–35.
32. Davis AR, Ali QK, Aclimandos WA, Hunter PA. Topical steroid use in the treatment of ocular alkali burns. *Br J Ophthalmol*. 1997;81(9):732–4.
33. Gicquel JJ. Management of ocular surface chemical burns. *Br J Ophthalmol*. 2011;95(2):159–61.
34. Perry HD, Hodes LW, Seedor JA, et al. Effect of doxycycline hyclate on corneal epithelial wound healing in the rabbit alkali-burn model: preliminary observations. *Cornea*. 1993;12(5):379–82.
35. Kuckelkorn R, Kottek A, Schrage N, et al. Long-term results of Tenon-plasty in treatment of severe chemical eye burns. *Ophthalmologie*. 1995;92(4):445–51.
36. Meller D, Pires RT, Mack RJ, et al. Amniotic membrane transplantation for acute chemical or thermal burns. *Ophthalmology* 2000;107(5):980–9; discussion 90.
37. Tseng SC, Prabhasawat P, Barton K, et al. Amniotic membrane transplantation with or without limbal allografts for corneal surface reconstruction in patients with limbal stem cell deficiency. *Arch Ophthalmol*. 1998;116(4):431–41.
38. Rama P, Matuska S, Paganoni G, et al. Limbal stem-cell therapy and long-term corneal regeneration. *N Engl J Med*. 2010;363(2):147–55.
39. Shimazaki J, Yang HY, Tsubota K. Amniotic membrane transplantation for ocular surface reconstruction in patients with chemical and thermal burns. *Ophthalmology*. 1997;104(12):2068–76.
40. Maguire MG, Stark WJ, Gottsch JD, et al. Risk factors for corneal graft failure and rejection in the collaborative corneal transplantation studies. collaborative corneal transplantation studies research group. *Ophthalmology*. 1994;101(9):1536–47.
41. Srikumaran D, Munoz B, Aldave AJ, et al. Long-term outcomes of boston type 1 keratoprosthesis implantation: a retrospective multicenter cohort. *Ophthalmology*. 2014;121(11):2159–64.
42. Edwards RS. Ophthalmic emergencies in a district general hospital casualty department. *Br J Ophthalmol*. 1987;71(12):938–42.
43. Lin YB, Gardiner MF. Fingernail-induced corneal abrasions: case series from an ophthalmology emergency department. *Cornea*. 2014;33(7):691–5.

44. Ball DC, Bouchard CS. Ocular morbidity associated with airbag deployment: a report of seven cases and a review of the literature. *Cornea*. 2001;20(2):159–63.
45. Roth S, Thisted RA, Erickson JP, et al. Eye injuries after nonocular surgery. A study of 60,965 anesthetics from 1988 to 1992. *Anesthesiology*. 1996;85(5):1020–7.
46. Turner A, Rabiou M. Patching for corneal abrasion. *Cochrane Database Syst Rev* 2006(2):CD004764.
47. Jayamanne DG, Fitt AW, Dayan M, et al. The effectiveness of topical diclofenac in relieving discomfort following traumatic corneal abrasions. *Eye (Lond)*. 1997;11(pt 1):79–83.
48. Diez-Feijoo E, Grau AE, Abusleme EI, Duran JA. Clinical presentation and causes of recurrent corneal erosion syndrome: review of 100 patients. *Cornea*. 2014;33(6):571–5.
49. Eke T, Morrison DA, Austin DJ. Recurrent symptoms following traumatic corneal abrasion: prevalence, severity, and the effect of a simple regimen of prophylaxis. *Eye (Lond)*. 1999;13(Pt 3a):345–7.
50. Ramakrishnan T, Constantinou M, Jhanji V, Vajpayee RB. Corneal metallic foreign body injuries due to suboptimal ocular protection. *Arch Environ Occup Health*. 2012;67(1):48–50.
51. DeBroff BM, Donahue SP, Caputo BJ, et al. Clinical characteristics of corneal foreign bodies and their associated culture results. *CLAO J*. 1994;20(2):128–30.
52. Luo Z, Gardiner M. The incidence of intraocular foreign bodies and other intraocular findings in patients with corneal metal foreign bodies. *Ophthalmology*. 2010;117(11):2218–21.
53. Lim LT, Al-Ani A, Ramaesh K. Simple innovative measures for ease of corneal foreign body removal. *Ann Acad Med Singapore*. 2011;40(10):469–70.
54. Fahad B, McKellar M, Armstrong M, et al. Aspergillus keratitis following corneal foreign body. *Br J Ophthalmol*. 2004;88(6):847–8.
55. Benson WH, Snyder IS, Granus V, et al. Tetanus prophylaxis following ocular injuries. *J Emerg Med*. 1993;11(6):677–83.
56. Hulbert MF. Efficacy of eyepad in corneal healing after corneal foreign body removal. *Lancet*. 1991;337(8742):643.
57. Brissette A, Mednick Z, Baxter S. Evaluating the need for close follow-up after removal of a noncomplicated corneal foreign body. *Cornea*. 2014;33(11):1193–6.
58. Esmaeli B, Elner SG, Schork MA, Elner VM. Visual outcome and ocular survival after penetrating: a clinicopathologic study/trauma. *Ophthalmology*. 1995;102(3):393–400.
59. Hamill MB. Corneal and scleral trauma. *Ophthalmol Clin North Am*. 2002;15(2):185–94.
60. Nuhoglu F, Altiparmak UE, Hazirolan DO, et al. Comparison of sutures and cyanoacrylate tissue adhesives for wound repair in a rat model of corneal laceration. *Ophthalmic Res*. 2013;49(4):199–204.
61. Siatiri H, Moghimi S, Malihi M, Khodabande A. Use of sealant (HFG) in corneal perforations. *Cornea*. 2008;27(9):988–91.
62. Rowsey JJ, Hays JC. Refractive reconstruction for acute eye injuries. *Ophthalmic Surg*. 1984;15(7):569–74.
63. Zheng B, Shen L, Walker MK, et al. Clinical evaluation of rigid gas permeable contact lenses and visual outcome after repaired corneal laceration. *Eye Contact Lens*. 2015;41(1):34–9.
64. Lamkin JC, Azar DT, Mead MD, Volpe NJ. Simultaneous corneal laceration repair, cataract removal, and posterior chamber intraocular lens implantation. *Am J Ophthalmol*. 1992;113(6):626–31.
65. Rubsamen PE, Irvin WD, McCuen BW 2nd, et al. Primary intraocular lens implantation in the setting of penetrating ocular trauma. *Ophthalmology*. 1995;102(1):101–7.
66. Vora GK, Haddadin R, Chodosh J. Management of corneal lacerations and perforations. *Int Ophthalmol Clin*. 2013;53(4):1–10.
67. Zaidman G, Ramirez T, Kaufman A, et al. Successful surgical rehabilitation of children with traumatic corneal laceration and cataract. *Ophthalmology*. 2001;108(2):338–42.
68. Segev F, Assia EI, Harizman N, et al. Corneal laceration by sharp objects in children seven years of age and younger. *Cornea*. 2007;26(3):319–23.

Textbook of Ocular Trauma

Evaluation and Treatment

Kaufman, S.; Lazzaro, D. (Eds.)

2017, XVII, 284 p. 191 illus., 144 illus. in color.,

Hardcover

ISBN: 978-3-319-47631-5