
The History of Trans-sphenoidal Surgery for Pituitary Tumours

2

James A.J. King and Andrew H. Kaye

Understanding and Diagnosis of Pituitary Tumours

The development of pituitary surgery has evolved based on a progressive understanding of the pathophysiology of these tumours over the past 100 years. This has been underpinned by improvements in radiological imaging of the pituitary region and the development of immunohistochemistry techniques and more recently molecular genetics. Coupled with improvements in technology, surgical instrumentation and lighting, the operations have evolved and progressively become more refined since first undertaken in the modern era by Hermann Schloffer at the University of Innsbruck. There have been innumerable contributors in this process, of which the major participants will be highlighted in this review.

The French physician, Pierre Marie (1853–1940), described two cases of acromegaly from the Pitie-Salpetriere Hospital in Paris in 1886 [45], which he postulated was associated with pituitary hypertrophy [60]. The German physician, Oskar Minkowski, made the observation that pituitary tumours were almost invariably present in acromegaly [46, 65], but the definitive relationship between acromegaly and pituitary tumour was not confidently identified until 1909 [12, 13]. Such advances promoted interest in surgical access to the pituitary as a means of providing treatment, of relieving mass effect and thereby of improving vision and later surgical treatment of endocrine-active tumours.

J.A.J. King • A.H. Kaye (✉)

Department of Neurosurgery, The Royal Melbourne Hospital, Department of Surgery,
The University of Melbourne, Melbourne, Australia
e-mail: a.kaye@unimelb.edu.au

Surgical Approaches

Transcranial Surgery

Transcranial approaches to the pituitary predated the trans-sphenoidal operation and will be briefly discussed. Decompressive procedures were described initially followed by attempts at resection. Sir Victor Horsley (1857–1916), considered to be the first hospital-appointed “neurosurgeon” worldwide in 1886 to the National Hospital in Queen Square [49], attempted surgical resection of a pituitary adenoma via a transfrontal intracranial route in 1889, but the procedure was unsuccessful and unpublished. “My first attention to this subject was drawn by being requested in 1889 to operate on a tumour pressing on the front of the optic chiasma, and for this purpose I raised the frontal lobe, but found that the tumour was really a cystic adeno-sarcoma of the pituitary gland, and was inoperable...”. There are no records to support this surgery being performed at the National Hospital, where he was appointed, but it is suggested that it may have been performed outside the hospital [62]. The patient died a few years later with softening of the frontal lobe identified at autopsy. Horsley then published descriptions of ten procedures of both subfrontal and lateral middle fossa approaches to pituitary tumours, often performed in two stages, between 1904 and 1906, with a mortality rate of 20% [30]. This was significantly better than his peers reporting rates of 50–80% at that time [41]. Four operative records were identified from the National Hospital at Queen Square, the first describing actual tumour removal in 1903 (Michael Powell, 2015, Personal communication) [48] (Fig. 2.1).

The first published operation for pituitary pathology was that performed by Caton and Paul of the Royal Liverpool Infirmary, incorporating a lateral extradural subtemporal decompression on February 2, 1893, on a 35-year-old female patient with acromegaly, headache and severe visual loss. The tumour was not resected, and the patient died 3 months after the surgery [7].

The German surgeon-anatomist, Fedor Krause (1857–1937), chief surgeon at the Augusta Hospital at the University of Berlin in 1905 described a frontal transcranial approach to the sella [36]. Krause’s approach is stated to have been derived from a procedure he performed in 1900 to remove a bullet from the region of the anterior clinoid process in a man who have been shot 4 years earlier. After elevating an osteoplastic craniotomy flap lateral to the frontal sinus, an extradural approach was performed, until the dura was opened over the bullet. He was then able to visualise the optic nerve and the carotid artery and identified this as a potential approach to the pituitary. Krause wrote “Though the peduncle (infundibulum) of the pituitary arises from the brain behind the chiasm, the hypophysis itself lies in front, beneath its anterior edge” [37]. In 1909, Krause removed a pituitary tumour by this route. Krause subsequently made significant contributions to neurosurgery for epilepsy, trigeminal neuralgia and tumours of the cerebellopontine angle and pineal region [54] (Fig. 2.2).

The cranial approach to the pituitary underwent further modifications, primarily medial or lateral frontal intradural, as continued to be used today. Sir Walter Dandy

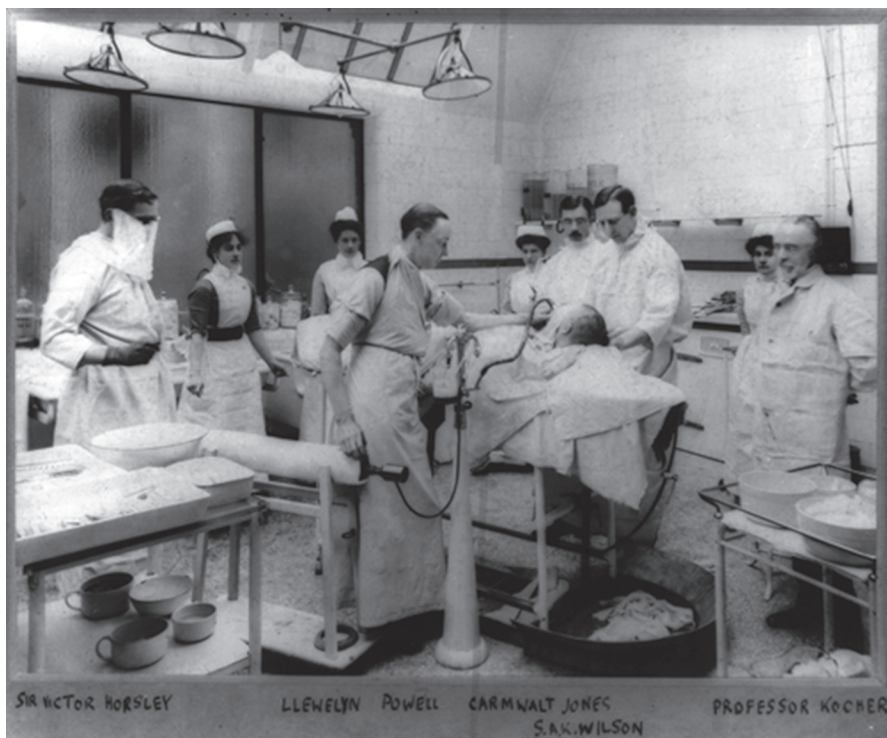


Fig. 2.1 Picture of Horsley and Kocher. Sir Victor Horsley's nineteenth century operations at the National Hospital for Neurology and Neurosurgery, Queen Square [62]. Permission required

Fig. 2.2 Photo of Fedor Krause (Reproduced from Kolle [69]. In [54]. Permission required)



(1886–1946) with Dr. George Heuer (1882–1950) described a lateral anterior fossa approach [15, 29]. Charles Frazier (1870–1936) at the University of Pennsylvania published the details of a fronto-orbital procedure which involved removal of the supraorbital ridge [19]. Harvey Cushing, perhaps the most influential neurosurgeon of the time, favoured a direct transfrontal craniotomy with a right subfrontal midline approach. He utilised this as his favoured approach to the pituitary gland from 1929 onwards. As a consequence of his stature in the field, transcranial approaches dominated until the trans-sphenoidal approach was repopularised by the efforts of Gerard Guiot and Jules Hardy as described later.

Herbert Olivecrona (1891–1980), neurosurgeon working with Rolf Luft (1914–2007), endocrinologist, at the Karolinska Institute in Stockholm in Sweden, published extensively on surgery on the pituitary gland for the treatment of Cushing's syndrome, metastatic breast and prostate cancer, diabetes mellitus and malignant hypertension [42, 43]. The approach is described in detail [42] involving a small lateral frontal flap with intradural exposure of the pituitary, division of the stalk and extirpation of the contents of the sella. Such surgery was made possible with the introduction of cortisone and other hormone replacement therapies.

Another major proponent of the transcranial approach in the mid-twentieth century was Bronson Ray (1904–1993), who served as Cushing's last resident at the Brigham from 1931 to 1932. As chief of the Department of Neurological Surgery at New York Hospital/Cornell University Medical Centre, he performed over 1500 transfrontal hypophysectomies for breast cancer and other disorders [52].

Trans-sphenoidal Surgery

The Egyptians had shown that the intracranial contents could be removed by a trans-sphenoidal route as far back as 1500–100 BC [23]. Perforations in the skull base through the ethmoid and sphenoid sinuses allowed access for a long hook to macerate the brain before removal as a part of the mummification process.

The morbidity and complication rate of transcranial surgery encountered in the late nineteenth century stimulated a search for extracranial routes to the pituitary through the paranasal sinuses. The Venetian anatomist and surgeon, Davide Giordano (1864–1954), described surgical experimentation on cadavers utilising a transnasal route to the pituitary in 1897 [2, 21]. He proposed a transglabellar approach to the pituitary involving resection of the nose and frontal sinus, followed by removal of the ethmoid bone, allowing wide access to the sphenoid sinus and sella.

It was not until Hermann Schloffer (1868–1937), as the director of surgery at the University of Innsbruck, performed removal of a pituitary adenoma in March 1907 was this approach, superior nasal trans-sphenoidal involving a lateral rhinotomy and mobilisation of the nose, used on a living patient [59]. This man was 30 years of age with a history extending over 6 years of headache and visual loss. The diagnosis was based on a radiographic image of an enlarged sella [59]. The surgery was completed after 75 min without complication. The patient successfully recovered from the operation despite 14 days of CSF rhinorrhea, only to succumb some

Fig. 2.3 Portrait of Schloffer (From Lindholm [70], public domain)



2 months after the surgery from hydrocephalus secondary to intraventricular tumour extension confirmed at autopsy [58] (Fig. 2.3).

Schloffer had undertaken extensive study of the anatomy of the paranasal sinuses and pituitary gland in his 51-page dissertation entitled *Zur Frage der Operationen an der Hypophyse* (On the Question of Surgery on the Pituitary), published in *Beiträge zur klinischen Chirurgie* in 1906 [57]. In this, Schloffer wrote “Until now, no such operation has yet been carried out on a living patient, at least none has been reported, obviously, because firstly the decision to perform such a difficult intervention bears the mark of a foolhardy novice, and is difficult even for the expert; secondly because the function of the hypophysis remains obscure and hence the consequences of extirpation of the pituitary cannot be foreseen” [57]. Schloffer performed his first such surgery 1 year later.

This procedure was refined further by Anton von Eiselsberg and Julius von Hochenegg (1859–1940) in Vienna, in 1908 who added resection of the frontal sinuses [63]. Von Eiselsberg reported five cases of meningitis (of which four were fatal) in 16 operations performed using Schloffer’s procedure [10]. The high risk of meningitis and the significant postoperative disfigurement necessitated further refinements of the technique.

The legendary Swiss surgeon and Nobel Laureate, Theodor Kocher (1841–1917) working in Berne, described the submucosal dissection of the nasal septum via a complex external incision involving the bridge of the nose in 1909 [35]. His approach provided the advance of confirmation of the midline and was less disfiguring. Kocher’s first patient was an acromegalic, and significant symptomatic improvement was documented post-surgery [39].

Ottakar Chiari, a rhinologist working in Freiburg in 1912, performed a superior trans-ethmoidal approach via the medial aspect of the orbit, which offered a shorter surgical corridor but was associated with increased risk to the anterior ethmoidal and the internal carotid arteries [8].

Oscar Hirsch

Oscar Hirsch, a Viennese rhinologist, proposed a direct trans-ethmoidal route without reflection of the nose. He performed this operation in multiple stages over up to 5 weeks, under local anaesthetic with successful visual outcomes. In June 1910, he is credited as the first to perform a submucosal trans-septal approach to the pituitary gland involving a small incision at the columella, the mucosa reflected by a nasal speculum. Subsequently, his colleague and collaborator, the neurosurgeon, Hannibal Hamlin, described Hirsch later in his career, operating with the patient “seated with the head fixed, while awake and under the influence of no other medication. The nasopharyngeal surface was cocaineized and the mucosa infiltrated by a local anaesthetic. Hirsch would sit opposite with instruments at hand. Illumination was provided by a reflective-mirrored light, and suction was supplied by a foot-pedal rig operated by a faithful dwarf (an ex-patient named Shostel)” [25].

Hirsch spent his early career in Vienna and performed the procedure for Cushing there in 1911, before moving to Boston in 1938, the year of the Anschluss [25]. Hirsch dedicated his life to trans-sphenoidal pituitary surgery. Working with Hamlin, he performed over 500 cases of pituitary surgery until retiring at 85 years of age. When the trans-sphenoidal approach had been largely abandoned in the USA and Europe, Hirsch continued to perform this procedure in a single sitting, described by Zervas as an “obscure voice in the wilderness [68]”.

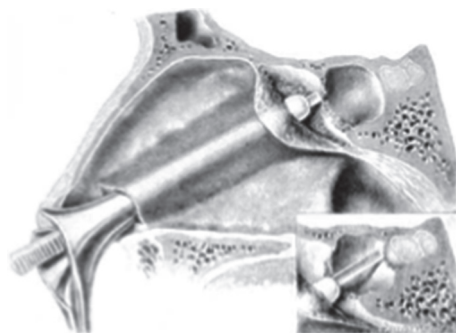A colourful description of Hirsch performing a trans-sphenoidal operation in October 1957 was published by Rovit [55] in 2002. It is illuminating and highlights the difficulties encountered by pioneering pituitary surgeons.

One incident involving Dr. Hirsch stands out in my memory. A 61-year-old woman with hypopituitarism had been followed for years by the staff of endocrine services at MGH. Skull x-ray films revealed progressive ballooning of the sella turcica. Her roentgen findings were so characteristic of an expanding pituitary tumor that they were included in the textbook *Roentgen Interpretation* by Holmes and Robbins. A pneumoencephalogram had demonstrated an intrasellar mass with suprasellar extension, and she had received two courses of radiation therapy. Despite this therapy, and while being maintained on thyroid medication and cortisone, the patient experienced bitemporal hemianopsia with decreased vision in both eyes, especially the left, and a left sixth nerve paralysis. Because of progressive visual impairment, Dr. Hirsch, assisted by Hannibal Hamlin, performed a trans-sphenoidal operation in October 1957.

In this particular case, Dr. Hirsch entered the sella floor without incident, but after a few manipulations, a sudden torrent of bright red blood gushed from the nose under arterial pressure, splashing everything in its vicinity. After the usual instantaneous profanities, Dr. Hirsch calmly said, “This is not the time to curse. This is the time to pray”. With that admonition and the loss of several hundred additional milliliters of blood, he skillfully packed the nose and the bleeding was controlled. No further bleeding was encountered when the packing was removed several days later. Subsequent angiography revealed a large internal carotid artery aneurysm that filled the sella. The patient initially did well but eventually died after an intracranial procedure with carotid ligation under hypothermia (Fig. 2.4).

Albert Halstead (1868–1926) of Chicago in 1910 subsequently described the sublabial gingival incision, a modification of the inferior rhinotomy approach of Allen Kanavel, improving access with a reduction in the postoperative defect [24, 34]. This technique was later to be adopted by Cushing.

Fig. 2.4 Drawing of Hirsch's endonasal, submucosal and trans-septal approach to the sella (Reproduced from a slide in Dr. Laws' collection. From Lanzino and Laws [39]. Permission required)



Harvey Cushing

Cushing's early experience of transcranial surgery for pituitary tumours at Johns Hopkins in Baltimore in 1905 was discouraging, and an alternative was sought. Cushing's first trans-sphenoidal patient was a 38-year-old farmer with acromegaly, undergoing surgery involving a tracheostomy, followed by a forehead flap incision to access the paranasal sinuses and sella, on March 25, 1909, under ether-based anaesthesia [9]. Cushing performed his first sublabial trans-septal excision of a pituitary tumour in Boston, it is said on the same day as Hirsch's operation, June 4, 1910, and the two corresponded regarding these procedures [39]. Cushing added the use of a sea sponge placed in the nasopharynx to prevent blood entering the oesophagus and topical adrenaline to assist with haemostasis. By World War I, Cushing had performed over 50 trans-sphenoidal cases, over 20% of his total operations.

Cushing primarily utilised a sublabial submucosal trans-septal approach under intratracheal general anaesthesia, adopting innovations from Allen Kanavel (1874–1938) and Albert Halstead (1868–1926) from Chicago and Theodor Kocher from Berne [13, 14]. In total, Cushing performed 74 pituitary operations at the Johns Hopkins Hospital, followed by 338 hypophysectomies in Boston.

During this period, a significant advance in the diagnosis and surgery for pituitary tumours was the development of pneumoencephalography in 1919 [16]. This for the first time allowed the surgeon to gain preoperative awareness of the presence of suprasellar tumour extension.

Cushing was able to demonstrate a mortality rate of 5.6% in his 231 pituitary trans-sphenoidal cases from 1910 to 1925 [28]. Despite this, Cushing abandoned the trans-sphenoidal approach in 1929 in favour of the transfrontal procedure, particularly when the sella was not enlarged, citing better visual outcomes with craniotomy, better ability to deal with unexpected pathology and greater ease at reoperation. As a consequence of his stature in the field, the majority of neurosurgeons followed his lead (Fig. 2.5).

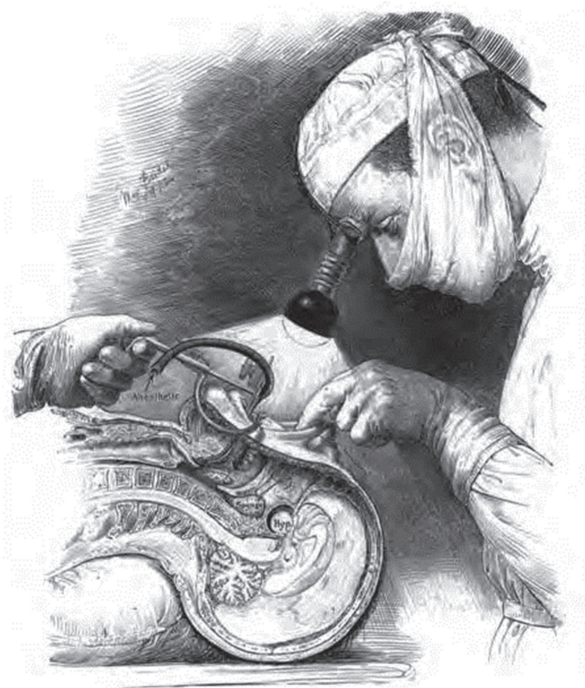

Fig. 2.5 Drawing of Cushing performing trans-sphenoidal surgery (From Cushing [14]. Permission required)

Norman Dott

Norman Dott (1897–1973) was the exception. Norman Dott was born in Edinburgh in 1897, attending medical school in that city and becoming a resident at the Royal Infirmary of Edinburgh where he was awarded the Fellowship of the Royal College of Surgeons of Edinburgh. Upon being awarded the Rockefeller Fellowship, Dott spent 6 months from November 1923 as Cushing's assistant at the Peter Bent Brigham Hospital in Boston. There he came to observe the sublabial trans-sphenoidal procedure and published in 1925 with Percival Bailey a report of Cushing's 196 patients with pituitary tumours [17].

Dott continued to perform trans-sphenoidal surgery at the Royal Infirmary in Edinburgh and by 1956 had performed 120 such operations. He further developed a lighted speculum retractor to facilitate better visualisation of critical structures at the depth of the surgical exposure.

Dr. J.F. Shaw describes the atmosphere of Dott's operating room. "Now watch Dott carrying out a typical pituitary operation. The patient, lying supine, is covered overall by surgical drapes: only the nose and the mouth are exposed. Dott leans over this area with a headlight on and every now and then adjusts the position of the long

malleable light, held by the assistant. Anxiety lies in the narrowly exposed eye of his assistant who is responsible for maintaining the correct position of this light but can only fleetingly see the deep operation site as he peers first one way then another around Dott's neck and hands. Sister too looks anxious, especially when she sees the light starts to flicker and go out, which, test it as you may before the operation, seems unfailingly to occur at least once during the crucial period.

How Dott would have appreciated the convenience of transaxial illumination of the operating microscope, which was denied him by a matter of years. Sister can see even less of the operating field than the assistant and the confident way she slaps the instruments into Dott's outstretched hand comes only from years of experience and the ability to deduce the stage of the operation from sound and hand movements. She too, in company with the small group of hopeful postgraduate students hovering behind the assistant, seeing little but hanging eagerly on any word or gesture, would have appreciated the modern microscope with its television facility; all would have been shown so clearly, on a nearby screen. So approximately 90 min pass to the noise of the sucker, or of instruments against bone, the silence of soft tissue, the occasional, sometimes testy interjection. Then Dott packs the nose and strips off his gloves. His assistants have been privileged by an occasional fleeting glance of the vital areas" [56].

Dott never published his trans-sphenoidal results, some suggesting this was out of deference to his mentor, Cushing (Fig. 2.6).

During the period of preoccupation of the neurosurgical community with transcranial approaches, otolaryngologists introduced microsurgical trans-ethmoidal hypophysectomy. These were predominantly performed for advanced cancer. Lennart Gisselsson is credited as the first, in Sweden in 1957 using Chiari's approach [65], followed by Niels Riskaer in Copenhagen in 1958. Riskaer published his series of 47 patients with breast cancer in 1961 [53]. Geoffrey Bateman, Ronald Macbeth and John James, all based in England, popularised the technique, describing the use of the drill for poorly pneumatized sphenoid sinus and reduction of cerebrospinal fluid leak by packing of the sphenoid sinus with muscle and fascia.

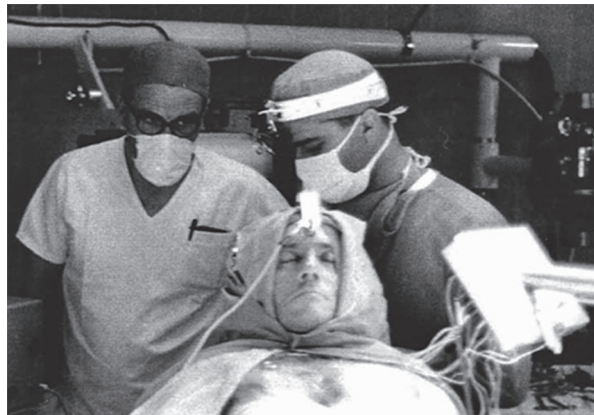Gerard Guiot

Gerard Guiot (1912–1998) was instrumental in the reintroduction of the trans-sphenoidal procedure to the neurosurgical community. Gerard Guiot was born in Fourmies in 1912, in Northern France, and graduated from the medical school of Paris in 1937. Guiot trained in neurosurgery under Professor R. Garcin in Paris and also influenced by Clovis Vincent. In 1956, Guiot founded the Department of Neurosurgery at l'Hopital Foch. It was in the same year that Guiot visited Norman Dott in Edinburgh as an observer and was impressed by his use of the trans-sphenoidal technique. "During those two weeks I saw Professor Dott operating two pituitary tumors by the transsphenoidal route. And I remember Pr. Dott telling me the day after: 'look at the postoperative campimetry! The patient is already improved'...he showed me his statistics: no mortality for his last 80 cases.... I was convinced" [39].

Fig. 2.6 Photo portrait of Norman Dott by Grace Allison, a former patient who had been treated by Dott for a pituitary tumour (Rush and Shaw [56]. Permission required)




Fig. 2.7 Photograph of Jules Hardy and Gerard Guiot (Reprinted from *Transsphenoidal Surgery*, Laws, ER, Lanzino, G, "History of Transsphenoidal Surgery for Pituitary Tumours" Lanzino, G, Catapano D, and Laws ER, permission required from Elsevier)



Guiot was an innovator and made many significant contributions to neurosurgery including intraventricular endoscopy and stereotaxy, but to pituitary surgery, he added the use of fluoroscopy [38]. Combined with lumbar spinal drain insertion for the administration of air and contrast, Guiot demonstrated greater safety of the trans-sphenoidal approach and the ability to resect those tumours with greater suprasellar extension. His series of pituitary surgery included more than 1500 pituitary adenomas of which more than 200 were performed with fluoroscopic guidance [40]. Significantly he mentored a young French Canadian surgeon, Jules Hardy, who popularised the procedure again in North America (Fig. 2.7).

Jules Hardy

Jules Hardy (1932-) from Quebec trained at the Montreal Neurological Institute and underwent fellowship training with Guiot in Paris in 1961–1962. Hardy introduced trans-sphenoidal surgery to the Notre Dame Hospital at the University of Montreal in 1962 stating “My very first patient had a very large tumor with a supra-sellar expansion; he was blind from one eye and had hemianopsia on the other. I therefore performed a sub-total debulking as Guiot taught me and the patient's vision improved rapidly”. Hardy routinely used preoperative angiography and intraoperative air encephalography. Hardy further refined the use of videofluoroscopy “...the major advantage of fluoroscopy was the monitoring of the instrumental manoeuvres on the television screen while removing large pituitary tumors with suprasellar extension. Intermittent views during the progressive descent of the tumor dome, monitored by air injection through the lumbar route or by direct visualization with contrast solution perfusion, afford immediate intraoperative live imaging of the tumor removal...” [26].

Perhaps Hardy's greatest contribution to the field was the introduction of the operative microscope in 1965 to overcome the long encountered difficulties of lighting and vision in trans-sphenoidal surgery. Hardy described the use of the microscope in a case of hypophysectomy for breast cancer on October 13, 1965, and subsequently stated, “at higher magnification I was able to distinguish in some cases the residual normal pituitary gland quite separate from the tumoral tissue. As a result I decided to make all effort to preserve the pituitary to prevent new deficits. This was successful and even more we observed restoration of functions after tumor removal due to relief of pressure upon the normal gland”. Hardy reported no deaths or major morbidity in his first 50 microscopic cases [65].

Hardy developed specific instrumentation for the trans-sphenoidal approach and was the first to describe surgery for endocrine-active microadenomas in 1968 which was met with controversy amongst the wider neurosurgical community [61]. Hardy recalls the comment of Bronson Ray “I would like to discourage any effort to revive this old ancient procedure through the nose presented by this young surgeon; the results are not any better than by the intracranial procedure...” [27].

The trans-sphenoidal procedure was then championed by prominent figures in the neurosurgical community, including Edward Laws, Tsutomu Kato, Charles Wilson, Edward Oldfield, Rudolf Fahlbusch and Giorgio Frank. Of these, Edward Laws has performed over 6000 trans-sphenoidal operations, adopting the fully endoscopic approach later in his career, and founder of the International Society of Pituitary Surgeons who first met in Boston in 1983. The development of immunohistochemistry driving better understanding of the pathology and advances in radiology with CT and MRI were critical to surgical progress during this time [66].

Image Guidance and Intraoperative MRI

Fluoroscopy as popularised by Guiot and Hardy has continued to be used to the present day, particularly by microscopic pituitary surgeons, as it affords real-time intraoperative imaging. Frameless stereotaxy/neuronavigation has been widely

adopted and has an important role in patients with complex anatomy and in reoperation but lacks the real-time facility and can be associated with registration error. The use of the endoscope, which affords a panoramic view within the sphenoid and sella, has, to some extent, reduced the reliance on intraoperative imaging. Both ultrasound [3, 51] and microvascular Doppler ultrasonography [18] have been applied to improve the safety of extended endoscopic approaches involving bony removal over the carotid arteries and in tumour removal from the cavernous sinus. Additionally microvascular Doppler has been described as useful in the assessment of the viability of a pedicled nasal septal flap in redo surgery [47].

The evolution of imaging in pituitary surgery has more recently incorporated intraoperative MRI [4, 5]. Proponents of the procedure have documented improved gross total resection rates with iMRI and longer disease-free intervals [4, 5]. The uptake of this technology has been limited. This procedure has been found by some to be cumbersome, costly and perhaps less helpful following refinements in the endoscopic technique. The interpretation of intraoperative images can also be difficult due to image artefact.

Endoscopic Pituitary Surgery

Guiot is credited as the first to describe the use of the endoscope in trans-sphenoidal pituitary surgery in 1963 [22]. The initial descriptions involved use of the endoscope as an adjunct to microscopic approaches [1], until Jankowski from the University of Nancy [31] described the first fully endoscopic sublabial approach to the pituitary in 1992. Hae-Dong Jho and Ricardo Carrau, working at the University of Pittsburgh Medical Centre, are considered pioneers of the pure endoscopic endonasal approach and amongst the founders of modern endoscopic pituitary surgery. Jho describes the development of the procedure in 1993 and in 1997 reported on the first 50 patients treated in this way [32].

Paolo Cappabianca and Enrico De Divitiis from the University of Naples made major contributions to the field of purely endoscopic pituitary surgery, with the development of equipment, evaluation of results and use of extended techniques [6].

Endoscopic pituitary surgery has grown in popularity over the last 20 years with the development of higher-definition camera systems, improved instrumentation and greater acceptance of the technique. Collaboration with otolaryngologists has become a common practice with the development of three- and four-handed surgical techniques. A number of groups have popularised the technique, Kassam and Snyderman, Schwartz and Anand, and others [50].

Extended Trans-sphenoidal Surgery

Both microscopic and endoscopic trans-sphenoidal procedures have been expanded to address parasellar, anterior fossa and clival pathologies [44]. The transplanum approach was described by Weiss in 1987 [64] for the removal of suprasellar lesions.

In 2004, Couldwell reported 105 cases of extended trans-sphenoidal approaches allowing access to the cavernous sinus, suprasellar and clival region [11].

The pure endoscopic technique has been employed to access the skull base from the cribriform plate down to the foramen magnum and odontoid and as far lateral as the foramen ovale [33].

Conclusion

The continuous development and refinement seen in pituitary surgery over the last century will inevitably continue into the future. Three-dimensional endoscopic systems as an advance on widely available 2D systems of today are gaining acceptance, and perhaps the most exciting potential development is the use of robotics [20]. Pituitary surgery would seem well suited to the use of robotics integrated with neuronavigation and other potential adjuncts to resection such as ICG, to facilitate access and vision in deep locations, even potentially to perform procedures remotely [67]. From near abandonment, the future of trans-sphenoidal pituitary surgery looks assured.

References

1. Apuzzo ML, Heifetz MD, Weiss MH, Kurze T. Neurosurgical endoscopy using the side-viewing telescope. *J Neurosurg.* 1977;46(3):398–400.
2. Artico M., Pastore FS, Fraioli B, Giuffrè R. The contribution of Davide Giordano (1864–1954) to pituitary surgery: the translabellar-nasal approach. *Neurosurgery.* 1998;42(4):909–11; discussion 911–2.
3. Atkinson JL, Kasperbauer JL, James EM, Lane JJ, Nippoldt TB. Transcranial-transdural real-time ultrasonography during transsphenoidal resection of a large pituitary tumor. Case report. *J Neurosurg.* 2000;93(1):129–31.
4. Berkmann S, Schlaffer S, Nimsky C, Fahlbusch R, Buchfelder M. Follow-up and long-term outcome of nonfunctioning pituitary adenoma operated by transsphenoidal surgery with intraoperative high-field magnetic resonance imaging. *Acta Neurochir.* 2014;156(12):2233–43; discussion 2243.
5. Berkmann S, Schlaffer S, Nimsky C, Fahlbusch R, Buchfelder M. Intraoperative high-field MRI for transsphenoidal reoperations of nonfunctioning pituitary adenoma. *J Neurosurg.* 2014;121(5):1166–75.
6. Cappabianca P, Alfieri A, de Divitiis E. Endoscopic endonasal transsphenoidal approach to the sella: towards functional endoscopic pituitary surgery (FEPS). *Minim Invasive Neurosurg.* 1998;41(2):66–73.
7. Caton R, Paul FT. Notes of a case of acromegaly treated by operation. *Br Med J.* 1893;2:1421–3.
8. Chiari O. Ueber eine Modifikation der Schlofferschen Operation von Tumoren der Hypophyse. *Wien Klin Wochenschr.* 1912;25:5.
9. Cohen-Gadol AA, Liu JK, Laws Jr ER. Cushing's first case of transsphenoidal surgery: the launch of the pituitary surgery era. *J Neurosurg.* 2005;103(3):570–4.
10. Cope V. The pituitary fossa, and the methods of surgical approach thereto. *Br J Surg.* 1916;4:107–44.
11. Couldwell WT, Weiss MH, Rabb C, Liu JK, Apfelbaum RI, Fukushima T. Variations on the standard transsphenoidal approach to the sellar region, with emphasis on the extended

- approaches and parasellar approaches: surgical experience in 105 cases. *Neurosurgery*. 2004;55(3):539–547; discussion 547–50.
12. Cushing H. The hypophysis cerebri: clinical aspects of hyperpituitarism and of hypopituitarism. *JAMA*. 1909;53:249–55.
 13. Cushing H. The pituitary body and its disorders: clinical status produced by disorders of the hypophysis cerebri. Philadelphia: JB Lippincott; 1912.
 14. Cushing H. The Weir Mitchell lecture. Surgical experiences with pituitary disorders. *JAMA*. 1914;63:1515–25.
 15. Dandy W. A new hypophysis operation. *Bull Johns Hopkins Hosp*. 1918;29:154.
 16. Dandy W. Roentgenography of the brain after the injection of air into the spinal canal. *Ann Surg*. 1919;70:397–403.
 17. Dott NB, Bailey P. A consideration of the hypophyseal adenomata. *Br J Surg*. 1925;13:314–66.
 18. Dusick JR, Esposito F, Malkasian D, Kelly DF. Avoidance of carotid artery injuries in transsphenoidal surgery with the Doppler probe and micro-hook blades. *Neurosurgery*. 2007;60(4 Suppl 2):322–28; discussion 328–9.
 19. Frazier C. An approach to the hypophysis through the anterior cranial fossa. *Ann Surg*. 1913;57:145–50.
 20. Gilbert H, Hendrick R, Remirez A, Webster 3rd R. A robot for transnasal surgery featuring needle-sized tentacle-like arms. *Expert Rev Med Devices*. 2014;11(1):5–7.
 21. Giordano D. *Compendio di chirurgia operatoria*. Torino: Unione Tipografico-Editrice Torinese; 1897. p. 101–4.
 22. Guiot G, Rougerie J, Fourestier A, et al. Une nouvelle technique endoscopique. Exploration endoscopiques intracraniennes. *La Presse Medicale*. 1963;71:1225–8.
 23. Haase S, Pirsig W, Parsche F. Surgical findings in an Egyptian mummy's skull. *Dtsch Z Mund Kiefer Gesichtschir*. 1991;15(2):156–60.
 24. Halstead A. Remarks on the operative treatment of tumors of the hypophysis. With the report of two cases operated on by the oronasal method. *Trans Am Surg Assoc*. 1910;28:73–93.
 25. Hamlin H. Oskar Hirsch. *Surg Neurol*. 1981;16(6):391–3.
 26. Hardy J. Neuronavigation in pituitary surgery. *Surg Neurol*. 1999;52:648–9.
 27. Hardy J. History of pituitary surgery. *Neurochirurgie*. 2010;56(4):358–62.
 28. Henderson W. The pituitary adenomata. A follow-up study of the surgical results in 338 cases (Dr Harvey Cushing's series). *Br J Surg*. 1939;26:811–921.
 29. Heuer G. The surgical approach and the treatment of tumors and other lesions about the optic chiasm. *Surg Gynecol Obstet*. 1931;53:489–518.
 30. Horsley V. On the technique of operations on the central nervous system. *BMJ*. 1906;2:411–23.
 31. Jankowski R, Auque J, Simon C, Marchal JC, Hepner H, Wayoff M. Endoscopic pituitary tumor surgery. *Laryngoscope*. 1992;102(2):198–202.
 32. Jho HD, Carrau RL. Endoscopic endonasal transsphenoidal surgery: experience with 50 patients. *J Neurosurg*. 1997;87(1):44–51.
 33. Kassam AB, Gardner P, Snyderman C, Mintz A, Carrau R. Expanded endonasal approach: fully endoscopic, completely transnasal approach to the middle third of the clivus, petrous bone, middle cranial fossa, and infratemporal fossa. *Neurosurg Focus*. 2005;19(1):E6.
 34. Kennedy DW, Cohn ES, Papell ID, Holliday MJ. Transsphenoidal approach to the sella: the Johns Hopkins experience. *Laryngoscope*. 1984;94(8):1066–74.
 35. Kocher T. Ein Fall von Hypophysis tumor mit operativer Heilung. *Dtsch Z Chir*. 1909;100:13–37.
 36. Krause F. *Hirnehirurgie*. *Dtsch Klin*. 1905;8:953–1024.
 37. Krause F. *Surgery of the brain and spinal cord, based on personal experiences*, vol. 1–3. New York: Rebman; 1909–1912.
 38. Krisht KM, Sorour M, Cote M, Hardy J, Couldwell WT. Marching beyond the sella: Gerard Guiot and his contributions to neurosurgery. *J Neurosurg*. 2015;122(2):464–72.
 39. Lanzino G, Laws Jr ER. Pioneers in the development of transsphenoidal surgery: Theodor Kocher, Oskar Hirsch, and Norman Dott. *J Neurosurg*. 2001;95(6):1097–103.

40. Lanzino G, Laws ER, Feiz-Erfan I, White W. Transsphenoidal approach to lesions of the sella turcica: historical overview. *Barrow Q.* 2002;18:4–8.
41. Liu JK, Das K, Weiss MH, Laws Jr ER, Couldwell WT. The history and evolution of trans-sphenoidal surgery. *J Neurosurg.* 2001;95(6):1083–96.
42. Luft R, Olivecrona H. Experiences with hypophysectomy in man. *J Neurosurg.* 1953;10(3):301–16.
43. Luft R, Olivecrona H. Hypophysectomy in the management of neoplastic disease. *Bull N Y Acad Med.* 1957;33(1):5–16.
44. Magrini S, Pasquini E, Mazzatenta D, Mascari C, Galassi E, Frank G. Endoscopic endonasal odontoidectomy in a patient affected by Down syndrome: technical case report. *Neurosurgery.* 2008;63(2):E373–74; discussion E374.
45. Marie P. Sur deux cas d'acromégalie: hypertrophie singulière non congénitale, des extrémités supérieures, inférieures, et ceph-alique. *Rev Med Liege.* 1886;6:297–333.
46. Minkowski O. On a case of acromegaly [In German]. *Berlin Klin Wochenschr.* 1887;24:371–4.
47. Pinheiro-Neto CD, Carrau RL, Prevedello DM, Fernandez-Miranda JC, Snyderman CS, Gardner PA, Kassam AB. Use of acoustic Doppler sonography to ascertain the feasibility of the pedicled nasoseptal flap after prior bilateral sphenoidotomy. *Laryngoscope.* 2010;120(9):1798–801.
48. Pollock JR, Akinwunmi J, Scaravilli F, Powell MP. Transcranial surgery for pituitary tumors performed by Sir Victor Horsley. *Neurosurgery.* 2003;52(4):914–25; discussion 925–6.
49. Powell M. Sir Victor Horsley – an inspiration. *BMJ.* 2006;333(7582):1317–9.
50. Prevedello DM, Doglietto F, Jane Jr JA, Jagannathan J, Han J, Laws Jr ER. History of endoscopic skull base surgery: its evolution and current reality. *J Neurosurg.* 2007;107(1):206–13.
51. Ram Z, Bruck B, Hadani M. Ultrasound in pituitary tumor surgery. *Pituitary.* 1999;2(2):133–8.
52. Ray B, Pearson OH. Hypophysectomy in the treatment of advanced cancer of the breast. *Ann Surg.* 1956;144:394–403.
53. Riskaer N, Fog CV, Hommelgaard T. Transsphenoidal hypophysectomy in metastatic cancer of the breast. *Arch Otolaryngol.* 1961;74:483–93.
54. Rosegay H. The Krause operations. *J Neurosurg.* 1992;76(6):1032–6.
55. Rovit RL. Transsphenoidal surgery. *J Neurosurg.* 2002;96(6):1159–60; author reply 1160.
56. Rush CS, Shaw JF. With sharp compassion. Norman Dott: Freeman surgeon of Edinburgh. Edinburgh: Aberdeen University Press; 1990.
57. Schloffer H. Zur Frage der Operationen an der Hypophyse. *Beitr Klin Chir.* 1906;50:767–817.
58. Schloffer H. Erfolgreiche Operation eines Hypophysentumors auf nasalem Wege. *Wien Klin Wochenschr.* 1907;20:621–4.
59. Schmidt RF, Choudhry OJ, Takkellapati R, Eloy JA, Couldwell WT, Liu JK. Hermann Schloffer and the origin of transsphenoidal pituitary surgery. *Neurosurg Focus.* 2012;33(2):E5.
60. Souza-Leite J. De l'Acromégalie. *Maladie de Marie.* These de Paris; 1890.
61. Thanabalasingham G, Karavitaki N, Cudlip S, Wass JA. Treatment of pituitary tumors: history. *Endocrine.* 2005;28(1):3–8.
62. Uff C, Frith D, Harrison C, Powell M, Kitchen N. Sir Victor Horsley's 19th century operations at the National Hospital for neurology and neurosurgery, Queen Square. *J Neurosurg.* 2011;114(2):534–42.
63. von Eiselberg A. The operative cure of acromegaly by removal of a hypophysial tumor. *Ann Surg.* 1908;48:739–47.
64. Weiss M. Transnasal transsphenoidal approach. Baltimore: Williams and Wilkins; 1987.
65. Welbourn RB. The evolution of transsphenoidal pituitary microsurgery. *Surgery.* 1986;100(6):1185–90.
66. Wilson CB. A decade of pituitary microsurgery. The Herbert Olivecrona lecture. *J Neurosurg.* 1984;61(5):814–33.

67. Wirz R, Torres LG, Swaney PJ, Gilbert H, Alterovitz R, Webster RJ 3rd, Weaver KD, Russell PT 3rd. An experimental feasibility study on robotic endonasal telesurgery. *Neurosurgery*. 2015;76(4):479–84; discussion 484.
68. Zervas NT. Reflections on the surgery of the pituitary. *Clin Neurosurg*. 1980;27:124–32.
69. Kolle K, editor. *Gross Nervenarzie*. Stuttgart: Thieme; 1963. p. 199–206.
70. Lindholm J. A century of pituitary surgery: Schloffer's legacy. *Neurosurgery*. 2007;61:865–8.

Transsphenoidal Surgery

Complication Avoidance and Management Techniques

Laws Jr., E.R.; Cohen-Gadol, A.; Schwartz, T.H.; Sheehan,
J.P. (Eds.)

2017, XVII, 629 p. 215 illus., 125 illus. in color.,

Hardcover

ISBN: 978-3-319-56689-4