
Abstract

Patient Positioning and Ports Placement are important to laparoscopic liver resection. Ports placement for this procedure requires careful preoperative planning based on the anatomic location of the hepatic lesion. We suggest three different positions according to the lesion site.

Patient Positioning and Ports Placement are important to laparoscopic liver resection. Ports placement for this procedure requires careful preoperative planning based on the anatomic location of the hepatic lesion. We suggest three different positions according to the lesion site.

2.1 Patient Position

2.1.1 The First Position: Reverse Trendelenburg Position

The patient is placed in supine position with a 20-degree reverse-Trendelenburg adjustment, which is suitable for the majority of laparoscopic liver surgery (Fig. 2.1).

Methods: The surgeon stands on the opposite side of the lesion (e.g., if lesion in the left lateral lobe, the surgeon stands on the right side of the patient). The first assistant stands on the other side of the patient. This position is appropriate for the majority of laparoscopic liver surgery, such as local hepatectomy, left lateral lobectomy, left hemihepatectomy, etc.

2.1.2 The Second Position: Lithotomy Position

Methods: The patient is placed in the supine position, with lower limbs apart (Figs. 2.2 and 2.3), the surgeon stands between the legs with one assistant on each side. We use this position in single-port laparoscopic surgery.

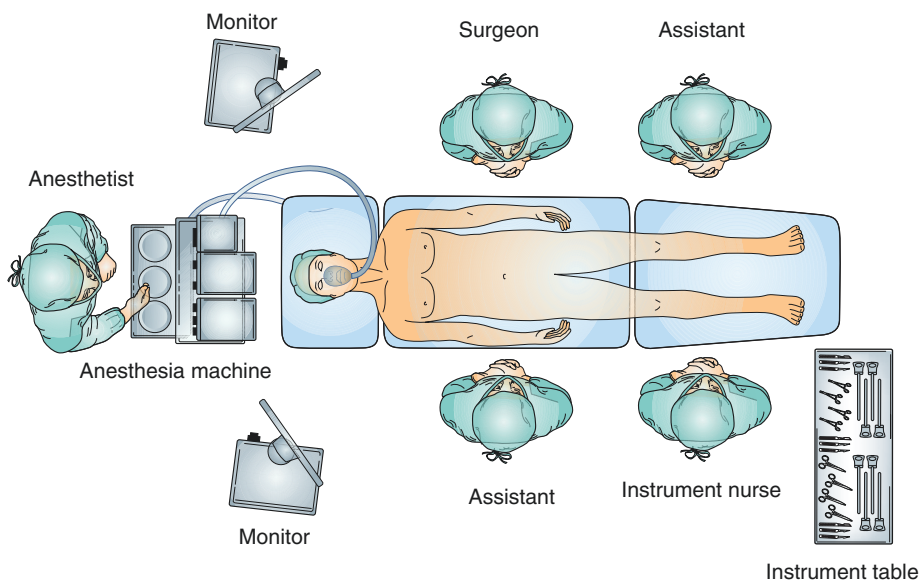


Fig. 2.1 Operating room setup of reverse Trendelenburg position

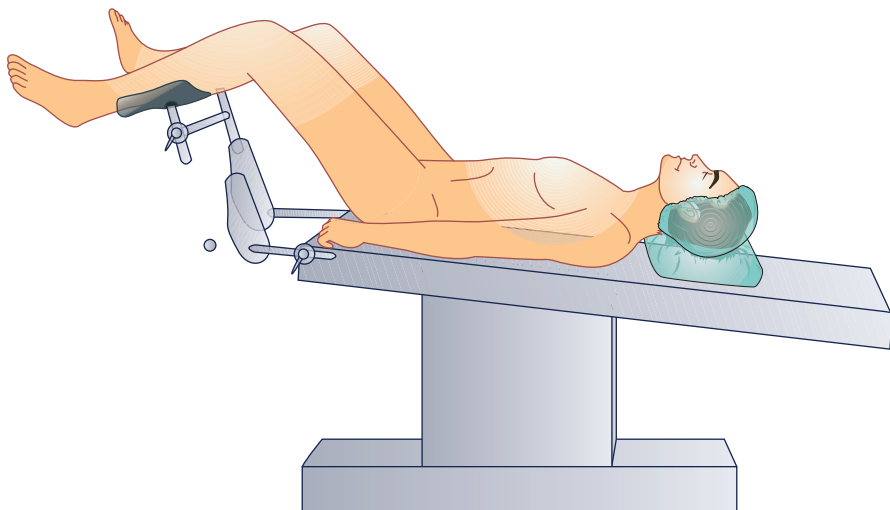
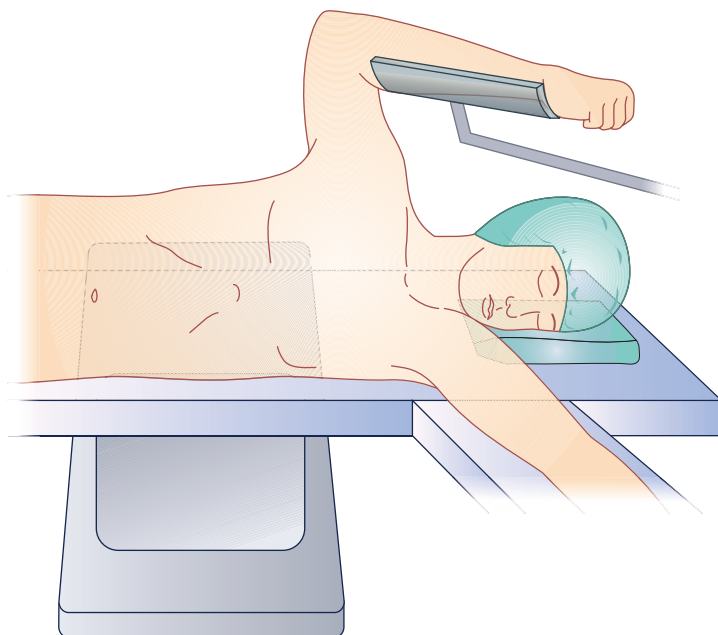
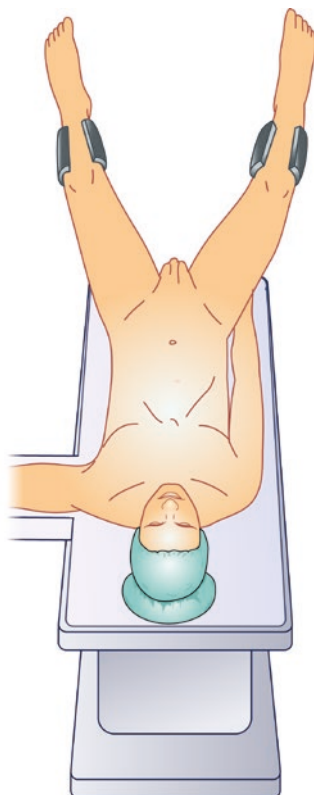


Fig. 2.2 The side view of lithotomy position

2.1.3 The Third Position: Left Lateral Decubitus Position

The left lateral decubitus position with a steep reverse Trendelenburg position is ideal for lesions in the right lobe—particularly those requiring mobilization of the right lobe to gain access to the posterior surface (Fig. 2.4).

Fig. 2.3 The front view of lithotomy position**Fig. 2.4** The side view of left lateral decubitus position

2.2 Principle of Trocar Positioning

Positioning of port sites is different according to the tumor site. When the patient is placed in position, pneumoperitoneum is achieved through a Veress needle under the umbilicus to insufflate the peritoneal cavity to 14 mmHg. A first 10-mm trocar is then placed under the umbilicus for laparoscope. The other two 12-mm trocars are located in the upper abdomen, according to the location of the tumor. Besides the two 12-mm trocars, a 5-mm trocar is then placed assisting in organ exposure, traction, and suction.

2.2.1 Left Lateral Lobectomy and Left Hemihepatectomy

The surgeon stands on the right side of the patient, and the first main operating port is located on the junction between the right midclavicular line and 4 cm below the costal margin. The second main operating port position is located on the junction between the left midclavicular line and a little bit below the costal margin. On the left side of the anterior axillary line to establish assistant operation hole for 5 mm trocar (Fig. 2.5).

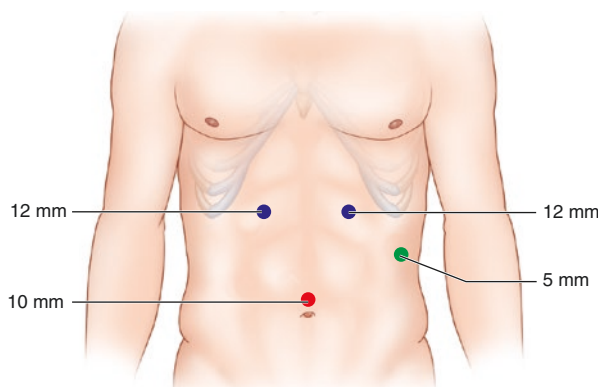
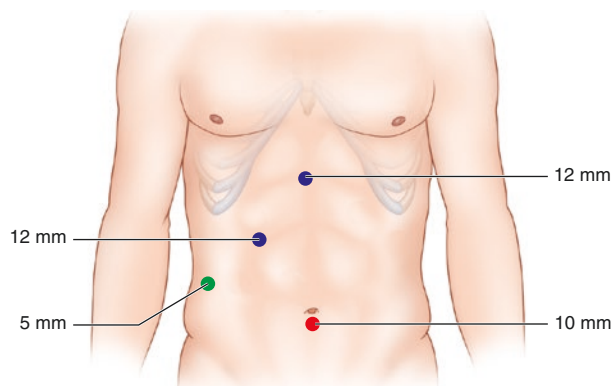


Fig. 2.5 Port position for left lateral lobectomy and left hemihepatectomy

Fig. 2.6 Port position for right posterior lobectomy



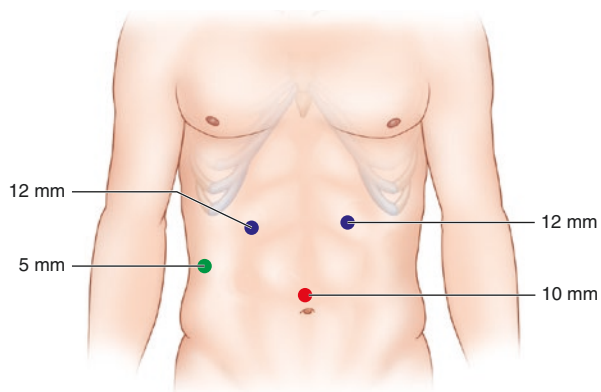
2.2.2 Right Posterior Lobectomy

The surgeon stands on the left side of the patient, and the first main operating port is located on the junction between the right midclavicular line and 4 cm below the costal margin. The second main operating port position is located below xiphoid bone. On the right anterior axillary line and 4 cm above the level of umbilicus, a 5 mm trocar is then introduced to establish an assistant operating port (Fig. 2.6).

2.2.3 Right Hemihepatectomy

The surgeon stands on the left side of the patient, and the first main operating port is located on the junction between the right midclavicular line and 4 cm below the costal margin. The second main operating port is located on the junction between the left midclavicular line and a little bit below the costal margin. On the right anterior axillary line and 4 cm above the level of umbilicus, a 5 mm trocar is introduced to establish an assistant operating port (Fig. 2.7).

Fig. 2.7 Port position for right hemihepatectomy



Laparoscopic Liver Resection

Theory and Techniques

Liu, R.

2017, X, 107 p. 16 illus., 7 illus. in color., Hardcover

ISBN: 978-94-017-9734-4