

Endoscopic Recanalization Techniques

Jan Krahn and Axel Eickhoff

- 2.1 Introduction – 26**
- 2.2 Dilation Techniques – 27**
 - 2.2.1 Bougienage – 27
 - 2.2.2 Dilation – 30
- 2.3 Stenting – 34**
- 2.4 Thermal Procedures for Recanalization/ Ablation – 38**
 - 2.4.1 Argon Plasma Coagulation – 38
 - 2.4.2 Nd:Yag Laser – 40
 - 2.4.3 Photodynamic Therapy – 41
 - 2.4.4 Cryoablation – 41
 - 2.4.5 Radiofrequency Ablation – 42
- 2.5 Zenker's Diverticulotomy – 42**
- 2.6 Peroral Endoscopic Myotomy – 44**
- References – 46**

This chapter describes the large variety of endoscopic techniques that are available to reestablish or maintain luminal patency in the gastrointestinal tract. A comprehensive portrayal of various procedures is complemented by a concise overview of their respective indications and clinical outcomes. Since achalasia as well as Zenker's diverticula can pose a significant obstruction of passage in the upper GI (gastrointestinal) tract, advanced techniques such as endoscopic diverticulotomy or peroral endoscopic myotomy are depicted in this chapter as well. Endoscopic ablation techniques are described because of their impact on prognosis and recurrence rates of endoluminal tumors, thereby playing a significant role in maintaining patency of different segments of the gastrointestinal tract.

2.1 Introduction

■ Historical Aspects

Medical recanalization procedures were already being used in ancient times. For example, the dilation of urethral strictures was achieved with the help of feathers or papyrus stalks in ancient Egypt.

Girolamo Fabrizi d'Acquapendente reported the blind intubation of the esophagus with wax tapers in the sixteenth century, mainly as a treatment for food impactions and foreign bodies in the esophagus (French «bougie»: wax candle).

Sir Thomas Willis is usually credited with the first successful «bougienage» of the lower esophageal sphincter in an achalasia patient in 1672, which was performed using a whale bone with a sponge fixed to its apex.

The first esophageal stenting was reported by Sir Charles Symonds, who used an indwelling boxwood tube (which was fixed with strings emerging through the nose and tied behind the ears) in 1885.

In 1914 Guisez et al. performed the first tube implantations under endoscopic guidance, employing rigid esophagoscopy and Seldinger technique.

The remarkable technical progress in flexible endoscopy and minimally invasive therapy since the mid-twentieth century has now created a

broad armamentarium of endoscopic recanalization techniques that are available to use in the gastrointestinal tract.

■ Epidemiology/Pathogenesis

Stenosis might occur anywhere throughout the gastrointestinal tract, and its pathogenesis can be categorized into mechanical/structural and neuromuscular/functional mechanisms.

Due to the marked heterogeneity in causes and localizations of gastrointestinal stenoses, data regarding epidemiology are extremely variable with regard to different etiologies and also change in the course of time. For example, the rate of peptic stenosis as a reason for food bolus impaction has declined from 75% to 41% since the turn of the millennium. At the same time, a rising prevalence of eosinophilic esophagitis was noted (Mahesh et al. 2013).

Causes of Gastrointestinal Obstruction

Mechanical/Structural

- Inflammatory strictures/scarring (e.g., Crohn's disease, primary sclerosing cholangitis (PSC), autoimmune cholangiopathy, radiation-induced or peptic stricture)
- Schatzki ring
- Postoperative/anastomotic stricture
- Neoplastic stricture
- Extrinsic compression
- Eosinophilic esophagitis

Neuromuscular/Functional

- Achalasia
- Sphincter of Oddi dysfunction

■ Clinical Symptoms

The clinical manifestations of symptomatic stenoses are as variable as its possible localizations and its dynamics of obstruction. For instance, the development of increasing dysphagia, regurgitations, and eventually loss of weight are the typical symptoms of progressing achalasia. Painless jaundice may be a harbinger of neoplastic biliary obstruction because of its slow progression, whereas colicky pain and cholangitis typically indicate more acute obstructions.

2.2 Dilation Techniques

Flexible bougie and balloon dilators are both used to treat strictures throughout the gastrointestinal tract. In gastroenterology, the term dilation refers to the application of balloon dilators, whereas bougienage describes the usage of bougies.

The balloon dilators exert radial force along the length of the stricture, thereby achieving dilation by tearing of tissue. Bougie dilators additionally produce axial shear forces, while the tapered end of the bougie is passing the stricture.

For various parameters that are of practical interest, e.g., the value and duration of maximal balloon pressure or time between repeat dilations, divergent recommendations exist by different work groups. On the basis of the available evidence, most of these recommendations appear to produce the same results.

2.2.1 Bougienage

■ Indication

Generally, indications for bougienage can be any symptomatic stenosis in the gastrointestinal tract, especially of benign etiology.

With regard to stenotic neoplastic lesions, bougies may be used as a preparatory measure for further interventions, since mere bougienage of malignant narrowings has a very short-lived effect. In practical terms, bougies can only be used in easily accessible segments of the GI tract or if the intended dilation diameter does not exceed the width of the working channel of the used endoscope.

In the following, the technique of esophageal bougienage will be described in a stepwise manner. Bougienage in other locations may be per-

formed with the same technique by analogy. Biliary and pancreatic strictures are also amenable to smaller bougies used through the working channel of a duodenoscope.

Several controlled trials have compared bougies with balloon dilators for the treatment of esophageal strictures. In summary, no significant differences concerning clinical response or complication rates could be demonstrated. Thus, in situations where the use of both bougies and balloon dilators is feasible, the selection of the proper device depends on the individual expertise and experience of the operator. An argument for the use of bougie dilators is the operator's ability to better gauge the forces exerted on a stricture by tactile feedback.

■ Devices

Bougie dilators are flexible catheters with a tapered tip, available as push-type dilator (■ Fig. 2.1b) or wire-guided devices. The most commonly used bougie for the esophagus is the Savary–Gilliard dilator (■ Fig. 2.1a). These tapered, solid tubes of polyvinyl chloride are reusable devices, have a central channel to accommodate a guide-wire, and are available in calibers 1–20 mm (3–60 Fr).

In addition to endoscopic standard equipment, a fluoroscopy unit should be available, even though many esophageal strictures, especially in the case of repeat dilations at the same site, can be dilated without fluoroscopic guidance. Small-caliber (pediatric) endoscopes can be useful in transversing a difficult stricture.

■ Technique

— The etiology, length, and further characteristics of the site needing dilation have to be well evaluated before therapy. If a stricture should prove to be impassable even with a small-caliber endoscope, contrast matter can be

■ Fig. 2.1 Tools for gastrointestinal dilation.
a Savary–Gilliard dilator.
b Maloney dilator. c balloon dilator



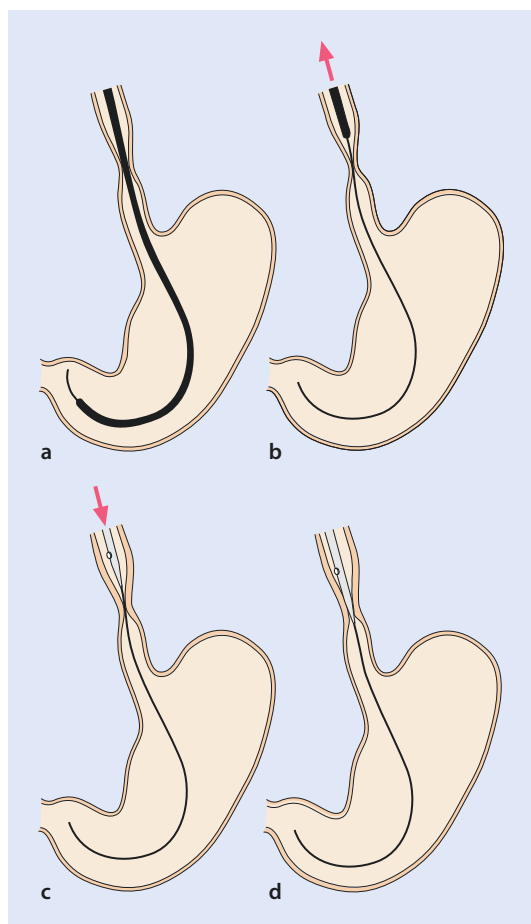


Fig. 2.2 Bougienage of an esophageal stricture.
a Guide-wire placement. **b** Withdrawal of the endoscope.
c Introduction of the bougie over the guide-wire.
d Bougienage, repeat with larger bougies if indicated

applied via an ERCP catheter to depict the stenosis on fluoroscopy.

- For the treatment of an esophageal stricture, the endoscope is passed through the stenosis into the stomach. A guide-wire is placed into the antrum or duodenum under endoscopic control (■ Fig. 2.2a). In the case of an impassable stricture, the guide-wire can be advanced over the stricture into the stomach under fluoroscopic control. In this case, a soft guide-wire with a Terumo tip should be used.
- After withdrawal of the endoscope (■ Fig. 2.2b), the bougie dilator is introduced over the guide-wire using gentle pressure until the maximal caliber is passed over the stenosis (■ Fig. 2.2c, d). The bougie should always be

well lubricated for a smooth passage. If no resistance is felt, no dilation of the stricture site has occurred. On the other hand, no excessive force should be used.

- The bougie is finally withdrawn carefully with simultaneous advancement of the guide-wire to prevent dislocation out of the stomach.

To prevent complications, usually the «rule of three» is applied for the selection of appropriate bougie sizes: the caliber of the first bougie should be equivalent to the estimated diameter of the stricture, followed by a stepwise increase in bougie sizes. After moderate resistance is encountered for the first time, no more than three dilators of progressively increasing caliber should be passed in one session (i.e., widening of the stricture by 3 mm in one session).

An exception to this rule is the treatment of a symptomatic Schatzki ring. The single passage of a large-diameter bougie (16–20 mm) has been advocated for this classic indication, as bougienage aims to disrupt the ring consisting of mucosa and submucosa.

Traces of blood on the withdrawn bougie dilator are a sign of expected mucosal injury (■ Fig. 2.3) and are not equivalent to a complication but should sound a note of caution.

In the case of persisting or recurrent dysphagia, a repeat procedure should be scheduled in 3–7 days.

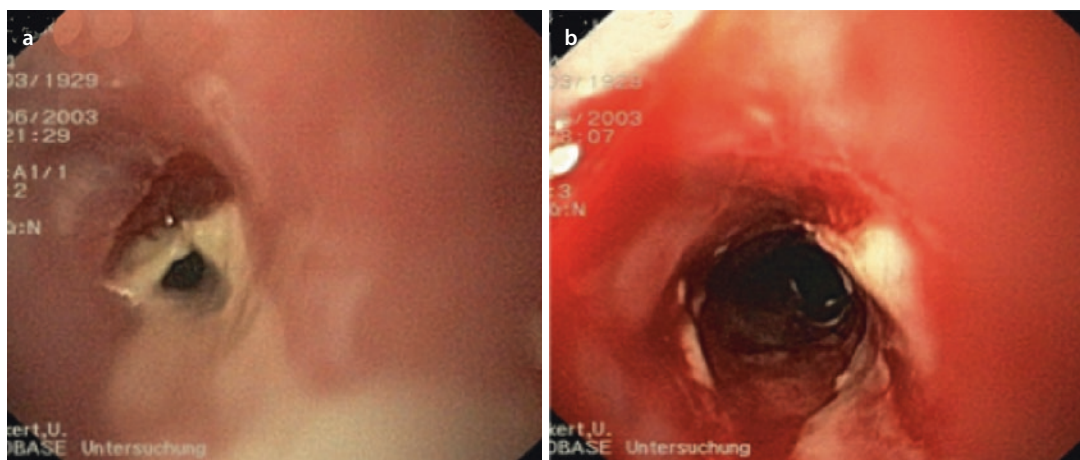
■ Outcomes and Safety

Dysphagia usually can be relieved regardless of the type of stricture, if a widening of the lumen to at least 13–15 mm is achieved.

For peptic stenoses, clinical success rates of 85–93% are reported with bougie dilations to diameters of 13–20 mm. Significant predictors for recurrent dysphagia are an initial small diameter of the stricture, a hiatal hernia >5 cm, persisting heartburn after the procedure, and a high number of dilation sessions necessary to relieve dysphagia.

The use of PPI can lower the risk of recurrence in peptic stenosis. In general, non-peptic strictures appear to have an increased risk of recurrence within the first year post-procedure.

The major complications of bougienage in the esophagus are perforations, significant bleeding, and aspiration. Perforation is the most clinically significant complication and is estimated to occur in 0.1–0.4% of cases. A perforation should be



■ Fig. 2.3 Esophageal stricture **a** before and **b** after bougienage

■ Fig. 2.4 Hegar's dilators, sample sizes of 12, 14, and 16 mm



suspected if intense or persisting pain is reported post-procedure or if dyspnea, tachycardia, subcutaneous emphysema or fever is observed. In those cases, a thoracic CT or an esophagogram with water-soluble contrast should be obtained.

Even though dilatation procedures (together with variceal sclerosing) in the esophagus have been associated with a higher incidence of bacteremia than any other endoscopic procedures, it is rarely clinically significant. The current guidelines of the DGVS (the German gastroenterology association) do not recommend routine antibiotic prophylaxis, as there is no scientific evidence as to its benefit in preventing infectious endocarditis (Egan et al. 2006, Siddiqui et al. 2013).

■ Bougienage of Anal Strictures

Anal or distal rectal strictures (e.g., Crohn's-related or deep pelvic anastomotic) can be widened with the use of metal bougies.

A pre-procedure evaluation with a small-caliber endoscope is advisable to identify more proximal stenoses or inflammatory alterations. For bougienage in this setting, so-called Hegar dilators are commonly used. These are slightly curved stainless steel rods with a conic tip and a round profile (■ Fig. 2.4). They are available in sets of various sizes, ranging from 3 to 18 mm. They are introduced with gentle pressure without the use of a guide-wire; the initial diameter is estimated by means of the digital rectal examination;

the rule of three is applied accordingly. If the initial rectal examination is already painful, sedation during the procedure is recommended.

2.2.2 Dilation

■ Indications

Stricture dilation may be indicated in any accessible segment throughout the gastrointestinal tract if there is associated clinical impairment or if the passage of a larger instrument for further interventions is required.

■ ■ Esophagus

Dysphagia is the indication for dilation of a benign esophageal stricture. Dysphagia secondary to a malignant stricture will usually only temporarily be alleviated by dilation and prompts further interventions (e.g., stent placement). The endoscopic standard therapy for achalasia is pneumatic balloon dilation.

Esophageal strictures can be categorized into two groups. Simple strictures are symmetric or concentric with a diameter >12 mm and allow for an easy passage of the endoscope. Complex strictures are tortuous, smaller than 12 mm in diameter, or cannot be passed with a diagnostic endoscope.

Empiric dilations of the esophagus without obvious structural pathologies have been reported. Taking into consideration the balance between possible major complications and questionable success rates, dilation for this indication cannot be recommended (Egan et al. 2006).

■ ■ Stomach/Small Intestine

The most common indication in this segment is a gastric outlet stenosis due to various etiologies: peptic scarring, inflammatory conditions (Crohn's disease, pancreatitis, etc.), NSAID-induced, corrosive damage, or iatrogenic after endoscopic resections. The majority of these strictures are located in the pylorus or the duodenal bulb. Anastomotic strictures after surgery are another principal indication (Kochhar and Kochhar 2011).

■ ■ Biliary System

Dominant strictures of the biliary tract in primary sclerosing cholangitis (PSC) are an indication for biliary dilation. Benign or postoperative biliary

and anastomotic strictures after orthotopic liver transplantation are amenable to balloon dilation but have to be treated with further stenting for sustained clinical success. The widening of malignant stenoses to allow for the placing of a stent or balloon dilation of the papilla (preferably after sphincterotomy) in preparation for stone extraction is a further indication (Siddiqui et al. 2013).

■ ■ Colon

Colonic stricture associated with obstructive symptoms should generally be evaluated for endoscopic dilation. The various etiologies include inflammatory bowel disease (IBD), ischemia, anastomotic or radiogenic scarring, NSAID, neoplasia, and diverticular disease.

Predictors of clinical success after dilation are short strictures, anastomotic stenosis, and tight strictures <10 mm. Multiple strictures, complete obstruction, stricture length of >4 cm, associated fistulas in the stenotic area, malignancy, or recent surgery are arguments for primary surgery (Lemberg and Vargo 2007).

■ Devices

Dilators are made of inflatable thermoplastic polymers fixed to a catheter and can be inflated to a cylindrical shape (■ Fig. 2.1c) using a handheld accessory device. By pressure injection of liquid (water/diluted radiopaque contrast) or air, the balloon is expanded to a specified diameter. Most balloon dilators are designed to pass through a 2.8-mm endoscopic working channel («through the scope,» TTS) with or without wire guidance. Large-diameter balloons for the treatment of achalasia are filled with air («pneumatic dilation») and cannot be passed through the working channel of an endoscope. They are placed using wire guidance.

TTS balloon dilators are available in various sizes and designs, usually with diameters 6–20 mm and balloon lengths 3–8 cm. Some designs allow for sequential dilation to multiple diameters, depending on the applied pressure. Achalasia balloons are available in standard sizes of 30, 35, and 40 mm.

From a practical point of view, it is a noteworthy detail that lower pressures are used for pneumatic dilation to treat achalasia than for the smaller TTS balloons. For this reason, pressures are commonly indicated in atmospheres (atm) on devices for TTS balloons and in «pounds per

square inch» (PSI) for achalasia balloons. Both coiled and monofilament/coated guide-wires can be used for dilator guidance if the design provides sufficient lateral stability (e.g., Jagwire).

■ Technique: Esophagus

Pneumatic dilation for achalasia: by dilation of the lower esophageal sphincter (LES), a disruption of LES muscle fibers is intended to lower the sphincter's resting pressure. A favorable diagnostic marker for clinical success is a post-procedure resting pressure of the LES of <10 mmHg, which can only be evaluated by manometry in the further clinical course. The dilation can be performed under direct endoscopic visualization or facilitated by use of fluoroscopic guidance, depending on the operator's preference and experience. It is imperative that a complete esophagogastroduodenoscopy with detailed inspection of the cardia has been performed before the dilation, to rule out pseudoachalasia.

The concept of «graded dilation» has proved effective and safe: The LES is first dilated using a 30-mm balloon. If there is an unsatisfactory resolve of dysphagia, a further dilation to 35 mm is performed 4–8 weeks later, with a final dilation to 40 mm after a similar interval if necessary.

With fluoroscopy the dilation is performed as follows:

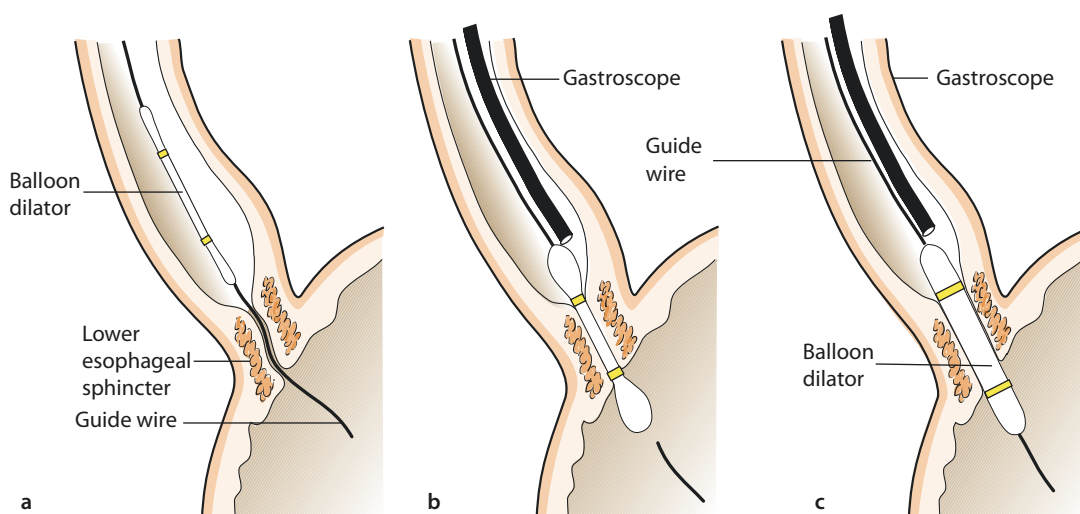
- After placement of the guide-wire under endoscopic visualization and removal of the

endoscope, the achalasia balloon (e.g., Rigidflex) is well lubricated and inserted over the guide-wire. Under fluoroscopic control, the balloon is advanced (■ Fig. 2.5a), until the double radiopaque markers (signifying the center of the balloon) are projected on the crest-like demarcation between the «dark» thorax and «light» abdominal area, i.e., the balloon is placed at the level of the diaphragm.

- First the balloon is inflated incompletely to adjust the position of the forming waist in the middle of the balloon (■ Fig. 2.5b).
- After appropriate centering over the stricture, pressure is applied preferably up to 7–10 PSI. The pressure is maintained until the waist is obliterated (the preferred endpoint) and optionally for a further 6–60 s (■ Fig. 2.5c). Care has to be taken to keep the balloon into place over the stricture, because there is a tendency for aboral dislocation.
- Finally, the balloon is completely deflated and removed together with the guide-wire.

Without fluoroscopy the dilation comprises the following steps:

- Placement of the guide-wire, removal of the endoscope, and introduction of the balloon as described above.
- Then the gastroscope is reintroduced and positioned above the cardia, so that the



■ Fig. 2.5 Dilation of an esophageal stricture. a Introduction of the balloon dilator over the placed guide-wire. b Positioning of the balloon under direct

visualization, alternatively with fluoroscopic control. c Balloon inflation until obliteration of the waist

balloon can be maneuvered across the stricture under direct visualization (■ Fig. 2.5b).

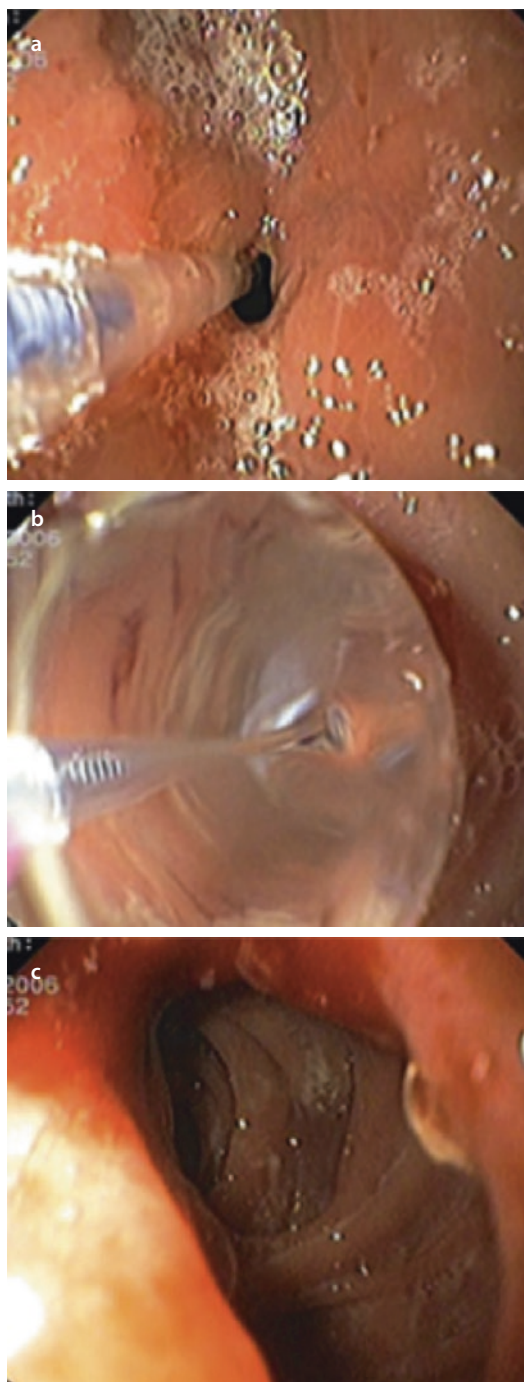
- The balloon is slowly inflated to 7–10 PSI. The dilated cardia can be observed through the balloon (■ Fig. 2.5c).
- The pressure is maintained until an ischemic ring at the tightest diameter of the cardia is noted (equivalent to the obliteration of the waist) or for 6–60 s.
- Finally, the balloon is completely deflated and removed after the endoscope.

❗ **Care has to be taken to completely deflate the balloon before extraction.**

■ ■ Technique: TTS Balloon Dilators

TTS dilators can be used in the esophagus as an alternative to bougienage. Their use is usually preferred for complex strictures. Bougienage is as effective and more cost-efficient for simple strictures (e.g., Schatzki rings).

- First, the length and further characteristics of the stricture are determined (with contrast via an ERCP cannula if required). Then a balloon dilator with appropriate size and length is selected.
- If the stricture cannot be negotiated with the endoscope, a guide-wire is advanced into the antrum using fluoroscopy to avoid kinking of the balloon catheter while passing complex strictures. With simple strictures, the balloon can be cautiously placed under direct endoscopic guidance without a wire, and fluoroscopy is not required.
- The balloon is inflated under vision. The appropriate inflation pressure (depending on the intended diameter according to manufacturer's specifications) is held for 30 s or until a sudden drop in pressure is noted on the pressure gauge of the inflation system. A slow increase of the inflation pressure and positioning of the dilator directly at the tip of the endoscope reduces the likelihood of balloon dislocation.
- Waist formation and its obliteration can be directly observed through the transparent balloon.
- Finally, the balloon is completely deflated and withdrawn with the endoscope (■ Fig. 2.6).



■ Fig. 2.6 Balloon dilation of pyloric stenosis. a Passage of balloon catheter over stricture. b Inflation of balloon. c luminal view after dilation

■ ■ Technique: Gastric/Enteral, Biliary System, and Colon

Dilation in these segments is performed in analogy to the technique described above. (For dila-

tions of biliary strictures, see ► Chap. 4). The larger the selected dilation diameter, the more sustained the clinical response seems to be, at the expense of an increased perforation rate.

Special aspects and recommendations with regard to different segments of the GI tract are listed in the following table.

Dilations in Different Segments of the Gastrointestinal Tract

Stomach/Small Intestine

- First dilation usually to 15 mm.
- Ulcerations and active inflammations should be treated medically before dilation.
- More cautious dilation in repeat sessions of tight strictures (interval approx. 7 days).
- No dilation within 8 weeks after chemical burns.

Biliary System

- Ampulla of Vater: balloon size depending on the width of the distal bile duct. Up to 15 mm possible after sphincterotomy.
- Proximal CBD: not over 6 mm.
- If no waist obliteration is observed after 30 s, repeat dilations may be attempted.

! There is a risk of cystic duct dilation/perforation, especially in cases of low insertion of the cystic duct. The position of the guide-wire in the central bile ducts has to be ascertained before balloon inflation.

Colon

- First dilation for anastomotic strictures and Crohn strictures: 15 mm.
- More cautious approach for strictures induced by diverticulitis, ischemia, or radiation.
- (Neoterminal) ileum: 10–12 mm. Repeat dilation to 15 mm in case of insufficient clinical response.

■ Outcomes and Safety: Esophagus

Balloon dilations of benign esophageal strictures have excellent short-term clinical results.

Nonetheless, recurrence of dysphagia within the first year post-dilation occurs frequently, especially in the case of non-peptic strictures. Clinical response and complication rates are comparable to those achieved with bougienage (see above).

Balloon dilation can be considered the standard therapy for achalasia, as an alternative to operative myotomy. Performed as «graded dilatation» as described above, a European multicenter trial observed a success rate of 82% after 5 years with no significant difference to laparoscopic Heller myotomy (LHM) with Dor fundoplication (Moonen et al. 2016). Irrespective of operative or endoscopic treatment (with a tendency toward more favorable outcomes for LHM), relapses may become apparent in the further clinical course and warrant repeat interventions. Rates of significant gastroesophageal reflux of about 20% are to be expected after dilation as well as LHM with fundoplication.

A better outcome for dilation is to be expected for patients >45 years of age. Young men in particular have a tendency toward lower success rates after balloon dilation. Further unfavorable predictors for clinical success after dilation are a dilated esophagus and Type I or III achalasia according to the Chicago classification (Pandolfino and Kahrilas 2013).

■ Outcomes and Safety: Stomach/Small Intestine

Dilations of the pylorus for treatment of a gastric outlet stenosis have favorable short-term success rates of 70–80%. Divergent results are reported for sustained clinical response, with success rates between 30% and 100%. A consistent therapy with PPI as well as eradication therapy of *helicobacter pylori* seem to be predictors for a successful outcome.

It is noteworthy that for this indication, strikingly high perforation rates of up to 7% were reported. For this reason we recommend cautious dilation, not over 15 mm. Dilations of gastroenteric anastomotic stricture seem to have good response rates. Case series for fibrotic Crohn's disease strictures report long-term success rates, with avoidance of surgery in 56–75% of patients.

■ Outcomes and Safety: Biliary System

Exclusive dilation of biliary strictures has no sustained clinical response and should be accompanied

by additional therapy like stent implantation. Only with PSC-induced dominant strictures is the placement of a stent of no additional use.

The dilation of the sphincter of Oddi as an alternative to endoscopic papillotomy is associated with an increased rate of pancreatitis. A large-caliber dilation after sphincterotomy has a success rate of 98% with regard to removal of large biliary stones, with a low complication rate (post-ERCP pancreatitis 1.2%).

■ ■ Outcomes and Safety: Colon

Various uncontrolled case series have observed good effectivity of the dilation of benign colorectal strictures, with reported complication rates of 0–10%.

Excellent short-term results are reported for strictures in Crohn's disease, but data for long-term avoidance of surgery are similarly divergent as described above for gastric/enteral strictures (Endo et al. 2013).

■ ■ Outcomes and Safety: Additional Techniques

Incisions Electrosurgical incisions of esophageal or colonic strictures using a sphincterotome or needle-knife have been described by different work groups. Performed in addition to balloon dilation, increased clinical success rates are claimed. Evidence for the superiority of this procedure is rare, with the exception of the incisional treatment of Schatzki rings. For this indication, incisional therapy seems to produce comparable results to bougienage.

Steroid injections There is an ongoing controversy over the role of adding intralésional steroid injection to dilational therapy. Data from controlled trials predominantly suggest a lowered relapse rate after additional steroid injection, especially with regard to strictures in Crohn's disease. On the contrary, steroid injections were not found to be effective with possible negative side effects in anastomotic strictures.

In our opinion, the injection of steroids in combination with dilation is a noteworthy treatment option for refractory benign strictures of peptic or inflammatory origin. A practicable approach to this technique is to dilute 40 mg/ml triamcinolone 1:1 with saline. Then, 0.5 ml aliquots are injected into each quadrant at the edge of the lesion (Di Nardo et al. 2010).

2.3 Stenting

In medical practice, stents are devices used to maintain or restore luminal patency of hollow organs, vessels, or ducts. In gastroenterology, semirigid plastic stents are distinguished from self-expandable stents. Tubelike plastic stents are generally only used in the biliary/pancreatic system and are placed over a guiding catheter or are pushed directly over the guide-wire in case of small-caliber stents. Plastic stents are available in different designs (e.g., straight or pigtail) and in sizes up to 12 French.

Self-expandable stents consist of mesh cylinders that are packaged in a compressed form on a delivery catheter. Once deployed, they exert self-expanding forces until reaching a predefined diameter (■ Fig. 2.7). Sustained high radial forces then effect an appropriate widening of strictures and anchoring to surrounding tissue. Self-expandable stents are most commonly composed of metal alloys (SEMS, self-expandable metal stents) such as nitinol.

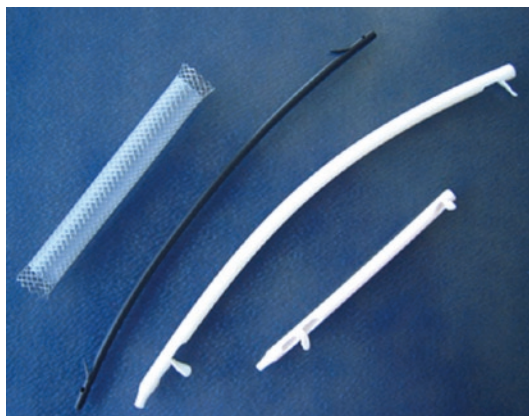
A self-expandable plastic stent (SEPS) has been developed for the esophagus, allowing for easy retrieval but also showing high migration rates. Self-expandable stents made of absorbable polyester-polymer (biodegradable stents) are available in Europe. Stents coated with a chemotherapeutic agent (drug-eluting stents) have been tested only in preliminary studies.

To prevent ingrowth of neoplastic tissue through the mesh, SEMS may be wholly or partially covered with a plastic membrane or silicone (fully or partially covered SEMS). Esophageal stents are commonly flared at both ends to prevent migration and are available in various diameters (12–28 mm, >30 mm for leakage SEMS) as well as lengths (■ Fig. 2.8). Enteral and colonic stents are usually uncovered to achieve firm anchoring to the intestinal wall, to reduce the likelihood of migration despite peristaltic forces.

Esophageal SEMS are deployed over a guide-wire outside the endoscope; other stents have to be introduced via the endoscopic working channel. SEMS are marketed in various designs and sizes with different characteristics with regard to radial forces and the degree of foreshortening after deployment (Varadarajulu et al. 2011).

■ Indications: Esophagus

Esophageal SEMS are indicated for the palliation of malignant strictures or tracheoesophageal fistulas. Furthermore, SEMS are an important therapeutic



■ Fig. 2.7 SEMS and plastic stents

option for the treatment of esophageal perforations. SEPS and covered SEMS may be used for benign strictures.

■ ■ Indications: Stomach/Small Intestine

Gastroduodenal SEMS are commonly used for palliation of malignant gastric outlet strictures. Further applications are possible, especially for advanced endoscopic transgastric procedures (e.g., EUS-guided biliary drainage, transmural necrosectomy, etc; see ► Chap. 5).

■ ■ Indications: Biliary/Pancreatic System

An important indication for endoscopically placed stents is palliative drainage of malignant biliary obstructions. Because of lower occlusion rates, insertion of SEMS is preferred if the expected survival is >4 months.

The majority of benign strictures for which stenting is indicated are caused by postsurgical injuries or inflammatory disorders. Dominant strictures in PSC are usually treated by dilation only. Further potential applications are the therapy of biliary leakage, temporary stenting for bile duct stone that cannot be cleared initially, symptomatic pancreatic strictures, a symptomatic pancreas divisum, or the prophylaxis of post-ERCP pancreatitis (Pfau et al. 2013).

■ ■ Indications: Colon

Colonic SEMS are mainly used as palliative therapy for malignant obstructions, mostly as a bridge to surgery. The closure of malignant fistulas may be attempted with covered SEMS in non-operable palliative situations.

■ Technique

Before stenting, the extent of the respective stricture has to be evaluated endoscopically or using fluoroscopy. The length of the stenosis can be evaluated using the distance markers on the shaft of the endoscope. Alternatively, the edges of the stricture can be marked with the injection of Lipiodol. The selected stent should be 3–4 cm longer than the obstruction, to cover a sufficient distance on both sides of the lesion. Examining the patient in supine or prone position has the advantage of better fluoroscopic overview of the anatomy.

! **Long-standing colonic obstruction with (sub-) acute ileus is frequently present in the case of malignant colonic strictures presented for stenting. Therefore, insertion of a nasogastric tube is strongly encouraged before endoscopy to minimize the risk of aspiration during sedation.**

- The endoscope is advanced to the stricture. If the stenotic lesion can be easily transversed, a stiff wire of 0.89 mm (0.035 inch) is advanced about 20 cm over the stricture. If no passage is possible, the stricture is cautiously probed with a flexible, hydrophilic wire through a biliary catheter; contrast application through the catheter is used for fluoroscopic guidance. Once wire and catheter are passed over the stricture, the wire is exchanged for a stiff wire. Occasionally, dilation has to be performed to allow passage of the esophageal SEMS. In contrast, dilation should be avoided during colonic SEMS deployment.
- Over the wire: The endoscope is withdrawn, and the delivery catheter is advanced through the stricture over the wire. The endoscope is then reintroduced alongside the predeployed stent for direct visual control.
- TTS: A working channel of ≥ 3.2 mm (10F) is required, e.g., a therapeutic gastroscope or standard colonoscope. The delivery system can be advanced through the scope in this case.
- The middle of the stent is positioned over the stenotic lesion, and the constraint system is released, with subsequent radial expansion of the stent (from distal to proximal with most delivery systems) (■ Figs. 2.9 and 2.10).




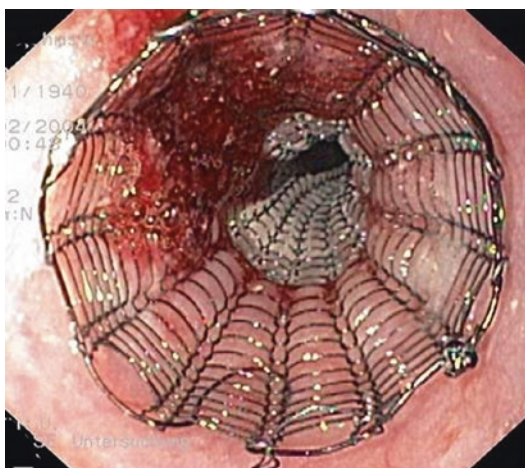
Fig. 2.8 Different variants of self-expanding esophageal stents

! An important aspect of SEMS deployment is the variable degree of foreshortening that occurs with most stents upon release from the delivery catheter. A permanent adjustment of position under fluoroscopic or visual control is therefore essential.

— After the entire stent is released, its position should be evaluated using fluoroscopy. If no definite waist formation can be detected, or if one end of the stent appears to be compressed, the stricture is possibly not bridged. Repositioning or placement of a further stent (stent-in-stent) then has to be considered.



■ Fig. 2.9 Distal release SEMS



■ Fig. 2.10 Partially covered SEMS in the esophagus

- When malignant gastric outlet strictures are evaluated for stenting, a simultaneous biliary obstruction is frequently either evident or impending. In these cases, a biliary SEMS should be placed before deployment of the duodenal stent to allow for biliary drainage. If biliary obstruction becomes evident after duodenal stent placement, dissection of the SEMS mesh can be attempted in the papillary area using APC. If the biliary system cannot be accessed through this route, a percutaneous transhepatic drainage is required.

■ Outcomes and Safety: Esophagus

SEMS can provide at least short-term relief of dysphagia due to malignant obstructions in over 90%

of cases and therefore are an established procedure for the restoration of enteral nutrition in palliative care or as a bridge to surgery. Stent migration is a concern in the further clinical course, especially after neo-adjuvant therapy. Migration rates of 24–46% have been reported in these cases.

SEPS dislodge more frequently and are not recommended for use in malignant obstructions.

Of concern are strictures near the upper esophageal sphincter; here, SEMS with a smaller diameter are used to prevent complications as foreign body sensations, pain, tracheal compression, and pressure necrosis. Stents with a proximal release mechanism are beneficial in these situations to allow for a more precise positioning.

Placement of self-expandable stents for therapy of benign strictures has been reported in case series. Silicone-covered SEPS are easier to remove, especially after long placement periods; on the other hand, higher migration rates than for SEMS have been described.

For esophageal ruptures and leakages, covered SEMS are successfully employed with lower complication rates than for operative alternatives. For this indication, attention should be paid to extract the implanted stents after 2–4 weeks to prevent tissue ingrowth and a technically difficult removal.

■ Outcomes and Safety: Stomach/Duodenum

The technical success of stent implantation for the treatment of gastric outlet obstruction is reported to approach 100%. And for >80% of patients, subsequent oral intake of at least a soft diet is possible.

Stenting of malignant gastric outlet obstructions seems to be superior to bypass surgery with regard to short-term reestablishment of oral nutrition and improvement of quality of life.

Surgery is associated with lower rates of long-term recurrent obstructions because of possible stent occlusion by tumor ingrowth.

Severe complications of gastroduodenal stent placement occur in about 1% of patients. With a mean survival of 12 weeks after stenting for malignant obstruction, stent migration ($\approx 5\%$) and restenosis ($\approx 18\%$) are late complications.

■ Outcomes and Safety: Biliary System

Plastic stents as well as SEMS are successfully used for palliation of malignant bile duct obstruction, decreasing cholestasis and improving quality of life.

Occlusion of inserted plastic stents with a diameter of 10F occurs in 3–6 months. Longer patency could not be demonstrated for plastic stents with a larger diameter, with a possible increased risk of post-procedure pancreatitis.

SEMS have longer patency, but after some time uncovered stents are virtually impossible to remove because of tissue ingrowth.

Bridging drainage for the treatment of biliary or pancreatic leakages and irretrievable bile duct stones is possible in more than 90% of cases.

Clinical success in benign stenosis is strongly dependent on the etiology of the obstruction; insertion of multiple plastic stents side by side generally yields superior results compared to single plastic stents. In this context, general success rates for benign strictures are 94% and 54% for multiple and single stenting, respectively, with strictures due to chronic pancreatitis only 60% and 44%.

A predominantly distal migration occurs in 5–10% of cases after placement of plastic stents, whereas uncovered SEMS rarely migrate. Cholecystitis has been reported in up to 10% of cases after placement of a covered stent across the cystic duct ostium.

Temporary placement of a covered SEMS for benign strictures is a feasible alternative in selected patients. The problem of possible induction of hyperplastic tissue growth at the proximal end of the stent with subsequent difficult removal or new stricture formation has to be considered in these cases.

In chronic pancreatitis with pancreatic duct stricture, good short-term improvement of pain can be achieved by pancreatic duct stenting. Endoscopic long-term treatment often requires frequent stent changes over multiple months.

A reduction in post-ERCP pancreatitis rates has been reported for prophylactic pancreatic duct stenting for small plastic stents (3–5 French, 3–5 cm length) in the case of high-risk patients (e.g., difficult cannulations, accidental pancreatic duct cannulation; see ► Chap. 4) (Pfau et al.).

■ ■ Outcomes and Safety: Colon

Insertion of stents as a bridge to surgery in acute malignant obstructions is the principal indication for the use of SEMS in the colon, allowing for subsequent one-stage surgery in an elective setting with lower complication rates. Although a difference in overall survival in comparison to primary surgery has not been demonstrated to date, improved quality of life and cost-effectiveness have been reported (Varadarajulu et al. 2011).

Technical and short-term clinical success rates are above 90%. Main complications are perforations (about 4%) and migration (about 10%). Though SEMS may be placed successfully in all colonic segments, the advantages of primary endoscopic therapy have been demonstrated for left-sided stenting. Furthermore, the topic is controversial since recent controlled studies have produced conflicting evidence with unusually high perforation rates and inferior outcome of colonic stenting compared to emergent surgery.

In conclusion, placement of colonic SEMS may be used as a treatment option in patients with acute obstruction of left-sided cancer to avoid emergent surgery and in certain palliative situations. It should be performed by experienced endoscopists; balloon dilation before placement is not encouraged. Special caution should be applied if chemotherapy is planned, as an increased rate of delayed perforations has been reported in these cases (Garcia-Cano 2013, van Hooft et al. 2011).

2.4 Thermal Procedures for Recanalization/Ablation


2.4.1 Argon Plasma Coagulation

Argon plasma coagulation (APC) is a technology of electrocoagulation, i.e., ionized argon gas («argon plasma») is «sprayed» onto the target tissue from a monopolar probe, and this plasma is used as a medium to create an electric current, effecting thermal coagulation at the tissue surface. The extent and depth of the coagulation effects are influenced by application time, power setting (watt), settings of plasma flow (■ Figs. 2.11 and 2.12), specific surface characteristics of the target tissue, and distance from the probe to the target tissue.

The dried coagulated tissue layer has an insulating effect, first routing part of the electrical current through the surrounding tissue. Continuing application of current then produces deep coagulation defects as well.

If the probe is too distant from the target tissue, no effective current density can be established. If the probe touches the mucosa, a diathermal effect is produced comparable to a monopolar coagulation probe, and argon gas is insufflated into the submucosa through the ensuing defect.

■ Fig. 2.11 Pulsed APC



■ Fig. 2.12 Forced APC



■ Devices

Application of APC involves an appropriate applying catheter and an electrosurgical generator. Upon activation by a foot pedal, a synchronized flow of gas and current out of the tip of the catheter probe is generated. A neutral electrode patch is applied to the patient.

APC probes are marketed with various designs of openings at the tip, allowing for straight, circumferential, and sideways applications.

■ Indication

As a recanalization technique, APC can be used for tumor debulking throughout the gastrointestinal tract. Furthermore, it is used for restoring luminal patency of overgrown and obstructed stents. Cutting the mesh of SEMS may be possible using APC, presenting a helpful method for treating dislocated and obstructing stents.

■ Technique

- The endoscope is advanced to the target lesion. Residual soiling and surface fluid have to be cleared because they interfere with gas flow.
- The APC probe is inserted through the working channel, the tip placed approximately 2–8 mm from the surface of the target lesion. Because of possible thermal damage to the endoscope's video chip, it is recommended that the probe is extended at least 10 mm outside the endoscope (usually until the first black ring is visible in the endoscopic field).
- Power, gas flow, and mode settings depend on the location, structure, and size of the target lesion and should generally follow manufacturer's recommendations (■ Table 2.1).
- If the probe is at the correct distance from the surface, an electric arc is formed between the probe and tissue upon depressing the activation pedal. Coagulation is indicated by blackening of tissue and smoke formation. One should keep the endoscope and probe tip in motion to achieve a continuous treatment of the target area.

❗ **Duration of application is the most important factor to influence coagulation depth, even before power settings and distance from the probe to target tissue** (■ Fig. 2.13).

❗ **Care should be taken not to apply coagulation current to one spot for too long (0.5–2 s) to avoid transmural damage, especially in the peripheral area of ablated lesions.**

- One has to keep in mind that argon gas is insufflated during activation, so steady suctioning should be applied to minimize distension and clear smoke from the field of vision.

■ Outcomes and Safety

The evidence for APC as a method to restore luminal patency largely consists of case series. For inoperable esophageal cancer, clinical success rates of 84% have been reported after up to two sessions of APC treatment, with perforation rates of 8%.

Nowadays APC devices are standard equipment in endoscopy units; therefore, it serves as a useful adjunct to the other techniques mentioned above (Ginsberg et al. 2002).

■ **Table 2.1** Recommended APC settings in the gastrointestinal tract (for ERBE-APC2-system with the VIO-generator system)

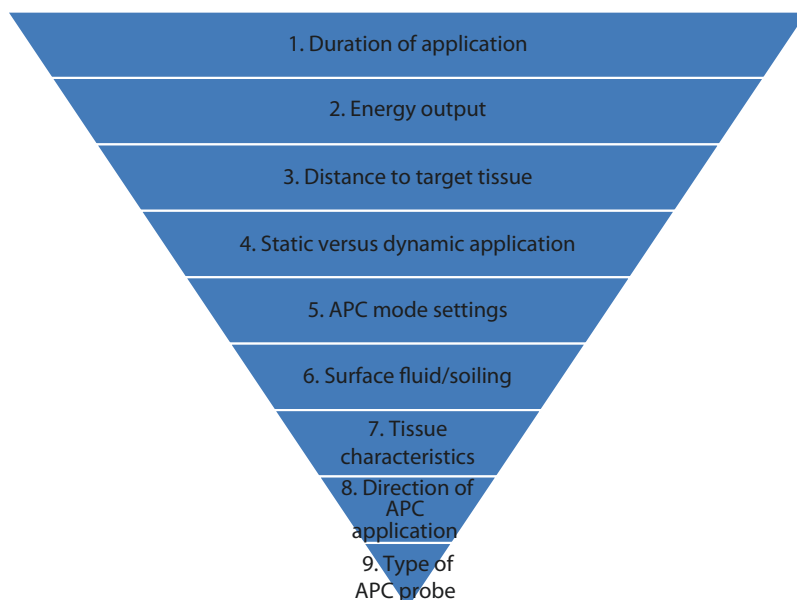
Procedure	Power settings	Mode
<i>Devitalization</i>		
Barrett's esophagus	30–50 W	Pulsed E2
Small polyps	10–30 W	Pulsed E1
Ablation of residual adenoma tissue after EMR	20–30 W	Pulsed E1
Zenker's diverticulum	40–50 W	Pulsed E1
Radiation proctitis	10–30 W	Pulsed E2
<i>Hemostasis</i>		
Vascular ectasia stomach/colon	10–30 W	Pulsed E2
Vascular ectasia duodenum/right colon	E4–E5	Precise
Bleeding ulcer, Forrest Ib–IIb	30–60 W	Forced
<i>Tumor ablation</i>		
Large (≥15 mm)	≥60 W	Forced
Small (<15 mm)	20–50 W	Forced
<i>Stent management</i>		
Stent ingrowth/overgrowth	20–30 W	Pulsed E2
Stent trimming	30–60 W	Forced

2.4.2 Nd:Yag Laser

Laser beams are highly coherent rays of light of a certain wavelength that are produced with the help of an active laser medium. Lasers of a high-power density can be applied for the ablation of lesions, as the absorption of laser light induces a photothermal reaction with ensuing destruction and vaporization of the targeted tissue. For this application in medicine, various lasing media can be employed, e.g., the neodymium-doped yttrium aluminum garnet crystal (Nd:YAG). Nd:YAG laser beams are invisible and produce coagulation up to 6 mm into the tissue with superficial vaporization.

■ **Fig. 2.13** Parameters of APC application, ranked according to impact on coagulation depth.

1. Duration of application.
2. Energy output.
3. Distance to target tissue.
4. Static versus dynamic application.
5. APC mode settings.
6. Surface fluid/soiling.
7. Tissue characteristics.
8. Direction of APC application.
9. Type of APC probe



In clinical practice, additional complex equipment and a certain organizational effort are required; special qualifications to use medical lasers have to be obtained, and in German endoscopy units, a «Laser Protection Commissioner» has to be appointed.

Alternative methods as APC or RFA (radio-frequency ablation) are notably more cost-efficient, easier to apply, and have a more favorable risk profile. For these reasons, gastrointestinal endoscopic laser therapy for thermal ablation is rarely used nowadays.

2.4.3 Photodynamic Therapy

Photodynamic therapy (PDT) is the use of a photochemical reaction to destroy target cells. A light-sensitive drug (photosensitizer) is exposed to light of a certain wavelength, producing singlet oxygen which causes oxidative injury and destruction of cells.

Various substances are utilized as photosensitizers (e.g., aminolevulinic acid and hematoporphyrin derivatives) that are usually administered systematically (i.v. or per os).

Medically applied photosensitizers differ in their respective half-life and duration of effectiveness and are preferentially retained by cells with a high metabolic rate (e.g., cancerous or precancerous cells).

For internal sites, a low-energy laser light of precise wavelengths is used, thereby avoiding direct thermal injury. Only cells that retain a sufficient amount of photosensitizer are destroyed, allowing for selective destruction of neoplasia.

Possible applications in gastroenterology are the palliative treatment of esophageal cancer and cholangiocarcinoma (CCC) as well as the ablation of Barrett's esophagus. For non-resectable CCC, a combination of PDT and stenting has been shown to be superior to stenting alone, with markedly improved survival. The evidence for the clinical benefit of PDT for other indications as compared to less complex treatment options is inconclusive. Furthermore, the optimal photosensitizers for the different indications have yet to be determined. Serious complications of PDT seem to be rare (Fayter et al. 2010).

2.4.4 Cryoablation

For cryotherapy, liquid nitrogen or compressed carbon dioxide (CO₂) is delivered through a catheter for tissue destruction. Liquid nitrogen has a temperature of −196 °C. Compressed CO₂ expands rapidly after exiting the catheter tip, freezing upon the sudden decrease in pressure (Joule–Thomson effect). Applied correctly, the induced freezing damage causes mucosal necrosis almost exclusively.

The device consists of a cryogenic system that delivers the gas or liquid via a flexible catheter through the accessory channel of the endoscope. The tip of the catheter is positioned 5–10 mm from the target tissue. The cryogenic substance is applied by depressing a foot pedal until whitening of the target tissue is witnessed (taking about 10 s). After the mucosal surface has thawed (returned to its original color), freezing is performed repeatedly, usually at 2–3 cycles. A nasogastric decompression tube is used to prevent damage from expanding gas.

This technology is available commercially for gastroenterologists only since 2007 but is already an established procedure in various centers for Barrett's ablation because of relatively simple application. Case series report an excellent safety profile and promising success rates for the treatment of Barrett's dysplasias (Chen and Pasricha 2010).

2.4.5 Radiofrequency Ablation

The term «radiofrequency» denotes a spectrum of electromagnetic wave frequencies above the spectrum of audible frequencies. Heat generated from high-frequency electrical currents is employed for the ablation of tissue. In gastroenterological endoscopy, the most common application of radiofrequency ablation (RFA) is the treatment of Barrett's esophagus.

An array of electrodes, each separated micrometers from each other, on a balloon (for circumferential ablations) or on a rectangular platform (for focal ablations) is used with two immediately adjacent electrodes functioning as a bipolar device. The electric current between these electrodes delivers heat to the surrounding tissue and produces an electrocoagulatory effect to a depth of 1 mm, limiting damage to the mucosa. In the areas of RFA-ablated Barrett's mucosa, a regeneration of squamous epithelium is induced.

The first commercially available RFA balloon devices required the use of a sizing balloon to gauge the appropriate size of the employed ablation balloon; now, self-adjusting balloon catheters are available as well.

After identifying and rinsing the target lesion (and measuring the esophageal diameter depending on the available system), the ablation balloon

is passed into the esophagus over a guide-wire and positioned under endoscopic control, extending approximately 1 cm above the target mucosa; the length of the ablation electrode is usually 3–4 cm.

After balloon inflation and upon foot-switch activation, a circumferential ablation is induced by controlled radiofrequency application (usually for 1 s). This procedure is repeated with or without rinsing of the treated tissue surface; then, the balloon is advanced under direct vision for further ablation steps until the complete extent of Barrett's mucosa is ablated down to the gastroesophageal junction in an overlapping fashion.

In the case of focal lesions or areas of incomplete contact with the ablation balloon, a focal ablation array is used. This system contains a convex platform covered by electrodes on a catheter and is mounted on the tip of an endoscope; a smaller platform for TTS application is available as well. The mounted platform is oriented to the 12 o'clock position of the endoscopic image; ablation is performed analogous to the steps described above.

After Barrett's esophagus ablation, a maximal suppression of gastric acid is critical for the regeneration of squamous epithelium. High-dose PPI, H₂-blockers, and possibly sucralfate should be prescribed for at least 2 weeks post-procedure.

After endoscopic resection of noticeable neoplastic areas, RFA has been reported to achieve a sustainable eradication of dysplastic Barrett's mucosa and prevent metachronous neoplastic lesions. Severe complications are rare, though mucosal lacerations are possible, especially in scarred areas after endoscopic resection (Haidry et al. 2013, Pouw et al. 2010).

RFA for the therapy of neoplastic biliary obstructions applying peculiar catheters has been demonstrated to be feasible with an acceptable safety profile. The evidence for this method is limited to case reports and small series, so little is known about its efficacy.

2.5 Zenker's Diverticulotomy

■ Indication

Zenker's diverticulum is an outpouching of the mucosal and submucosal layer through the wall of the posterior pharynx in the area of the upper esophageal sphincter, most often directed to the left side. It is formed in between the oblique fibers

of the superior part and the circular fibers of the inferior part of the Pars cricopharyngea (the cricopharyngeal muscle) of the M. constrictor pharyngis inferior (a triangular area called Killian's dehiscence).

Zenker's diverticulum is observed almost exclusively in older individuals, with an estimated incidence of 2/100.000 at the age of 65–75. The widely accepted primary cause of Zenker's diverticulum is a neuromuscular dysfunction of the upper esophageal sphincter, but no consensus exists on the exact pathomechanism. This neuromuscular dysfunction leads to a hypertensive cricopharyngeal muscle which over time causes a pulsion diverticulum in the anatomic weak spot of Killian's triangle (■ Figs. 2.13 and 2.14).

Main symptoms include dysphagia, regurgitation, chronic cough, and aspiration.

Flexible endoscopic Zenker's diverticulotomy was first described in 1995. This technique creates a common cavity and performs a myotomy at the same time, by dividing the septum between the diverticulum and esophageal lumen which contains the cricopharyngeal muscle.

■ Devices

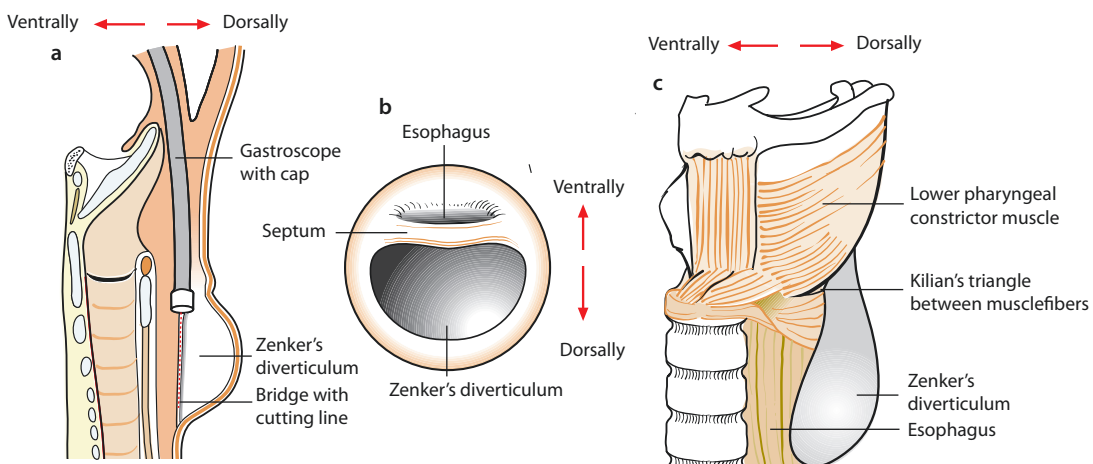
Diverticulotomy is performed using a standard gastroscope fitted with a transparent cap at the tip for better visualization. APC or a needle-knife is commonly used for myotomy; methods using bipolar cutting devices or the «harmonic knife» (developed for laparoscopic surgery) have been described. A soft overtube (the «diverticulo-

scope») may be used for better protection of surrounding tissue and optimizing the operative field, but its use in multimorbid patients is limited by the necessity for wide opening of the mouth and neck extension for insertion.

■ Technique

Patients are placed in a left lateral decubitus position, usually in intravenous analgesedation. General anesthesia with intubation is preferable for optimal conditions, especially in cases with difficult anatomic characteristics.

- First, a diagnostic gastroscopy is performed with detailed evaluation of the diverticulum. A nasogastric tube is inserted under endoscopic control to mark the esophageal lumen.
- Then, a transparent cap is attached to the tip of the endoscope. Some authors recommend inserting the needle-knife at this point and bending the protruding tip toward the center of the cap opening.
- The endoscope is advanced to the septum between the esophagus and diverticulum (■ Fig. 2.15a), and the center point on the cricopharyngeal bar is marked with the needle-knife.
- Then, a stepwise, caudally directed diverticulotomy is cautiously performed (■ Fig. 2.15). The needle-knife is maneuvered by rotating the shaft of the endoscope and by gentle tip deflection. Alternatively, APC is used for dissection of the cricopharyngeal bar. Pure coagulation current or



■ Fig. 2.14 Zenker's diverticulum. a Endoscopic diverticulotomy, lateral view. b Endoscopic view. c Lateral view of anatomy

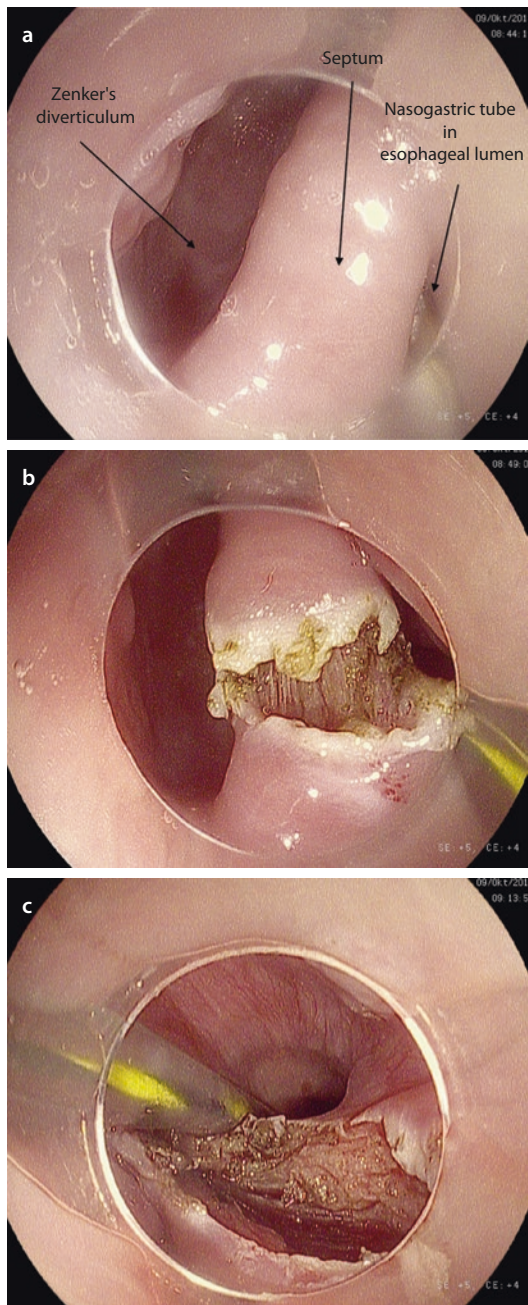


Fig. 2.15 a–c Medium-sized Zenker's diverticulum, endoscopic needle-knife diverticulotomy

blended currents can be used for the needle-knife (e.g., Endocut mode with ERBE generators); for APC power, settings around 50 watts are required.

- The last few millimeters of the cricopharyngeal bar should not be dissected, in order to minimize the risk of perforation.

- After finishing the dissection, an uncomplicated advancement of the standard gastro-scope into the stomach should be possible.

After an uneventful recovery, the patient can be discharged on the following day with a soft oral diet for a few days.

A sore throat is to be expected after diverticulotomy, but strong pain or a subcutaneous emphysema should prompt further radiological diagnostics. If a perforation is diagnosed, conservative management with i.v. antibiotics is usually sufficient; the inserted nasogastric tube can then be used for enteral feeding.

■ Outcomes and Safety

Case series of flexible endoscopic Zenker's diverticulotomy have reported initial success rates of about 96% with persistent or recurrent symptoms in 8.5% of cases. Bleeding occurs in about 3% and perforations in 4% of described cases.

With similar success rates and less severe morbidity compared to rigid endoscopy or surgical approaches, flexible endoscopic diverticulotomy may become the preferred method especially for poor surgical candidates. However, there are no randomized controlled trials comparing the various treatment options (Dzeletovic et al. 2012).

2.6 Peroral Endoscopic Myotomy

Peroral endoscopic myotomy (POEM) is a comparatively recent technique for the treatment of achalasia, applying the concept of natural orifice transluminal endoscopic surgery (NOTES). With this procedure, esophageal myotomy is performed via an endoluminal access, in contrast to the thoracoscopic or laparoscopic routes used for the established Heller's operation. POEM on a human patient was first performed by Inoue in Yokohama, Japan, in 2008.

■ Indication

Achalasia is the original indication for POEM. In theory, achalasia type III (according to the Chicago Classification) in particular might be a good indication for extended endoscopic myotomy. Because of spastic esophageal motility encountered in this subtype, therapy targeted only at the lower esophageal sphincter (LES) (e.g., balloon dilation) has a poor clinical success rate.

POEM has the advantage of tailoring the extent of myotomy in this setting. For the same reasons, POEM has been proposed as a treatment option for hypertensive esophageal motility disorders such as distal esophagus spasm (DES) or jackhammer esophagus.

■ Devices

In principle, POEM is an advanced and challenging endoscopic procedure and should only be performed by operators experienced in ESD techniques at high-volume centers.

POEM should be performed under controlled circumstances with the patient under general anesthesia, with surgical backup because of the potential for severe perforations.

A gastroscope with a transparent cap attached to the tip is employed for the procedure and carbon dioxide gas instead of air for insufflation. For the dissection of the submucosal layer and for myotomy, various instruments may be used depending on the operator's preference (e.g., Triangle Tip knife by Olympus or HybridKnife by Erbe). The HybridKnife has the advantage of enabling submucosal injection and dissection without having to change instruments during the procedure. A mixture of saline and indigo carmine or colloid solutions may be used for submucosal injection and hemostatic clips for mucosal closure. A decompression cannula should be available in the event of (usually harmless) pneumoperitoneum occurrence.

■ Technique

- A submucosal injection on the right side of the esophagus is performed to lift the mucosa 10–15 cm proximal to the lower esophageal sphincter (LES). At this location an incision of 2 cm width is made, for example using the HybridKnife.
- Through this incision, the endoscope is inserted into the submucosal space. A

submucosal tunnel along the right esophageal wall is created by sequential submucosal injection and dissection in an aboral direction. This tunnel is extended about 3 cm distal to the lower esophageal sphincter (LES) along the lesser curvature. The direction and progress of the tunnel is monitored regularly by withdrawal of the endoscope out of the tunnel and inspection from the esophageal lumen.

- The next step comprises the actual myotomy, which is started a few centimeters below the initial incision. The aim is to dissect the inner circular muscle layer without injuring the outer longitudinal esophageal muscle. Modifications, including the dissection of both muscles, have been described. Myotomy is continued distally until it is extended 2 cm into the cardia.
- Finally, the mucosal incision (the «tunnel entry») is closed with endoscopic clips (■ Fig. 2.16).

■ Outcomes and Safety

Various pilot studies have demonstrated the safety and effectiveness of POEM for the treatment of achalasia. A prospective multicenter trial reports a technical success rate of 100% without the need for surgery. Clinical success was observed in 97% of patients after 3 months and 84% after 1 year. The rate of post-interventional gastroesophageal reflux was 37%, slightly higher than in balloon dilation or LHM.

Future randomized controlled studies will have to further examine the efficacy of POEM in comparison to balloon dilation and Heller's myotomy with Dor fundoplication.

Considering the excellent safety profile and encouraging results of existing studies, POEM may become an established alternative to LHM in experienced centers (von Renteln et al. 2013).

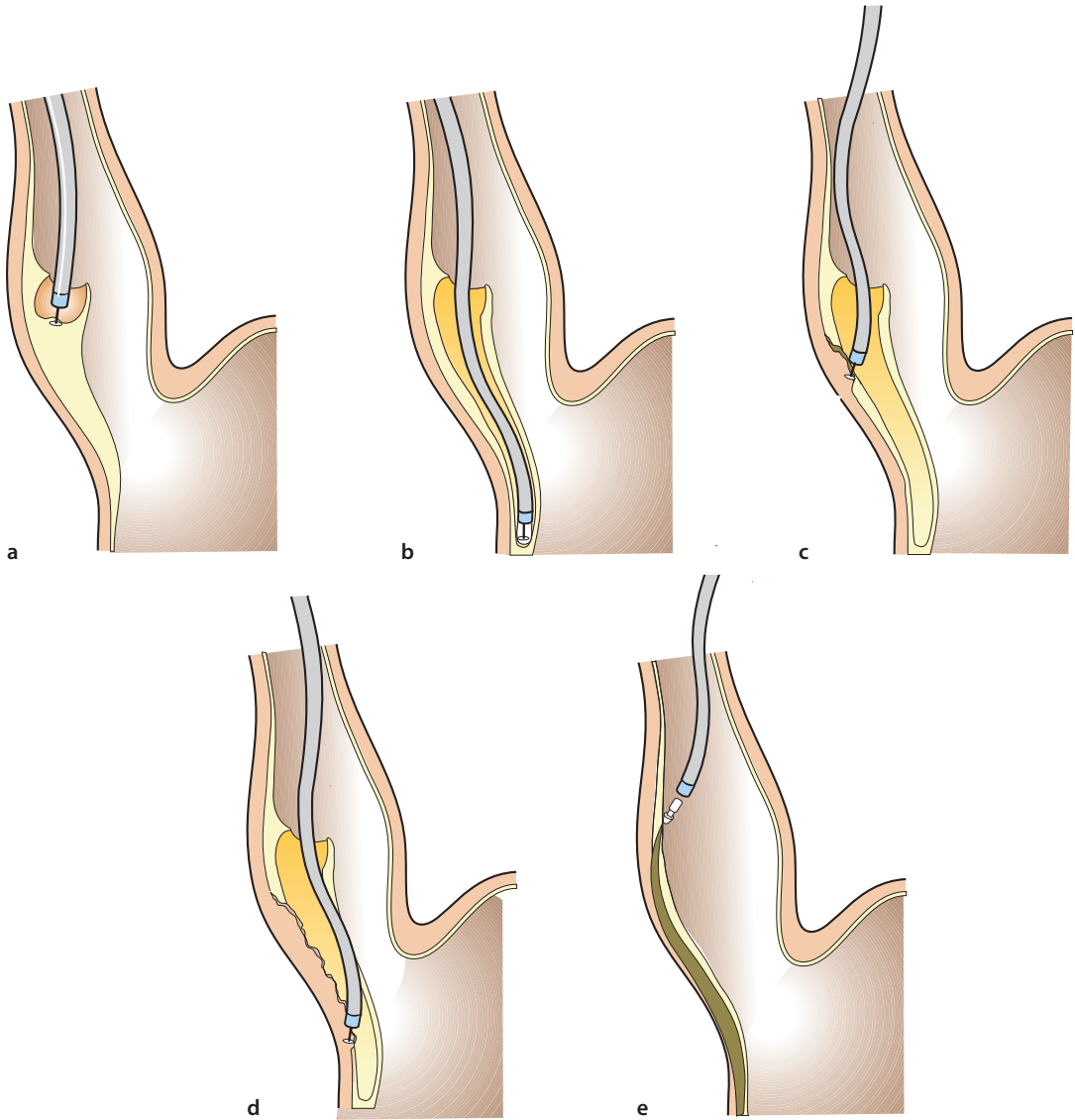


Fig. 2.16 a Incision after mucosal lift. b Creation of submucosal tunnel. c Incision of muscle fibers. d Extension of myotomy. e Closure of the tunnel

References

- Chen AM, Pasricha PJ. Cryotherapy for Barrett's esophagus: who, how, and why? *Gastrointest Endosc Clin N Am*. 2010;21:111–8.
- Di Nardo G, Oliva S, Passariello M, et al. Intralesional steroid injection after endoscopic balloon dilation in pediatric Crohn's disease with stricture: a prospective, randomized, double-blind, controlled trial. *Gastrointest Endosc*. 2010;72:1201–1208.
- Dzeletovic I, Ekbom DC, Baron TH. Flexible endoscopic and surgical management of Zenker's diverticulum. *Expert Review of Gastroenterol Hepatol*. 2012;6:449–66.
- Egan JV, Baron TH, Adler DG, et al. Esophageal dilation. *Gastrointest Endosc*. 2006;63:755–60.
- Endo K, Takahashi S, Shiga H, et al. Short and long-term outcomes of endoscopic balloon dilatation for Crohn's disease strictures. *WJG*. 2013;19:86–91.
- Fayter D, Corbett M, Heirs M, et al. A systematic review of photodynamic therapy in the treatment of precancerous skin conditions, Barrett's oesophagus and cancers of the biliary tract, brain, head and neck, lung, oesophagus and skin. *Health Technol Assess*. 2010;14: 1–288.
- García-Cano J. Colorectal stenting as first-line treatment in acute colonic obstruction. *World J Gastrointest Endosc*. 2013;5:495–501.
- Ginsberg GG, Barkun AN, Bosco JJ, et al. The argon plasma coagulator. *Gastrointest Endosc*. 2002;55:807–10.
- Haidry RJ, Dunn JM, Butt MA, et al. Radiofrequency ablation and endoscopic mucosal resection for dysplastic

- barrett's esophagus and early esophageal adenocarcinoma: outcomes of the UK National Halo RFA Registry. *Gastroenterol.* 2013;145:87–95.
- Kochhar R, Kochhar S. Endoscopic balloon dilation for benign gastric outlet obstruction in adults. *World J Gastrointest Endosc.* 2010;2:29–35.
- Lemberg B, Vargo JJ. Balloon dilation of colonic strictures. *Am J Gastroenterol.* 2007;102:2123–5.
- Mahesh VN, Holloway RH, Nguyen NQ. Changing epidemiology of food bolus impaction: is eosinophilic esophagitis to blame? *J Gastroenterol Hepatol.* 2013;28:963–6.
- Moonen A, Annese V, Belmans A, et al. Long-term results of the European Achalasia Trial: a multicenter randomized controlled trial comparing pneumatic dilation versus laparoscopic Heller myotomy. *Gut.* 2016;65:732–9.
- Pandolfino JE, Kahrilas PJ. Presentation, Diagnosis, and Management of Achalasia. *Clin Gastroenterol Hepatol.* 2013;11:887–97.
- Pfau PR, Pleskow DK, Banerjee S, et al. Pancreatic and biliary stents. *Gastrointestinal Endosc.* 2013;77:319–27.
- Pouw RE, Wirths K, Eisendrath P, et al. Efficacy of radiofrequency ablation combined with endoscopic resection for barrett's esophagus with early neoplasia. *Clin Gastroenterol Hepatol.* 2010;8:23–9.
- Renteln Von D, Fuchs K-H, Fockens P, et al. Peroral endoscopic myotomy for the treatment of achalasia: an international prospective multicenter study. *Gastroenterol.* 2013;145:309–11.
- Siddiqui UD, Banerjee S, Barth B, et al. Tools for endoscopic stricture dilation. *Gastrointest Endosc.* 2013;78:391–404.
- van Hooft JE, Bemelman WA, Oldenburg B, et al. Colonic stenting versus emergency surgery for acute leftsided malignant colonic obstruction: a multicentre randomised trial. *Lancet Oncol.* 2011;12:344–352.
- Varadarajulu S, Banerjee S, Barth B, et al. Enteral stents. *Gastrointest Endosc.* 2011;74:455–64.

Therapeutic Endoscopy in the Gastrointestinal Tract

Kähler, G.; Götz, M.; Senninger, N. (Eds.)

2018, XIII, 249 p. 242 illus., 212 illus. in color.,

Hardcover

ISBN: 978-3-319-55467-9