

Geoffrey J. Gladstone

Entropion, or inward rotation of the eyelid margin, is an eyelid malposition commonly seen by general ophthalmologists and oculoplastic surgeons. The severe corneal irritation secondary to contact with the lashes and keratinized epithelium of the eyelid skin brings patients in for evaluation promptly. There are four major types of entropion: congenital, acute spastic, involutional, and cicatricial. It is important to define the pathologic process in entropion to plan and achieve successful surgical repair.

Examination

A patient with any type of entropion will have complaints related to corneal irritation. Foreign body sensation, redness, and tearing are common. Entropion as well as its symptoms may be intermittent. A careful examination of the lids, lashes, conjunctiva, and cornea should exclude external disease that may exacerbate or cause spastic entropion.

Electronic Supplementary Material The online version of this chapter (https://doi.org/10.1007/978-3-319-67334-9_2) contains supplementary material, which is available to authorized users.

G.J. Gladstone, MD, FAACS
Consultants in Ophthalmic and Facial Plastic Surgery,
PC, Southfield, MI, USA

Oakland University William Beaumont School of
Medicine, Royal Oak, MI, USA

Wayne State University School of Medicine,
Detroit, MI, USA
e-mail: facialwork@gmail.com

The eyelid examination is first performed like an ectropion exam, in which the canthal tendons, lower lid laxity measurements, and snapback are assessed. In addition, the movement of the lower lid with downgaze may show evidence of weakness of the lower lid retractors. Normal excursion of the lower lid on downgaze is about 4 mm. The depth of the inferior cul-de-sac is assessed and inspected for scarring or symblepharon formation. If there is a cicatricial component to the entropion, this posterior lamellar shortening should be evident with examination. It is important to document the presence or absence of symblepharon, and to diagnose and treat ocular cicatricial pemphigoid prior to surgical intervention. A deep inferior cul-de-sac, or a visible white line (lower lid retractors) several millimeters inferior to the lower tarsal border is consistent with an involutional process.

Congenital Entropion-Epiblepharon

Etiology

True congenital entropion is a rare condition in which the entire lid margin is turned in. This is thought to be due to an overacting orbicularis muscle with congenital disinsertion of the lower eyelid retractors. Epiblepharon is much more commonly seen. This condition results from a fold of lower eyelid skin pushing the lashes in against the globe. Epiblepharon is most common in Asian children, and it often resolves as the facial bones develop.

Surgical Management

Congenital entropion can be repaired by reattachment of the capsulopalpebral fascia. This procedure is described in the involutional entropion section, and is performed without concomitant horizontal lid tightening in children.

Epiblepharon repair is necessary if there is evidence of keratopathy or if it is symptomatic. This can be accomplished with or without any skin removal. A horizontal incision is made 1.5 mm below the lash line, across the lower eyelid. The incision should extend a minimum of 2 mm medial and lateral to the inturned area. A small amount of skin is removed. A small amount of pretarsal orbicularis muscle is also removed, to expose the inferior tarsal border. The wound is then closed by approximating the upper skin edge to the inferior tarsal border, and then to the lower skin edge using interrupted 6-0 plain gut suture (Fig. 2.1, Video 2.1). This forces the incision made 1.5 mm below the lashes downward and inward toward the inferior tarsal border 4 mm below the lashes. This rotates the lashes outward.

Acute Spastic Entropion

Etiology

Spastic entropion, an acute condition that often occurs following eye surgery, injury, or inflammation, is believed to be the direct result of edema and blepharospasm. The process may improve or resolve with resolution of the underlying irritative process, but it may also cause a vicious cycle in which the spastic entropion creates more irritation and more orbicularis spasm. Injection of botulinum toxin is often effective in paralyzing the orbicularis and breaking the cycle. The effect of the botulinum toxin lasts only about 3 months, but the entropion may not recur when the effect wears off. More often than not, the authors have found, there is an underlying involutional component to the spastic entropion and these patients will develop involutional entropion later.

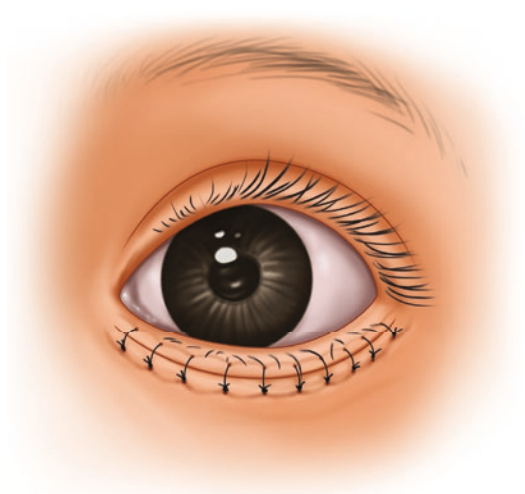


Fig. 2.1 Proper suture placement in epiblepharon repair

Involutional Entropion

Etiology

The most common type of entropion is the involutional type. The pathophysiology of this disorder involves several different mechanisms. Laxity of the medial and lateral canthal tendons, and thinning of the tarsus with aging, result in loss of horizontal support of the lower eyelid. Though a similar process occurs with involutional ectropion, associated dehiscence or attenuation of the lower eyelid retractors creates an imbalance of forces on the tarsus that results in an entropion. Additional contributing factors are thought to include the propensity of the preseptal orbicularis to override the pretarsal orbicularis. Involutional enophthalmos secondary to fat atrophy may contribute as well.

Surgical Management

Capsulopalpebral Fascia Reattachment

The method of repair of entropion is based on the type and severity of the problem, as well as the patient's ability to tolerate a procedure. Involutional entropion is reliably treated with a procedure that addresses the causative factors of the process. After local anesthesia, a subciliary incision is

made 2 mm below the lash line from below the punctum to the lateral canthal angle. A small skin flap is dissected inferiorly over the tarsus, and a strip of pretarsal orbicularis muscle is dissected off the tarsus. The orbital septum is tented and incised, exposing the thin white edge of capsulopalpebral fascia. This lies below the inferior orbital fat pads, as it is the lower eyelid analogue to the levator (Fig. 2.2). It is useful to mark the fascia with a 4-0 silk suture. A lateral tarsal strip operation is then performed to address the lower eyelid laxity (see Ectropion chapter) and the strip is sutured to the lateral orbital rim, with the appropriate amount of tension on the eyelid (Fig. 2.3). Three 6-0 silk sutures are used to reattach the capsulopalpebral fascia (CPF) to the inferior tarsal border (Fig. 2.4, Video 2.2). The eyelid should not be overcorrected, and the amount of CPF advancement can be confirmed by having the patient look down. The lid should have a normal 3–4 mm excursion. The skin is closed with interrupted 6-0 plain gut suture, and a small amount of CPF edge should be incorporated into the three central sutures to form a barrier to prevent overriding of the orbicularis muscle.

The lateral canthal angle is reformed with 6-0 plain gut suture.

Cicatricial Entropion

Etiology

Cicatricial entropion results from a differential horizontal shortening of the posterior lamella of the eyelid in relation to the anterior lamella. Chronic inflammation such as meibomianitis or blepharo-conjunctivitis can lead to lid margin keratinization, trichiasis, or distichiasis with severe symptoms in the absence of frank entropion. Trauma, particularly chemical burns, can lead to severe scarring and entropion. Chronic use of medication such as pilocarpine can cause conjunctival contracture leading to entropion. Trachoma is a common cause of entropion internationally, though it is seldom seen in North America. Other causes include ocular cicatricial pemphigoid, severe viral conjunctivitis, and erythema multiforme major (Stevens-Johnson syndrome).

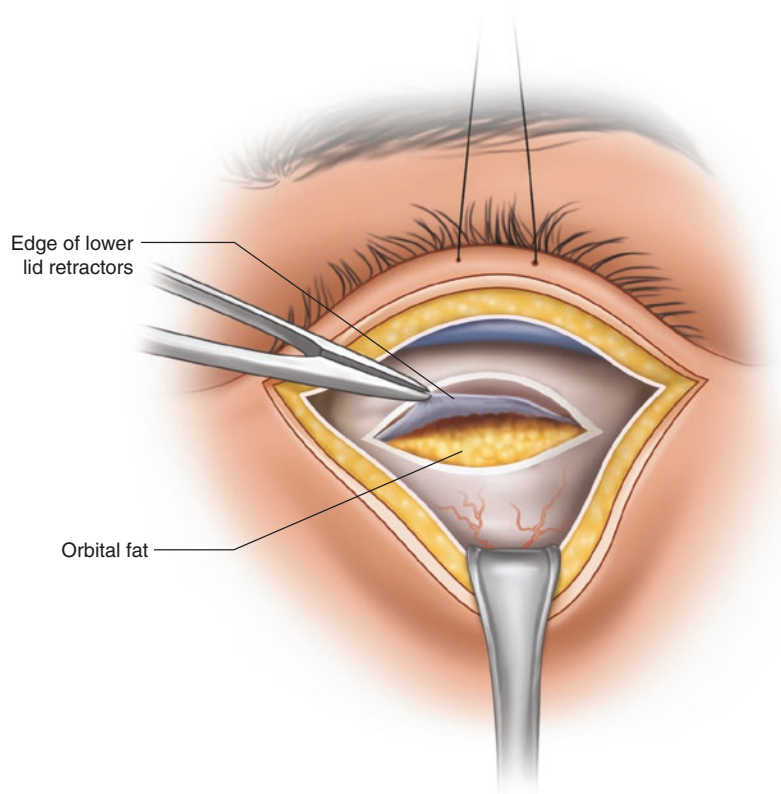


Fig. 2.2 A subciliary incision has been made, exposing the tarsus and lower eyelid retractors

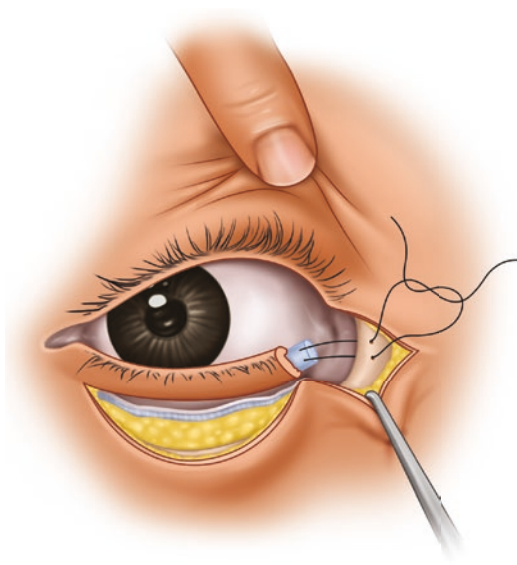


Fig. 2.3 A lateral tarsal strip is used to tighten the eyelid

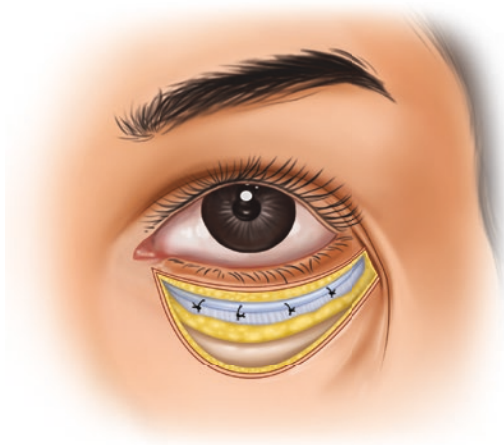


Fig. 2.4 The capsulopalpebral fascia is reattached to the inferior tarsal border

Surgical Management: Wies Procedure

If the entropion is cicatricial in origin, a transverse blepharotomy and marginal rotation (Wies

procedure) is effective for repair of the upper or lower eyelid. Local anesthesia is administered to the eyelid, and a horizontal incision is made 4 mm from the lid through skin and orbicularis. Care is taken to spare the marginal arcade, which lies 2–4 mm from the eyelid margin (Fig. 2.5). The lid is then everted, and a second corresponding incision is made through conjunctiva and tarsus. Westcott or tenotomy scissors are used to extend the full-thickness blepharotomy medially and laterally across the tarsus. Three double-armed 6-0 silk sutures are passed in mattress fashion through the tarsus internally, and over the surface of the tarsus to exit the skin near the lash line (Figs. 2.6 and 2.7). The closer these sutures are passed to the lashes, the more rotation is achieved. The sutures are tied over cotton or rubber bolsters to prevent “cheese wiring” (Fig. 2.8). A small overcorrection is the goal. The skin incision is closed with interrupted or running 6-0 plain gut suture. The silk sutures and bolsters should be removed in 10–14 days.

If the cicatricial entropion is severe, or if the foregoing procedure fails, posterior lamellar augmentation is necessary. A graft may be

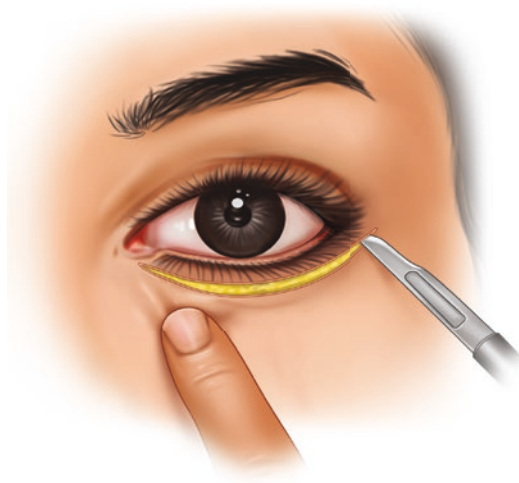

Fig. 2.5 A skin incision is made 4 mm below the eyelid margin

Fig. 2.6 A full-thickness blepharotomy is made and sutures are placed

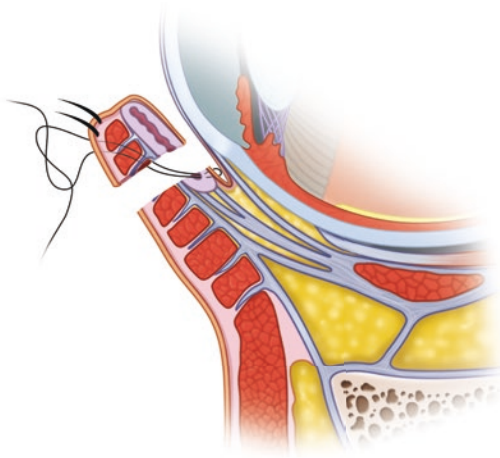
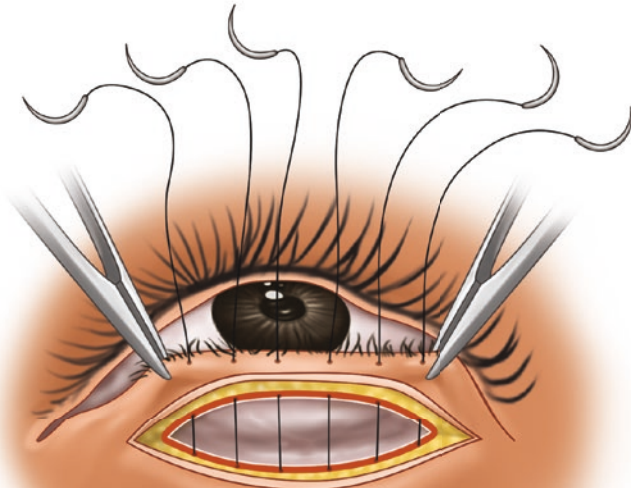


Fig. 2.7 Sutures for a full-thickness blepharotomy

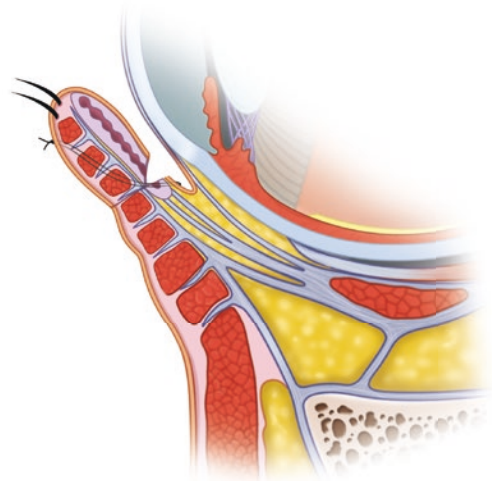


Fig. 2.8 When the sutures are tied, an external rotation of the eyelid is seen

placed between the conjunctiva/lower lid retractor complex and the inferior tarsal border of the lower lid. The various graft materials available include ear cartilage, hard palate, nasal septum, mucous membrane grafts, and tarsal substitutes. Upon release of the scarring, and production of a posterior lamellar defect, the graft material is sutured into place with

absorbable suture and the lid is allowed to heal with a traction suture placing it on stretch. The disadvantage of posterior lamellar grafting is that the lid may not retract well with downgaze (Video 2.3).

Oculoplastic Surgery Atlas

Eyelid and Lacrimal Disorders

Gladstone, G.J.; Nesi, F.A.; Black, E.H. (Eds.)

2018, XVIII, 81 p. 104 illus. in color. With online files/update., Hardcover

ISBN: 978-3-319-67333-2