


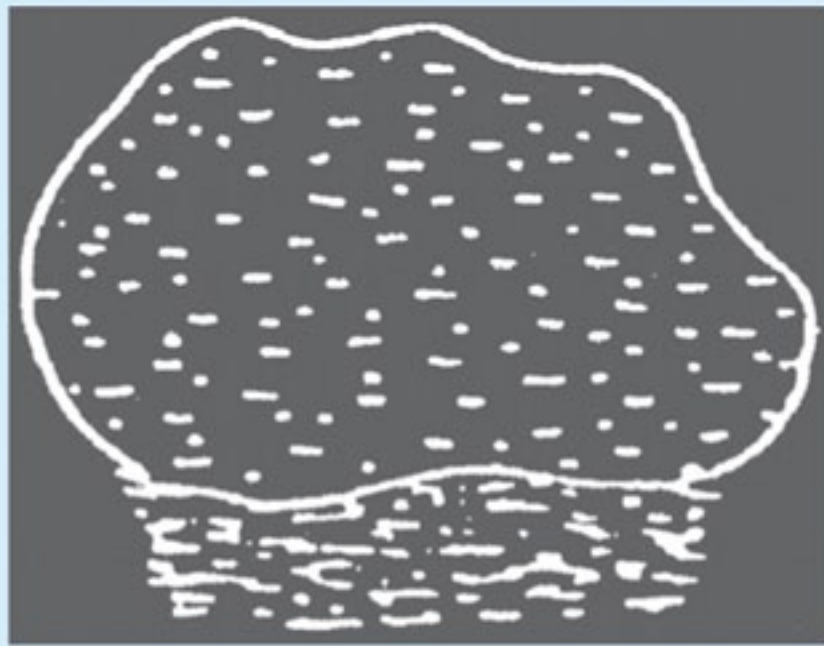
# Different types of abscesses




**Type I:** echofree



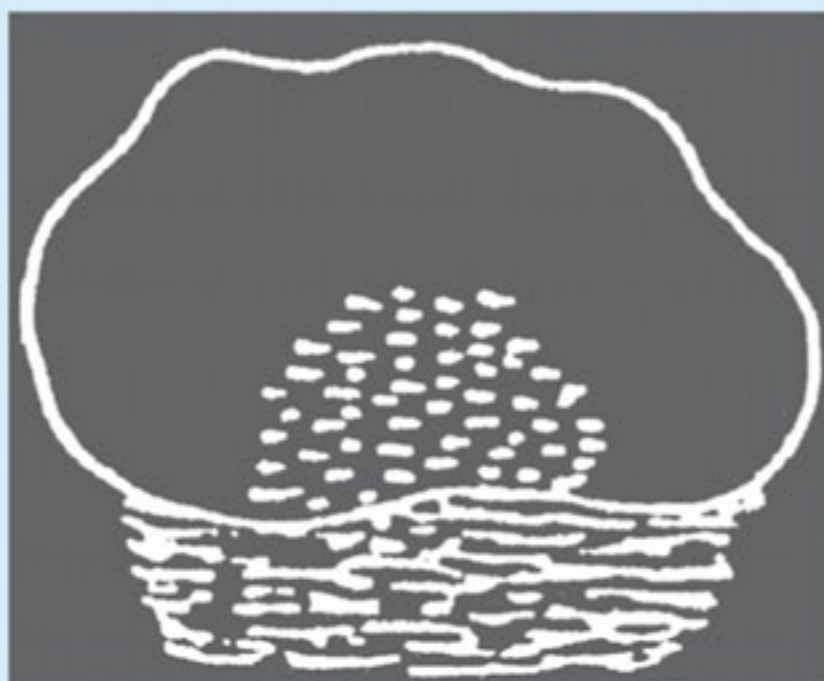**Type II:** hypoechoic



**Type III a:** hyperechoic  
with sound amplification



**Type III b:** hyperechoic  
without sound amplification



**Type IV:** mixed type



**Type V:** reflective