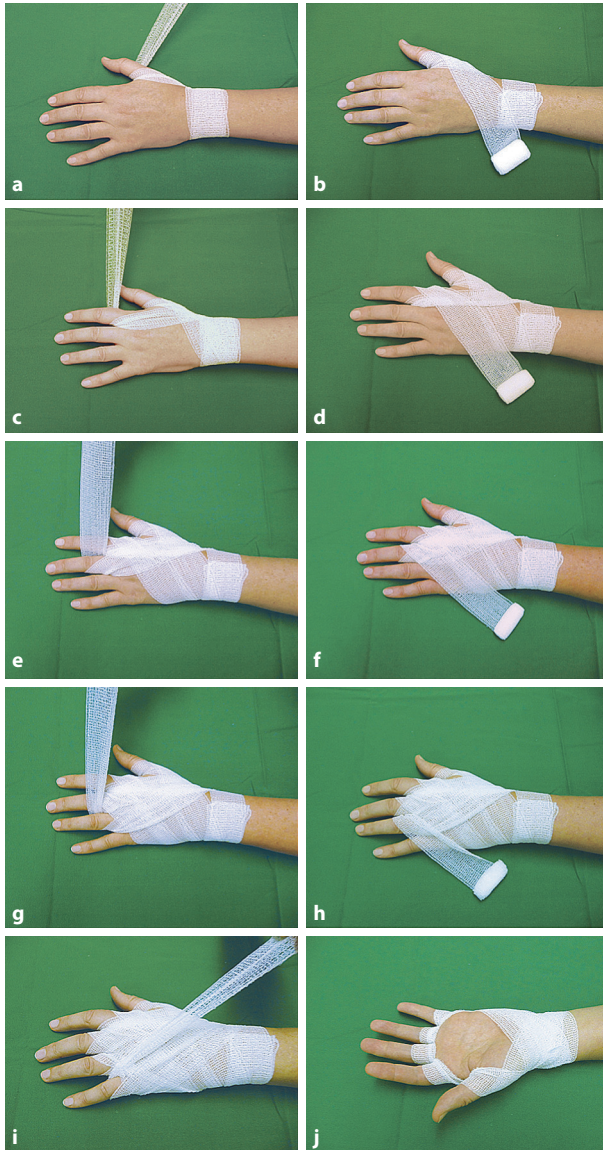
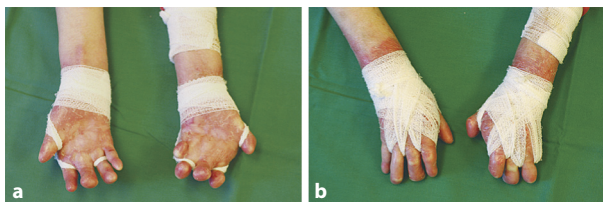


BANDAGING

■ **Fig. 8.38a–j** Bandaging steps, in alphabetic order

BANDAGING FOR DEB

■ **Fig. 8.39 a** Bandaging for a 15-year-old girl, 1 year postoperatively (palmar) (Hametner).
b Bandaging for a 15-year-old girl, 1 year postoperatively (dorsal) (Hametner)